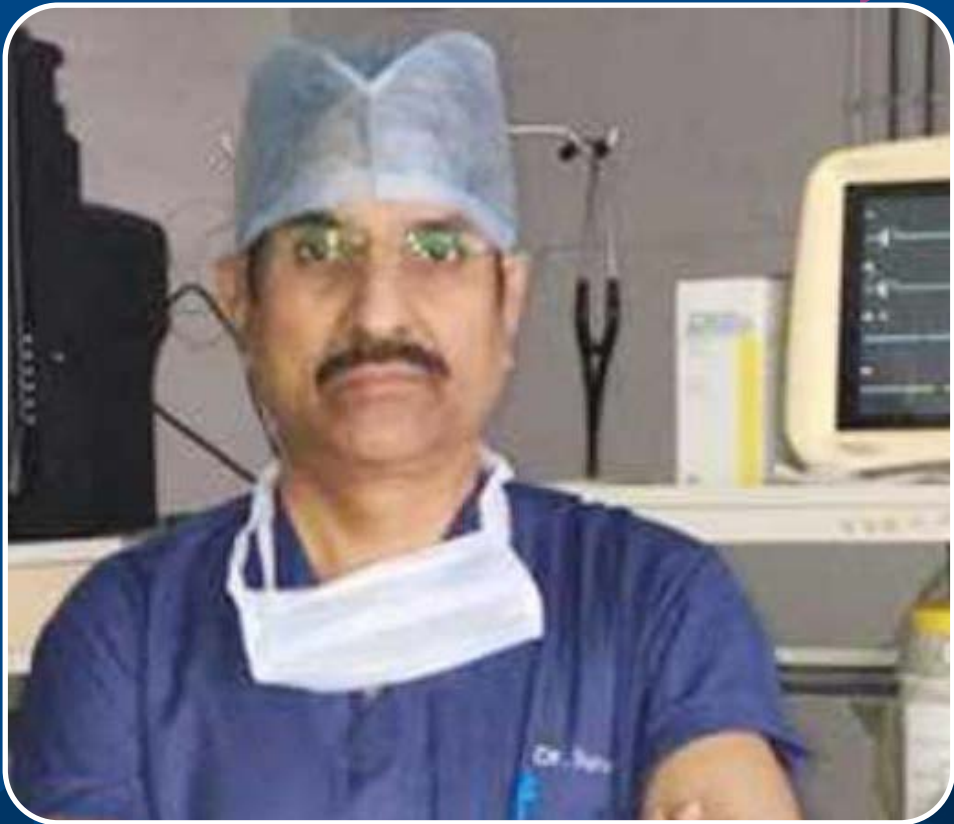

UNDERSTANDING THE  
*World of*  
PEDIATRIC SURGERY



DR. NARENDRA KUMAR ARE



## ▶ AUTHOR



Dr. Narendra kumar is a senior pediatric surgeon rendering his service to the needy children in both the states of Andhra Pradesh and Telangana. He has more than 30 years of experience in the field of childrens surgery. He worked as a medical teacher in various medical colleges in state of Telangana. Now he is working as professor & HOD, Department of pediatric surgery in Osmania medical college, Hyderabad.


He is known for his clinical acumen, surgical skills and his passion for teaching. As a medical teacher in government medical colleges, he trained many students with his extensive experience, in the field of pediatric surgery.

Profilic speaker, he has given more than 100 scientific deliberations in various medical meets & conferences. Performed many rare pediatric surgical procedures, which attracted national attention.

Dr. Narendra kumar's experience and knowledge has motivated him to write this book on common childrens surgical conditions & to share them in simple language with the general public. This write up hopes to bring awareness about children's surgeries.







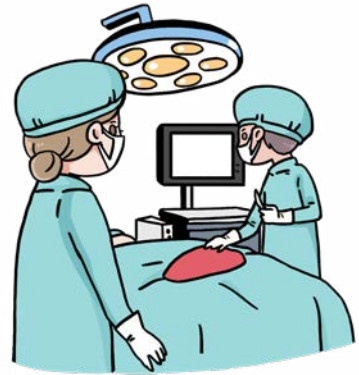**CHILDRENS SURGERIES –  
NO SCOPE FOR DOUBTS &  
APPREHENSIONS**



# 01

## CHILDRENS SURGERIES – NO SCOPE FOR DOUBTS & APPREHENSIONS

Children are very tender and delicate. They smile when they are happy and cry when they are in pain. They do not know beyond this. On such a delicate body, if surgery is required due to a surgical condition, the parents will get panic. A scar on baby's body is like a scar on the heart of the parents. Many doubts and apprehensions will surround the parents. Children cannot co-operate with surgeons because of their age, leading to problems to the treating children's surgeon.



Today pediatric surgery has overcome all these obstacles and became an established branch. Now days, with the advances in surgical techniques, advances in anaesthesia in children and advances in new born intensive care facilities, even just born newborns can be operated safely. But still there are many doubts and apprehensions on children's surgeries in the minds of the parents. This article tries & aims to clear all the doubts and apprehensions in the minds of the parents when ever a child needs surgical intervention.

Surgery is like an art. The beauty of surgery is to combine, scientific knowledge with the technical skill to repair the defect / problem in the body. Surgeon has to coordinate his hands, eyes, heart and brain to finish the surgical task. To become a good surgeon and to gain control over surgical technique a lot of patience is needed. This is more true in case of pediatric surgery.

### ► Specialities of Pediatric Surgery

Pediatric surgery is the subspeciality of surgery involving the surgery of fetuses, newborn, children and adolescents. Apart from core pediatric surgery, the subspecializations of

pediatric surgery are foetal surgery, neonatal surgery and adolescent surgery. This subspeciality will deal with corrections of (congenital) birth defects, traumatic lesions, infective and inflammatory conditions, and neoplastic (new masses) conditions in children. The main constraints in children's surgery when compared to adult surgery are

- **Communication** : Children can not communicate and express their problem on their own. It is always an indirect history from parents. They only smile when happy and cry when in distress. So there is always problem with communication in children for the attending pediatric surgeon
- **Co-operation** : Children do not co-operate with pediatric surgeon for clinical examination. They do not lie quiet and move a lot. They cry a lot during examination. So, pediatric surgeon needs lot of patience during examining a child.
- **Smaller tissues** : Children's tissues are small with less safety margin from vital structures. So more vigilance, more gentleness in handling is required in pediatric surgery.

- **Post-operative monitoring** : Children needs more constant monitoring in the postoperative period than in adults. This is because they deteriorate fast than adults if something goes wrong, so pediatric surgeons needs not only surgical technique but also needs dedication
- **Longterm results** : Children grows from feeding stage to the earning stage. Pediatric surgeons aim is to get a good longterm results so that the child leads a healthy & fruitful longlife. So the surgical results achieved in the childhood should lead him to an earning stage.

### ▶ **Problems Faced by Pediatric Surgeons**

- **Lack of awareness** : parents lack awareness about childrens surgeries and at the same time, have lot of fear and apprehensions about surgical procedures. They should realize that there are more than 600 conditions in children where they need surgical intervention.
- **Difficult to convince** : it is very difficult in some cases for the pediatric surgeons to convince the parents for surgery and take their consent. It will take long time to explain patiently the need for surgery and clear their doubts before taking their consent.

### ▶ **To Get Good Results in Pediatric Surgery**

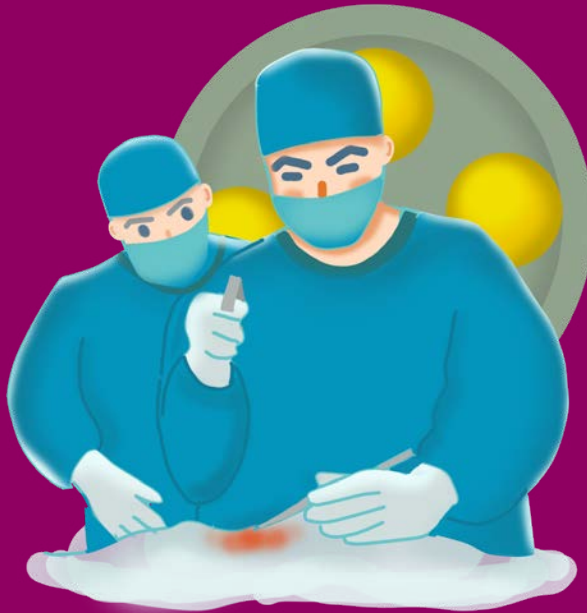- **Cooperation from parents** : parents should cooperate with pediatric surgeons for getting good longterm results
- **Emergency consultation** : in some situations children need emergency surgical intervention. So to get good results, parents need to consult pediatric surgeons in time & follow their advice in time.
- **Feeding after surgery** : the parents should follow the instructions given by the surgeon regarding feeding before and after the surgery. In some surgeries feeding is given after 4-6 hours, in some it is given after 24 hours, in major surgeries feeds will be given after 5 days. following surgeons instructions with regard to feeding will help in getting good results after surgery.
- **Right choice** : choosing a technically skillfull pediatric surgeon and a well equipped level -2 or 3 hospitals will give good results.



## ▶ Common Apprehensions & Truth in Them

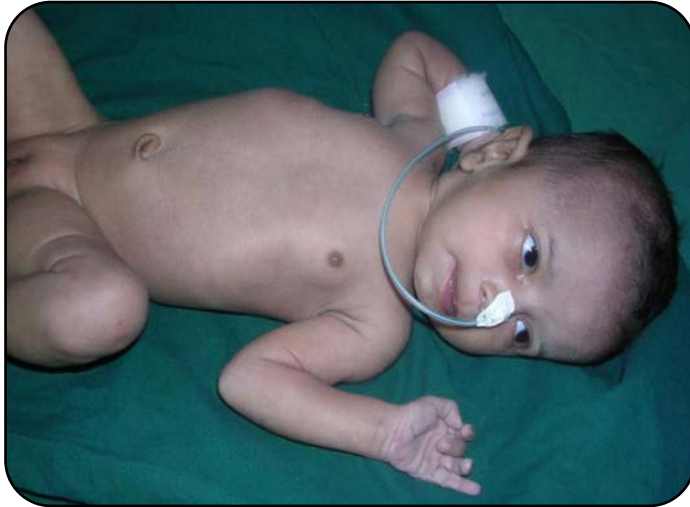
- **Age** : will small children can withstand the trauma of surgery -this is the first doubt the parents will get, when surgery is advised to their child. ➔ **Truth** : with the rapidly progressing advances in medical field, today operating on a foetus in the womb is a reality. So, today even new born can undergo major surgical procedures safely. This is possible because of advances in surgical procedures, pediatric anaesthesia and neonatal intensive care facilities.
- **Pain** : children cannot tolerate, pain of even a small injection, in such a situation how can they tolerate pain of a surgery ? this is the doubt expressed by most of the parents. ➔ **Truth** : pain and discomfort after surgery will be felt by children also. But there are many methods of controlling the pain post-operatively. Pain relieving medicines can be given by intravenously or through spinal route by a single, long acting injection or by a continuous infusion. Analgesics can be given orally to control the pain. Analgesia can be achieved locally by giving injection of pain relieving drug locally at operated area. Analgesia can also be achieved by introducing medication in the form of rectal suppositories.
- **Movement after surgery** : children are always active. How to keep them quiet and confine them to bed after surgery? ➔ **Truth** : in most of the childrens surgeries, there is no need to completely restrain them on bed. They can move to limited extent immediately after surgery. In cases where total restrin is needed, like when they are on ventilator sedation is given to make them sleep.
- **Feeding after surgery**: will they tolerate the fasting period after surgery ? ➔ **Truth** : in most of the childrens surgeries, 4-6 hours of fasting before surgery and 4-24 hours fasting after surgery is advised. Only in a few complex and major surgeries, 5 days of prolonged fasting is needed. This period can be managed with intravenous fluids and suppliments infusion.
- **Anesthesia in children** : Giving anaesthesia and recovering the child from anaesthesia are the two critical events during babies surgical procedure. Will the children withstand the surgical procedure ? ➔ **Truth** : since the last one decade, there are many advances in the field of childrens anaesthesia. Newer safe medications and newer anaesthesia and monitoring equipments are available now. With their help it is possible now to operate safely even in preterm and low birth weight babies. So, anaesthesia in children is safe now.
- **Infections after surgery** : resistance in children is low compared to adults. They can get infections after surgery particularly lung infections. How to tackle them ? ➔ **Truth** : Operating under strict asepsis, keeping the children postoperatively in intensive care units in a clean environment, keeping under antibiotic cover postoperatively for 5-7 days, will reduce the risk of infections and make the surgeries in children safe.
- **Longterm results** : How the children who has undergone surgery will grow, will there be any long term affects of surgery ? ➔ **Truth** : The longterm results will depend on the type of surgical condition, the child is suffering with. But 90% of the surgical conditions in children will have a good prognosis. In very few complex surgical conditions like cloacal malformations in girls will need staged correction, may have some longterm issues.





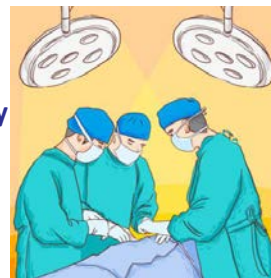## EMERGENCY SURGICAL CONDITIONS IN CHILDREN

## GREENISH VOMITING (BILIOUS)



## EMERGENCY SURGICAL CONDITIONS IN CHILDREN

Children's body is a delicate structure like petals of a flower. On such a body if surgery is needed to be performed, it leads to a panicky situation to the parents. The thought of putting a knife during surgery on their child's body, will lead to a tense situation for the parents. Lot of doubts will arise in their minds. Whether to give consent immediately or to consult another doctor for second opinion or to consult their relatives for opinion. This dilemma will lead to undue delay in giving consent for the procedure. This delay is not good for children in certain emergency conditions.



As parents are the main persons who take care of the health of their children, their Undue Delay in taking decision for giving consent for emergency procedures will lead to lot of problems like.....

- Loss / decrease of the function of the organ
- Gangrene / death of the organ
- Risk to the surrounding and adjacent structures.
- Risk of long term problems like adhesions.
- Increase in the suffering and also increase in the duration of hospital stay.
- Risk to the life of the child

This article will give a detailed insight of the **9 emergency conditions** in children, where the decision making by parents in time is very important.

1. Obstructed hernias
2. Torsion testis.
3. Perforated appendix
4. Malrotation of gut with volvulus
5. Massive meckels bleed
6. Tension pneumothorax.

7. Foreign body aspiration.
8. Acute intestinal obstruction
9. Intussusception

### ▶ Obstructed Hernias

Hernias are common surgical conditions in children. Herniation of bowel loops through abnormal openings in the musculature of the abdominal wall or Non closure of temporary openings during development which are supposed to close, will lead to development of hernias in children.

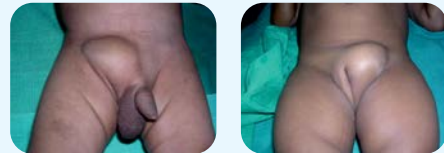
The common sites for the development of hernias in children are.. Inguinal areas (groin), femoral area (upper medial side of thigh) and umbilical areas. Inguinal hernias are the common hernias in children. Hernias are more common in pre-term babies.

The dreaded complication of hernias is irreducibility (failure to go back in to abdomen) and obstruction. Normally hernias are noticed by the mother as an intermittent swelling appearing in the groin, while giving bath or when the child is crying or coughing. This is because the intestine comes out on straining and goes back on relaxation.

In case of obstruction, intestines come out and they get stuck. This leads to initially swelling (edema) of the intestines. As time passes on the blood supply of the intestines is affected leading to death of the herniated part of the intestine (gangrene). If not operated even at this stage it will lead to risk to the life of the baby.

To avoid these complications parents should take, immediate doctors consultation if they notice any change in the hernial sites. No time should be lost, if there is an obstruction of the inguinal hernia.

**Danger signs :** Any persistent swelling, pain, redness later development of greenish / yellowish vomitings in the area of previous hernia is a danger sign. If fever and sickness develops it indicates that intestinal gangrene has set in. immediate medical consultation is needed.



## ▶ Torsion Testis

Normally both testis lies in the scrotum with certain element of up and down movement of the testis with in the scrotum.

But testis can not rotate and takes turns on its vascular pedicle due to an membranous attachment to the scrotal wall called-Gubernaculum.

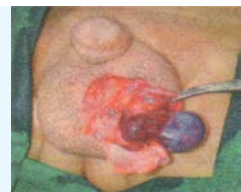But in some children, due to lack of proper attachment, the testis will rotate on its vascular pedicle. Testis is supplied by one major blood vessel testicular artery and two supportive blood vessels.

This leads to obstruction to the flow of the blood to the testis. This condition is called - Torsion Testis. This condition presents with

acute redness, swelling and pain in the torsion side of the scrotum. Sudden excruciating pain in the scrotum felt by a child followed by swelling will give a clue about possibility of torsion testis. An immediate, ultrasound with Doppler study will clarify whether the particular condition in question is torsion or not. On Doppler study, in torsion testis, the blood supply to testis will be totally cut off.

If this condition is not operated upon immediately (within 6-8 hours) the testis will loose its blood supply and becomes dead. the child will loose the testis for life. So once torsion testis is diagnosed, intervention should be urgent, (with in 3 hours) to protect and preserve the testis.

**Danger signs :** sudden development of acute pain in one half of the scrotum with development of redness is a danger sign. Immediately ultrasound with doppler study to be done to rule out torsion testis.



## ▶ Perforated Appendix

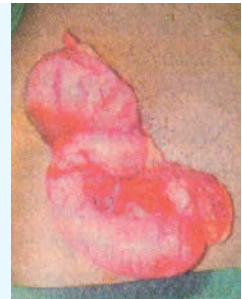
Appendix is a small part of the large intestine, present at the junction of the small and large intestines. Appendix can get affected by infection or obstruction of lumen (by fecolith or worms). This will lead to painful enlargement of the appendix. If it is not treated properly, it will lead to perforation of appendix.

Perforated appendix will lead to leakage of pus in to the abdomen. Presence of pus in abdomen will lead to infection of blood (septicaemia), pus pockets in the pelvis (pelvic abscess), collection of pus under diaphragm (subdiaphragmatic abscess). The presence of

pus will lead to adherence of intestines to the surrounding structures (intestinal adhesions). Pelvic abscess will lead to infection of internal genitalia in girls, leading to blockage of the fallopian tubes, may lead to infertility. Appendicitis in girls may need to be treated aggressively as it is in close proximity to uterus, fallopian tubes and ovaries (pelvic inflammatory disease).

In view of the risk of perforation, when appendicitis is diagnosed by a physician the parents need to take a quick decision.

**Danger signs :** sudden onset of acute abdominal pain, which starts around umbilicus and later spreads to right lower abdomen. On one finger pressure there will be severe pain in right lower abdomen. Not able to stand straight with temperature and one or two vomitings. This is the typical picture of acute appendicitis. emergency ultrasound and complete blood picture should be done to R/O appendicitis.



## ▶ Malrotation With Volvulus.

All of us have small and large intestines located and fixed in a particular fashion. The small intestine is long and freely moves in the abdomen but fixed to the posterior abdominal wall by a sheet of membrane called -Mesentery. In other words, the small intestine hangs from this Mesenteric attachment. This Mesentery will extend from left upper abdomen to right lower abdomen. This long Mesenteric attachment will prevent small intestine to get rotated on itself (volvulus). But in some children, the intestinal rotation and fixation of mesentery, during development will not be in a normal way. This condition is called.. Malrotation of midgut.

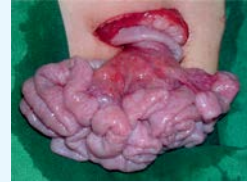The problem with the malrotation of gut is, improper fixation of the bowel.(mesenteric attachment). This will lead to a dreaded complication called- Volvulus of Midgut. In volvulus of midgut, when the bowel gets rotated, its blood supply also gets rotated leading to loss of blood supply to a large segment of small intestine. This will lead to death of a significant length of small intestine. (gangrene).

This condition can present in the newborn period or later in life. This presents with sudden onset of excessive crying with greenish or yellowish vomiting. If diagnosis is delayed it will lead to bleeding from rectum. This emergency will be detected by intestinal

contrast x-ray studies and doppler U/S study. This condition has to be operated upon on

emergency basis. Parents need to take an immediate decision once this condition is diagnosed.

**Danger signs :** if a child suddenly starts crying without reason, and starts having greenish or yellowish vomiting without abdominal distension, later starts passing blood per rectum indicates possibility of volvulus of small intestine due to malrotation of midgut. This is a real emergency condition. Immediate medical attention is needed.

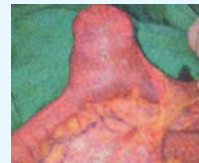

### ▶ Meckels Diverticulum With Massive Bleeding.

About 2% of general population will have an extra part attached to the terminal part of their small intestine called Meckels diverticulum. In those with Meckels diverticulum, a few will present with bleeding per rectum. Some times this bleeding will be massive and child may need multiple transfusions. In 2% of those with Meckel diverticulum, the diverticulum can have ectopic (intestinal covering layer) mucosa which secretes juices which produces ulcers and bleeding from intestine. Sometimes Meckels diverticulum will get infected and become bursted.

The characteristics of this bleed will be it is painless, intermittent and massive. Any massive painless bleeding with normal abdominal appearance in children, Meckels Diverticulum should be suspected. It needs immediate intervention by either laparoscopy or laparotomy. The intestinal part containing the Meckels diverticulum is removed and intestinal continuity is maintained. This surgical intervention gives prompt and permanent relief.

**Danger signs :** Sudden, Massive bleeding from rectum with normal abdomen is a dangerous sign and we have to rule out Meckels diverticulum.



### ▶ Tension Pneumothorax

Thorax is a rigid compartment bounded by ribs and muscles. It can not expand when air or fluid collects inside the thorax. But in case of abdomen, it is not the case. The abdomen distends to accommodate the collection.

Due to injuries, or due to pre-existing diseases, some times lungs rupture leading to leakage

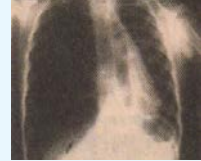of air in to the thorax. This condition is called "pneumothorax." If the rupture is wide, with each breath more and more air is leaked in to thorax leading to a life threatening condition called.. "Tension pneumothorax." This is one of the real life emergencies, as leaked air compresses the lungs and heart.



In this condition as an emergency – a vent has to be created in to the chest to relieve the air pressure. Even a common man can put a needle in the midclavicular line in the

front of the upper chest. qualified medical personnel will introduce a chest tube in to the 4th intercostal space in midaxillary line to relieve the compression on the lungs. Once air is escaped, the lungs will expand properly.

**Danger signs :** In cases of trauma or road traffic accidents, with or without, evidence of chest injury if the child becomes blue with respiratory difficulty it is an evidence of air trapping in the chest (Tension Pneumothorax)



## ▶ Intussusception

Telescoping of one part of the intestine in to another part of intestine is called.. intussusception. This can happen without any notice in some healthy babies commonly between 6- 9 months. It can occur in new borns or children between 2months to 3years of age.

Common seasons, when an intussusception can occur are winter seasons when respiratory infections are more in children and also in summer season when diarrhoeal attacks are more common.

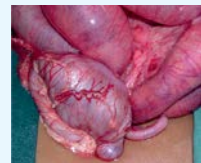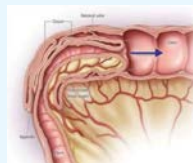
Intussusception is an emergency condition in children. As the intestine is going in to another

part of the intestine, it goes in to it along with its blood supply. As the time passes it leads to compression of the blood supply and death of the part of the intestine which goes inside.(Gangrene). Time is very precious in intervening once intussusception is diagnosed.

Intussusception is diagnosed by ultra sound examination. Doppler study will reveal whether, the bowel segment which is intussuscepted is viable or not

If it is detected early, it can be managed by non-operative Hydrostatic reduction under laparoscopic guidance. If delayed,it needs open surgery to relieve the intestinal obstruction.

**Danger signs :** Normal healthy child suddenly starts crying excessively and had greenish or yellowish vomiting. Later, the child passes blood in the stools. It is a typical presentation of intussusception. It is one of the real emergencies in children. It needs to be relieved by surgical intervention as it leads to gangrene of bowel if delayed.



## ▶ Foreign Body Aspiration

Growing children will have lot of enthusiasm to explore their surroundings and learn the things. In this manvour, they come across many attractive and colourful objects.

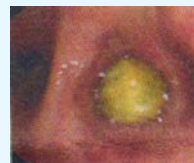When they put these objects in to the mouth, sometimes these objects may go in to the respiratory system, and cause aspiration. These foreign bodies when they are aspirated

may cause complete obstruction to the windpipe and cause instantaneous death. If the obstruction is incomplete and partial, changing with the position of the patient, the symptoms are less acute. These aspirated

foreign bodies should be removed by emergency bronchoscopic removal.

As it is a lifethreatening condition, in FB aspiration cases, the parents should not lose time in giving consent for the procedure.

**Danger signs :** When in a healthy child, if there is a sudden onset of respiratory distress and cough with baby turning in to blue colour, with relief of breathing by change of position, a foreign body aspiration should be suspected. It is an emergency condition which needs foreign body removal by bronchoscopy at the earliest.



## ▶ Intestinal Obstructions

Many conditions in children can lead to intestinal obstructions.. like adhesions, congenital bands, volvulus of bowel and inflammatory conditions.

In these conditions, if the obstruction is complete, it leads to swelling of the intestine,

later to compression of the blood vessels leading to death of the intestines. To prevent this complication and to preserve the vitality of the bowel, intestinal obstructions if they are significant and complete should be operated upon immediately.

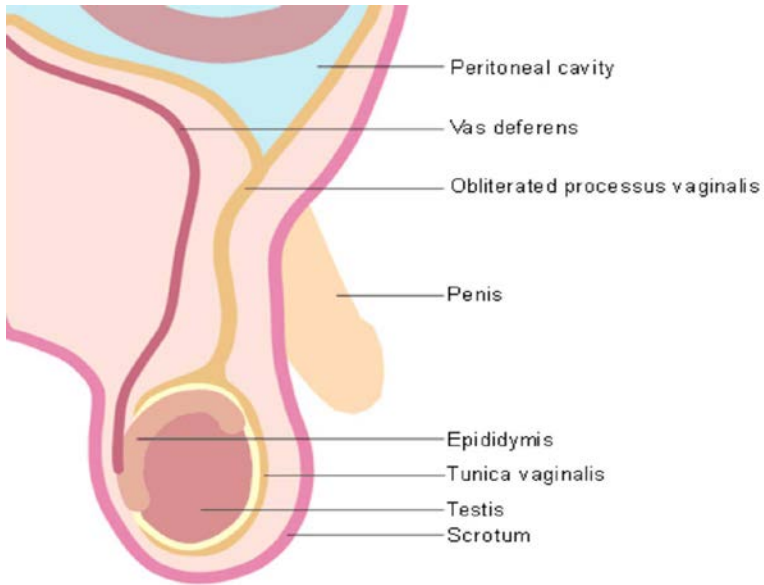
**Danger signs :** If the child develops abdominal distension, greenish /yellowish vomitings and constipation an intestinal obstruction has to be ruled out.

These **9 emergency conditions** in children are important in the aspect of timing of medical intervention. The parents play a crucial role in deciding the timing by giving their prompt consent. Hope this article brings the awareness about the emergency conditions and cautions the parents about their role

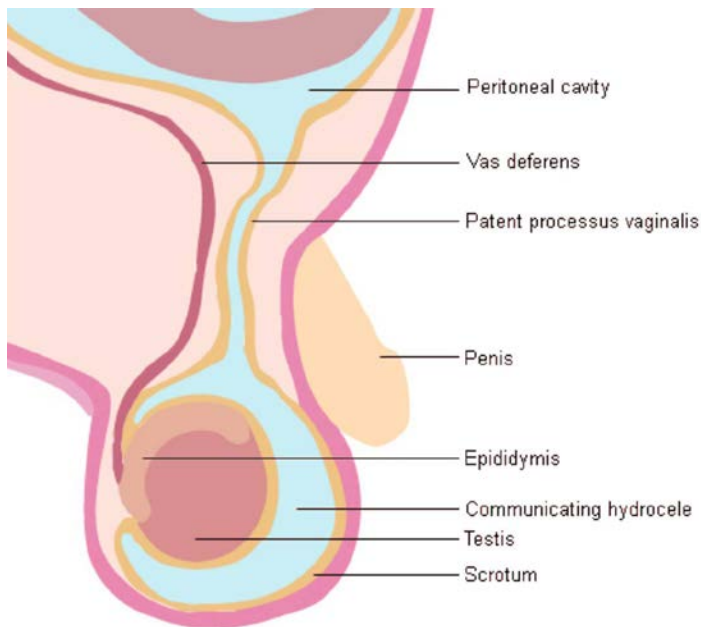


## HYDROCELE IN CHILDREN

### Normal



### Hydrocele - Communication is Present



Parents will take constant care about the health of their children & gets worried when ever any change occurs in the childs body. This is important as the children cannot express their problems. it is the duty of the parents to observe constantly the changes occurring & happening in the body of their children.



One such change is development of Hydrocele in children. Parents will notice a swelling in the scrotum of their child while changing diaper, while giving bath or when the child is crying. Many doubts will arise in the minds of the parents, when they notice a swelling in the scrotum. Will it be a serious problem ? will it needs surgery ? will there be any longterm effects on the male function ?. it is always better to consult a pediatric surgeon to get a clarity on the doubts raised in the minds of parents. There are two common lesions which can produce swelling in the scrotum in children. when fluids collects in the scrotum, it is called -Hydrocele. When a loop of intestine drops down in to the scrotum it is called -Hernia. These are the most common surgical conditions dealt by the pediatric surgeons in their day today practice.

hydroceles are usually painless.

Hydroceles occur more commonly in infants, especially premature infants, but can occur at any age.

During the seventh month of fetal development, the testicles move from the abdomen into the scrotum. When the testicle travels downward, it brings the sac-like lining of the abdominal cavity with it. The sac allows fluid present in the abdomen to surround the testicle. This sac usually closes before birth, preventing additional fluid from going from the abdomen into the scrotum, and the existing fluid is absorbed. If the sac communication persists two anomalies can occur. If the pouch communication with abdomen is small allowing only fluid, it results in the formation of Hydrocele. If the communication is big enough to allow fluid & intestine to come down it is called -Hernia.

### ▶ What is Hydrocele in Children ? How they Develop ?

A hydrocele is a collection of fluid in the scrotum, surrounding the testicle, which can occur on one or both sides. The fluid will make scrotum look swollen or enlarged, but

**Hydrocele is a fluid collection in the sac that normally surrounds and holds the testis in the scrotum.**

**This sac is called -Tunica vaginalis. The testes are initially formed in the babys abdomen during development..**

10% boys are born with hydrocele but in most of the instances, it resolves with in one year of age. It can present in new born particularly in premature neonates. Hydrocele in children will present like a smooth painless swelling in the scrotum or as a swelling which changes with time. The swelling is minimal in the early morning when the fluid goes back in to the abdomen during lying down at sleep, and returns back to produce a significant swelling during activity as the day progress.

## ▶ Types of Hydrocele in Children

There are two types of Hydrocele in children, communicating type -in which a small communication will persists throughout the length in to the abdomen. In the other type, the fluid collects but the communication gets closed later – it is called non-communicating hydrocele. The swelling from a noncommunicating hydrocele doesn't have changes in size. A communicating hydrocele can get bigger during the day, and if you gently squeeze it, the fluid will move out of the scrotum and into their belly.

There are many types of non-communicating hydroceles in children. If the fluid collects above the testis along the spermatic cord with communication closed above and below, it is called – encysted hydrocele of the cord. If the fluid surrounds the testis and closed above with abdomen it is called -infantile hydrocele. If the hydrocele fluid collection is there in the groin area and communication is closed below with scrotum it is called- funicular hydrocele. A reactive hydrocele is a type of non-communicating hydrocele that results from inflammation in the scrotum caused by trauma, infection or testicular torsion.

## ▶ How Hydroceles are diagnosed in children ?

Hydroceles are diagnosed by history of swelling in the scrotum and by clinical examination by the clinician. Presence of a smooth painless swelling in the scrotum will give a clue. The swelling can not be reduced by manual pressure as the communication with abdomen is very small but at the same time there is a history of diurnal variation in the size of the swelling. That is swelling is small in the early morning but increases in size with time as the day progresses due to increase in the activity of the child.

## ▶ Possible complications of hydrocele in the longterm

A hydrocele doesn't hurt. The only symptom is that one or both of the baby's testicles look swollen. Hydroceles are not harmful to the testicles in any way and they don't cause any pain. They are basically painless swelling in the scrotum.

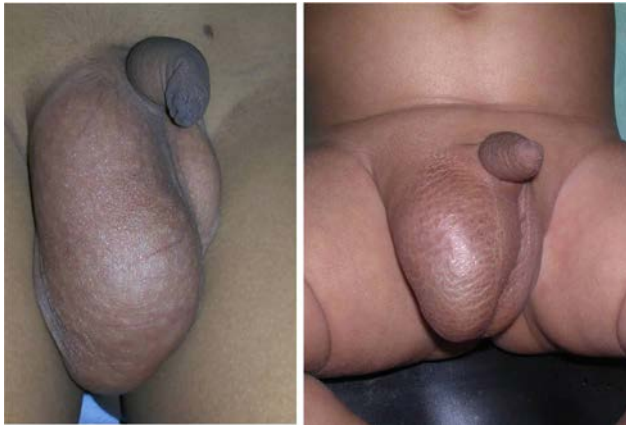If the hydrocele goes away on its own (spontaneous resolution) or it is corrected by surgery, no longterm affects will be there. But if any trauma to scrotum occurs before treatment, there is a possibility of development of Hematocele due to bleeding in to hydrocele.

## ▶ How a Hydrocele in children is being treated ?

Treatment depends on the type of the hydrocele, age of the child, size of the swelling & general condition of the child. As there are no major complications in childrens hydrocele, a waiting period up to 12-18 months of age is usually followed. A Hydrocele that persists beyond 12-18 months is often a communicating hydrocele. It needs to be corrected by surgery. As long as swelling is decreasing, it can be safely observed.

The treatment approach for hydrocele in children will depend on the type of hydrocele.

- **Non-communicating hydrocele:** In many cases, non-communicating hydroceles will resolve over the first year of life. If child age is less than 1 year of age, the surgeon will often recommend observation of the hydrocele. If the hydrocele persists past the age of 1, surgical repair will be necessary.
- **Reactive hydroceles:** If hydrocele is caused by infection or inflammation, antibiotics or anti-inflammatory medications will be used for treatment.



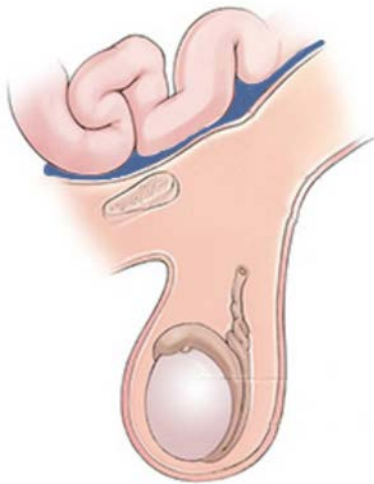
- **Communicating hydrocele:** Communicating hydroceles will not resolve on their own and will require a surgical procedure to repair the hydrocele.
- **Hydrocele of the cord:** Hydroceles of the cord will not resolve on their own and will require a surgical procedure.

surgery for hydrocele in children is done through a small cut in the groin area. In adults with hydrocele the surgery is done on scrotum as the reason for fluid collection is in the scrotum but in children surgery is done through groin incision as the fluid is

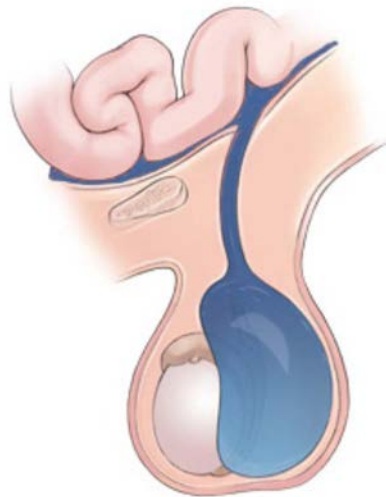
coming from abdomen. The communication is identified at surgery as a fluid filled white sac. It is separated from vas and blood vessel carefully and communication is closed off. The fluid in the distal sac is drained out and the distal sac is laid open. As the communication with the abdomen is closed surgically, no further fluid collection can occur in future.

Parents need not get panic or worry about the surgery of hydrocele in children as It is a surface surgery and done as a day care procedure. Surgery takes around 1 hour of time. Done under general anaesthesia. Laparoscopy is not an option for hydrocele surgery in children.

**Normal**



**Hydrocele**



### **Key Points :**

Hydrocele in children is a painless fluid collection around the testis in the scrotum due to the persistence of the communication with the abdomen. Most of the cases will get resolved within 12-18 months of age of the child, if it persists beyond it needs surgical correction.





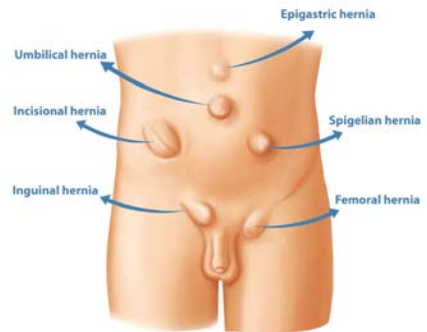
## HERNIAS IN CHILDREN



# 04

## HERNIAS IN CHILDREN

Many people are surprised to learn that hernias are common in kids. The statement -less awareness and more apprehensions will suit appropriately for hernias in children. Hernia surgery is one of the commonest surgery performed by the pediatric (childrens) surgeons. Sometimes babies, particularly preterms are born with hernias.



Some hernias are External and some hernias are Internal. External hernias like inguinal hernia, umbilical hernia are visible as a bulge at hernia site on straining but internal hernias like hiatus hernia or congenital diaphragmatic hernia are not visible. They present with respiratory or gastro-intestinal symptoms or they will be detected on evaluation by investigations. Most common are the external hernias.

The two common hernias in kids are- inguinal hernia in groin and umbilical hernia in bellybutton area. Hernias in kids needs prompt surgical correction.

### ▶ What is a Hernia ? Why They Occur ?

When a part of an organ or tissues (like intestinal loop) pushes through an abnormal opening, or weak spot in a muscle wall, it can protrude in to a space to which it does not belong. This is called as hernia. In otherwords, hernia occurs when a loop of intestine protrudes through a weakness in the abdominal muscles. There are three ways by which common hernias can occur.

- During normal development of a baby, many **natural openings** are present which closes spontaneously during development, once their purpose is served. If these openings persist beyond their expected time, they may invite herniation of abdominal contents. (Eg...inguinal Hernia)
- Sometimes, the contents can squeeze through a **weakness in the normal muscle openings** which are meant

for passag of normal viscera This also can lead to hernias (Eg Hiastus hernia by the side of esophageal passage in diaphragm)

- **Previous surgeries & injuries** can create a weak spot in the muscle wall, so that part of the near by organs can pass through it producing a Hernia.

### ▶ WHY HERNIA IS A CONCERN ?

Usually the herniated content comes and goes back on relaxation (reducibility). Occasionally the loop of intestine or any other herniated content, may get stuck and is no longer reducible (irreducibility). Then in such a situation, the content can not be pushed back in to the abdomen When this happens, the irreducible part of the viscera, may lose its blood supply.(strangulation).

As we can not predict, when the hernia gets stuck in children, it is a cause of concern and

needs childrens surgeons advice. In females, some times the hernial content may be ovary with fallopian tube of that side. In such cases when it got stuck -the ovary and fallopian tubes may be at risk of gangrene. in some boys, hernia may be associated with undescended testis. In such cases,the testis is at risk of gangrene if the associated hernia gets obstructed. So in children, hernia is a cause of concern.

## ▶ Is there More Than One Type of Hernia in Children ?

Yes. There are more than one site, where a hernia can occur in children. The most common types include

- Inguinal hernia
- Umbilical hernia
- Epigastric hernia
- Incisional hernia
- Congenital diaphragmatic hernia
- Hiatus hernia
- Spigelian hernia

## ▶ What are the Common Hernias Seen in Children ?

### ● Inguinal Hernia

It is the hernia that occurs at the groin area. Four times more common in boys than in girls. It occurs in 1-5% of fullterm babies and up to 30% of the preterm babies. In boys,the inguinal hernia may extend in to the scrotum. In girls it may extend in to the labial area.

In boys, testes develops in the abdomen. During the seventh month of pregnancy, the testes descends to reach the scrotum through a passage called inguinal canal. A fold of abdominal layer called - processus

vaginalis gives direction and protection to the descending testis. After the complete testicular descent, the processus vaginalis gets obliterated to close the communication between abdomen and scrotum. In some children, because of unknown reasons, this communication remains open even after the descent of the testis and can lead to hernia development.

In girls the communication is called- the canal of knuck. It is smaller in size than in boys. Normally a fibrous tissue cord -called round ligament goes through the inguinal canal in females. Female hernia can develops, when the canal of knuck size is more, which produces weakness by the side of round ligament.

Hernia comes to parenteral attention, by development of expansile bulge at hernia site on crying, coughing,jumping or straining. This swelling goes-off automatically when the child becomes quiet. This visible, intermittent bulge on straining becomes more frequent in appearance and also increases in size with time. Normally the bulge will be the size of a lemon. It is a painless bulge initially. Rarely hernia comes to attention on first time with irreducibility and obstruction. This presents with irreducible bulge at groin, pain &tenderness, redness over swelling and later with projectile vomiting.

Hernia can be unilateral or bilateral. in unilateral hernia cases up to 30% will develop hernia on the other side in later life.

Surgery (herniotomy)is the option for inguinal hernia in children. It can be corrected either by open surgery or laparoscopic surgery. In laparoscopy the otherside of the abdomen can also be observed to rule out opposite side hernia. There is no waiting period for surgical correction, as hernia may get obstructed at any time. It is always better in children, to get hernia corrected at the earliest.

## ● Umbilical Hernia

Some babies are born with weakness or opening in the abdominal muscles around the bellybutton, covered by normal skin through which the intestines can protrude when ever the child strains...this condition is called umbilical hernia. It is most obvious and worrisome to parents, when ever the child cries, coughs or strains. Umbilical hernias are more common in preterm babies, low birth weight babies and female babies. Size of the hernias can range from 2cm to 6cm.

In most of the instances, the umbilical hernia causes no discomfort. There are two differences between umbilical hernia and other hernias in children. Umbilical hernias rarely get obstructed or strangulated unlike other hernias, as the hernia defect is wider compared to other hernias. Second difference is unlike other hernias, which does not close on their own, most of the umbilical hernias will close spontaneously by 4 yrs of age. That's why pediatric surgeons will advice wait and watch policy rather than surgery for umbilical hernias in most of the cases. Surgery (hernia repair + umbilicoplasty) is done only when the hernia is very large, when it got irreducible or strangulated, or when it does not close by the age of 4yrs. Surgeons try to create near normal appearing umbilicus after closing the defect (Umbilicoplasty).

## ● Epigastric Hernia

it is a bulge through an abnormal opening in the wall of the midline abdominal muscles. Epigastric hernia occurs in the midline above the bellybutton. Epigastric hernia affects mainly children and young adolescents compared to adults. It occurs in the area between the chest and belly button (central upper part of the abdomen)known as the epigastrium. It differs from umbilical hernia in that it occurs above the belly button in the midline,where as umbilical hernia occurs through the belly button.

An epigastric hernia is a small type of hernia. Only the abdominal wall lining known as –peritoneum or intestinal lining called omentum will, protrude through this defect. In rare cases, the defect is large enough to allow the loop of intestine. It needs to be corrected by surgery as an elective procedure. In some situations,when the swelling becomes red,tender to touch, excessive crying,with vomiting then it needs to corrected by emergency surgery to prevent gangrene of the intestine.

## ● Incisional Hernia

This type of hernia occurs after the child previously undergoes abdominal surgery for some other surgical condition. Loops of intestines herniates through partially healed surgical incision. This hernia develops when the surgical wound gets infected or gets weakned due to poor healing process. Any type of abdominal surgery, including laparoscopic surgeries can produce incisional hernia. It usually develops 2 weeks to several months after the surgery. it manifests as a bulge at the surgical incision site, when ever the child coughs,cries or strains.

Incisional hernia also carries the same risk of irreducibility and strangulation like other hernias. Normally reducible hernia is a painless protrusion of bowel in to the weak defect area, but once it gets obstructed it will become painful. Surgery is the usual form of treatment for this form of hernia. The type of surgery depends on the size of the incisional hernia. Open / laparoscopic surgical repair using mesh is the preferred method for the large incisional hernias.

## ● Femoral Hernia

A femoral hernia is less common than inguinal hernia. More common in females due to wider pelvis. 75% of femoral hernia occur

in females. it occurs at a lower level in the groin than inguinal hernia and it is smaller compared to inguinal hernia.

It is caused by protrusion of contents in to the inside of the thigh or through the top of the groin through a region called –femoral canal. This tubular shaped opening lies in front of the thigh at the top. It is the point where major bloodvessels pass from abdomen in to thigh. This is a weak point –through which femoral hernia occurs. Weakness in femoral area, rise in abdominal pressure, obesity, constipation can increase the chances of femoral hernia.

Because of the small size, most of the patients do not feel any symptoms until it gets complicated. The common symptoms are dragging feeling or a dull ache around lower abdomen. The main complication of femoral hernia is it can get irreducible, obstructed or strangulated. Surgery is the treatment of choice for femoral hernia. No waiting period for surgical correction, it has to be corrected at the earliest.

### ● Hiatus Hernia

Hiatus hernia occurs when a part of the stomach, which should reside entirely in abdomen, protrude upwards in to the chest. Upper part of the stomach pushes up leading to pain, abdominal discomfort and heart burn. Chest and abdomen are separated by a sheet of tissue called- Diaphragm. This diaphragm will have three openings called **hiatuses** to transmit the thoracic structures in to abdomen during their ongoing route. One of the Hiatuses is called - **Esophageal Hiatus**, which transmits food pipe called Esophagus. In some children due to weakness at the esophageal hiatal area, part of the stomach may move up along or by the side of esophagus in to thorax. This leads to weak junction at the esophago- stomach junction. (gastroesophageal sphincter area). Normally this sphincter closes the junction preventing stomach contents like acid to go up in to

esophagus. If there is Hiatus hernia this sphincter area does not function and allow acid and other gastric contents to reflux and cause damage to the esophagus.

The symptoms of hiatus hernia include - heart burn, acid reflux, chest pain, difficulty in swallowing, Belchings, hiccoughs, asthmatic like symptoms and croaking voice. Symptoms may worsen after meal, lying down or bending forward. Some children may be totally asymptomatic and hiatus hernia is detected incidentally on evaluation. Surgical correction is the preferred option for hiatus hernia. At surgery the herniated stomach is pulled back and fixed in the abdomen along with closure and repair of the defect in esophageal hiatus.

### ● Congenital Diaphragmatic Hernia

Diaphragm is the partition between the chest and abdomen. sometimes due to developmental anomaly & improper formation, defect occurs in the diaphragm leading to herniation of the abdominal contents in to the chest. The contents varies in quantity and type of organs herniation to the chest from case to case. Organs ranging from stomach, small intestine, large intestine, spleen, kidneys & left lobe of liver can herniate in to the chest.

The herniated contents will interfere with the development of ipsilateral lung and also the heart. There may be associated rotational problems of the intestines. This leads to severe respiratory distress in the new born child. The degree of lung hypoplasia depends on the amount of compression on the developing lungs. If both lungs are hypoplastic, survival is difficult. Some cases of congenital diaphragmatic hernia cases will come to attention not in newborn period, but later in life. This is due to reasonably developed lungs. If it presents in later life, it presents with repeated respiratory infections.

Congenital diaphragmatic hernia, is diagnosed

at birth by clinical picture and X-Ray chest and abdomen. In newborn children with CDH, stabilization of the child by mechanical ventilation followed by surgical correction is the choice of treatment. During Surgery, the herniated contents are returned back in to the abdomen, followed by repair of the defect in the diaphragm. Some children needs ventilator support for some days after surgery.

## ▶ Common Queries From Parents

### ● What is the difference between hernia and hydrocele in children and adults ?

A Hydrocele is a collection of fluid in the layers around the testis. A hernia is protrusion of intestinal contents through an abnormal opening. There is difference in how & why they occur in children and adults.

In children both hydrocele and hernia, occur due to persistence of communication between abdomen & scrotum. If the communication is narrow, it will allow only fluid passage from the abdomen leading to Hydrocele formation. If the communication is wide, it will allow passage of intestines or its fatty covering (omentum) to the scrotum it is called hernia. the main difference between hydrocele and hernia is the size of the defect and content passing through defect. As the etiology is same - the surgical procedure is same for both lesions in children i.e identifying, separating, ligating and disconnecting the patent communication between abdomen and scrotum via groin approach. Even though swelling is in scrotum, in children surgery will be at groin. No muscle repair or mesh repair is required in children.

In adults both the lesions etiology is different. Hydrocele is due to excessive secretion or defective absorption of scrotal fluid. The pathology is due to local problem. so surgical correction will be done on scrotum only.

Hernia in adults is due to muscle weakness, so surgery will be done by open surgery at groin level or laparoscopic mesh repair via abdomen. Muscle repair and strengthening is the main component of repair in adults.

### ● In children, either Hydrocele or hernia which is an emergency ?

In children, both hydrocele & hernia are due to same etiology i.e due to persistence of communication between abdomen and scrotum (which is supposed to close at birth). as the etiology is same surgical procedure is also same for both hydrocele & hernia correction in children. But difference is in timing of surgery. Hydrocele is a fluid collection, does not have any major complications. So, surgery can be done 12 to 18 months after birth. Waiting period is there for hydrocele in children.

But, a hernia is protrusion of intestinal loops through the patent communication. A hernia can get obstructed at any time which is dangerous. So, there is no waiting period for hernia in children. Hernia has to be operated at the earliest after diagnosis. In that sense – out of the two, hernia is an emergency.

### ● Is there any speciality in female hernia ?

Female hernia differs in many ways from hernia in boys. In girls the hernia content may be intestine, its fatty covering (omentum) or fallopian tubes with ovary. so internal genital organs can be a content in girls hernia that risk will not be there in boys.

Hernia repair is comparatively easy in girls – as the contents going by the side of hernia sac through groin (inguinal canal) is only round ligament, which is a fibrous tissue. Round ligament can be tied and excised along with hernia sac without any major complications. But in boys, the hernia sac is intimately attached to the vas and testicular vessels, during its course through groin

(inguinal canal). These vital structures has to be carefully separated and protected during ligation and cutting of hernia sac. So, surgical procedure is to be more delicate in hernia in boys.

Rarely, disordered sexual differentiation (DSD) condition called - testicular feminization syndrome presents as a bilateral hernia in girls. So, hernia on both sides in girls needs a detailed examination.

#### ● **Role of laparoscopy in hernia correction in children**

Laparoscopy is advantageous in hernia repair in children. Laparoscopy is done through small instruments introduced from abdomen, the advantage in laparoscopy is that the surgeon can have a look at other side hernial orifice from inside in case of unilateral hernia. Laparoscopy is of role in wide incisional hernias in children, where mesh repair is required.

#### ● **Is Physical activity to be reduced after hernia surgery ?**

Not necessary. The post operative restrictions are only to be followed for one week. In adults, where the reason for hernia is muscle weakness and repair is done by mesh placement, restrictions and post-operative precautions are more. In children, where hernia is due to patent communication and repair does not need mesh repair, there is no need for prolonged restriction of physical activity.

#### ● **Any long term effects on potency & fertility in hernia operated children ?**

Not at all. During hernia repair in children, the hernial sac is isolated and separated from the vas & testicular vessels. If the surgeon is careful and experienced, no damage is done to the genital structures. No longterm affects on the potency & fertility due to hernial surgery.

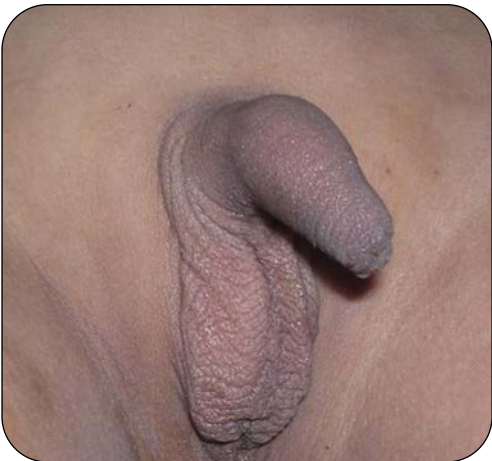



## UNDESCENDED TESTIS IN CHILDREN



**Left Sided Undescended Testis**

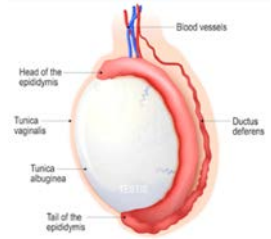


**Both Sides Undescended Testes**

# 04

## UNDESCENDED TESTIS IN CHILDREN

The way the genitalia form during development of baby will be very interesting particularly the development of testes. This is because the testes will not develop in the normal place scrotum where they reside. They develop in the abdomen near the developing kidneys and they descend down during later part of pregnancy to come and reside in scrotal sacs.



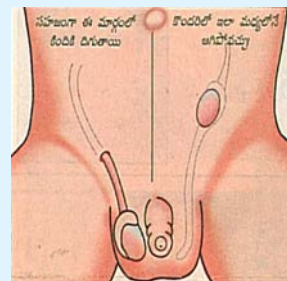
In some, this process will not take place properly. The testes which are supposed to descend to scrotum may not complete their descent properly and may get arrested at various places along the route. It can happen on one side or both sides. What will happen if the testes do not descend? Will it affect their function? Is there any other complications due to improper descent?

### ▶ How many children will be born with this anomaly?

As the foetus is developing in the womb of the mother, the raising pressure in the foetal abdomen, hormones released from the developing testes and the contractions of the attachments to the scrotum will act on developing testes and make it to descend. This process will not happen properly in 3% of full term and 30% of preterm babies. They are born with undescended testis. By the age of 1 year the incidence of undescended testis will be 1% that is 1 in 100 male children will have testicular descent problem. Because the descent of the testes will be completed in the last months of the pregnancy 30% of the premature babies will have undescended testes.

### How the testes will descend normally?

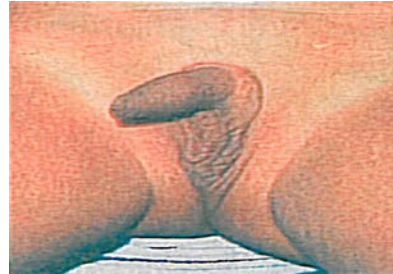During fertilization, if the sperm contains Y chromosome, the foetus is destined to become male. Under the influence of sex determining factor on Y chromosome the developing gonad will become testis. This formation occurs between 6-8 weeks of pregnancy. At this stage they are at the level of developing kidneys. By 8 weeks of pregnancy period they will start producing male hormone -Testosterone and Mullerian inhibiting substance. Under the influence of these hormones, the testes will descend to groin area by 17-18 weeks. It will take rest at that place till 28 weeks as the pathway (inguinal canal) is not formed. Once the groin pathway is clear the testis will start descending into the scrotum by 40 weeks. This is partly due to factors released from genitofemoral nerve, contractions of attachment to scrotum (Gubernaculum) and testosterone affect. The male hormone testosterone gets converted to active form and acts on external genitalia and develops it. It will be completed by 15-18 weeks.



## ▶ Reasons for not descending properly ▶ How to identify undescended testes

The exact reasons for non descent of the testes are not known. Hormone (testosterone) production deficiency is one of the main reason. Internal developmental problems in the testis itself may also contribute to non-descent. There may be obstructions in the pathway of descent. This can happen if there is development of peritonitis in the embryos abdomen during development. Another reason is failure to maintain abdominal pressure due to musculature defect in the abdominal wall. Genetic and chromosomal abnormalities in the family. Sometimes the testes may not develop at all on oneside.

The improper descent of the testes can be detected easily by looking at the scrotum. By simple inspection and clinical examination.



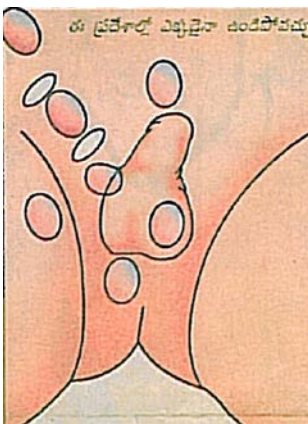
## ▶ Sites where testes can get stuck

In some the testes may remain in the abdomen itself (intra-abdominal testis). In some it may come out of the abdomen and get arrested in the normal route of descent. Then it will be found in the groin (inguinal canal) or entry point in to the scrotum (High scrotal position). Sometimes it may descend for some distance and gets deviated in to a different route (Ectopic testes). In such situations, it is found in the perineum, infront of penis, in the opposite hemiscrotum or in the thigh. Sometimes it may not develop at all on oneside.

## ▶ Problems that will arise if they do not descend

The undescended testis if it is not treated in proper time it can lead to many complications.

- **Testicular function** : As the scrotum is 2-3 degrees foreignheat temperature cooler than the rest of the body, in case of undescended testes as the testes is closer to the body, it will get exposed to higher temperature. As the time passes the testes will undergo thermal damage leading to damage of sperm producing tubules. This can lead to infertility which is higher if both testes are not descended.
- **Hernia association** : as the testes is not descended, the pathway is not closed. so almost all cases of undescended testis will have associated inguinal hernia
- **Torsion testis** : As the testis is not descended fully, it will not be fixed properly. So undescended testis will be prone to torsion testis due to poor fixation to scrotum.
- **Cancer development** : the undescended if it is not treated properly in time, it will lead to testicular damage. Later



cancerous growths can develop in the damaged testis. Studies shows 1 in 20 abdominal testis and 1 in 80 groin testis will undergo cancerous changes if not treated in time.

- **Trauma to testis :** if the undescended testis is in groin, it will undergo physical and constant muscular trauma.
- **Psychological changes:** The children with undescended testis may develop psychological upset as they are growing up as their external genitalia are looking different

### ▶ **What is the right time for surgery ?**

Many parents even if they found that their child's testis is not descended, they do not take any medical advice due to the misconception that the testes will descend on their own by 5 -10 years of age. This is not a correct and wise decision. If at all the testes descends on their own, it will descend by 6 months of age. If it does not descend by that time, the surgical intervention should be done between 6-9 months of age, maximum by 1 year of age the issues has to be settled. If not the testis will undergo thermal (heat) damage. So, ideal time for intervention for undescended testes is 6-9 months.

### ▶ **How the surgeons will correct the undescended testis anomaly ?**

Each testis will have blood vessels which supply the blood to the testis and spermatic cord (Vas) which will carry the formed sperms out of the testis when the child becomes an adult. both are important attachments to the testis. Even in cases of undescended testis, the vas is always long, sometimes may be looped. So in correction of undescended testis bringing vas along with testis is not a problem. The main problem comes with blood vessel attached testis (testicular vessels).

If the testicular blood vessel length is adequate after mobilization, there is no problem in bringing and placing the testis in the scrotum (standard orchidopexy). If the testicular blood vessel length is not sufficient, the testis is mobilized as long as possible and placed at that level, to be brought down after 6 months by another surgery (Staged orchidopexy). If the testis is stuck in the abdomen, during its descent (Non-Palpable undescended testis) surgery involves a special technique called -Fowler stephens technique. This technique is done through laparoscopy. The length of testicular vessel is assessed and status of alternate (collateral) blood supply is assessed. The main testicular vessel is blocked to see the adequacy of alternate blood supply. If the testis is maintaining blood flow on collaterals, when the main testicular artery is ligated then testis is brought down in to scrotum on collateral blood supply. This is done in two stages usually with a gap of 6 months (Two Stage Fowler-Stephen technique).

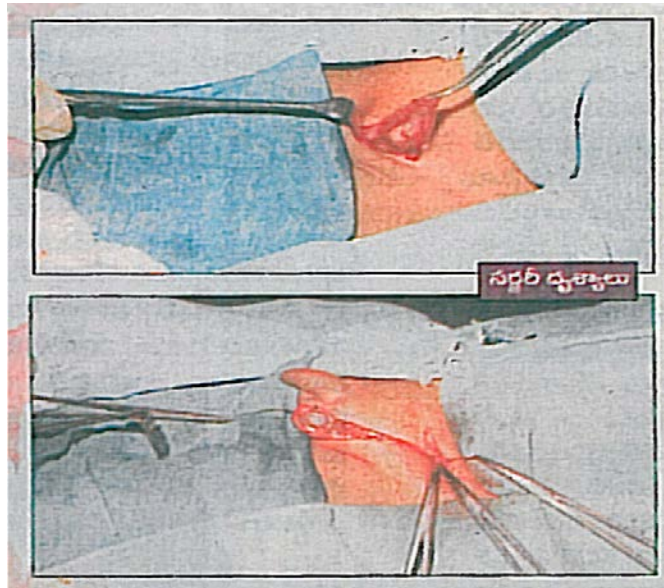
If the testis is hypoplastic, if the collateral blood supply is not adequate if no other option is feasible, the testis has to be removed. undescended testicular tissue should not be left in the body because of the risk of development of cancer in the damaged testis. Loss of one testis will not affect the future potency & fertility of the child. If the child is having a psychological feeling a prosthetic, artificial testis made up of silastic material can be placed in the scrotum for appearance purpose.

### ▶ **If the testis gets pulled up and comes back to normal position ...**

This condition is called – Retractable testis. Retractable testis is a normally descended testis but pulled up by the overactivity of the cremasteric muscle, the thin muscle surrounding the testes. When the child is awake and active, the testis will be pulled up

but when the child is sleeping and relaxed, the testes will be normally located in the scrotum. This muscle pull will regress by 10-12 years of age. A Retractable testis does not need surgical

correction, as it is a normally descended testis and most of the time the testes will be in the scrotum.

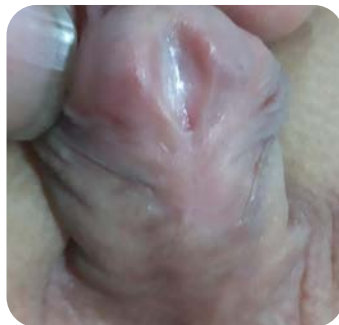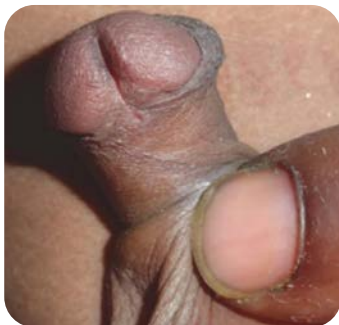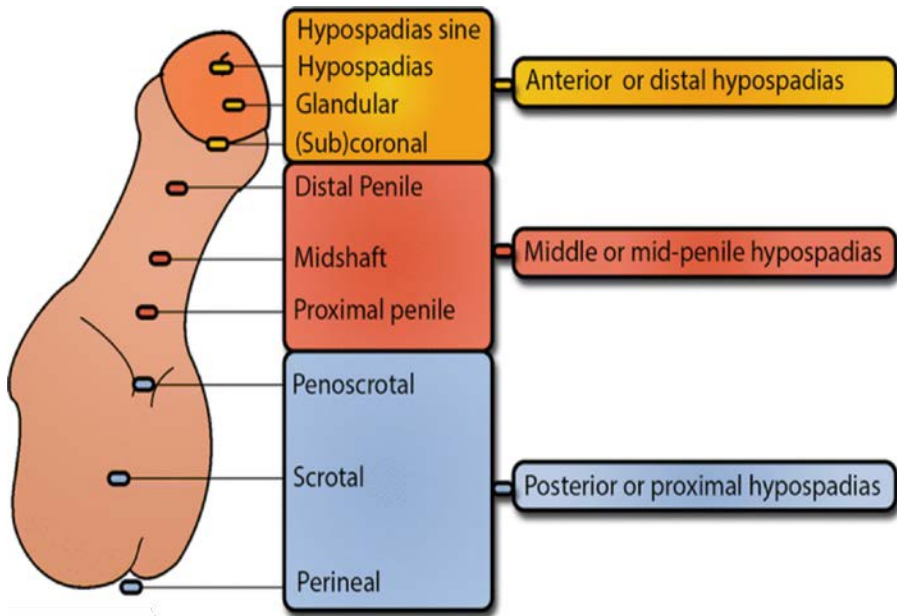


### Key Points :

If testis is not descended, it should be surgically corrected by 6-9 months of age



## HYPOSPADIAS IN CHILDREN





## HYPOSPADIAS IN CHILDREN

If the child is born normally with good weight & good health, the entire family will go in to celebrations. But if the same child is born with an anomaly, the family will go into a mood of despair. Some congenital anomalies are very peculiar, particularly this is seen in cases of anomalies of external genitalia. The newborn male is looking good but if you look at his penis- it looks different with urinary opening not at the tip. Entire family will go in to depression about the future of the child. The common external genital anomaly which occurs in male child is hypospadias. In Hypospadias anomaly, the urethral orifice (urine carrying tube) will not be at the tip, instead it will be somewhere on the under surface of the penis. Because of this the penis will not look normal. The urine in this anomaly will not come from the tip of the penis, but it will come from ectopic orifice on the undersurface of the penis. Along with this the curvature of the penis will bend towards undersurface, it is called chordee. It is not a rare anomaly and there are methods to correct it. Because of the lack of awareness & apprehensions, some parents will not take medical advice and help till the adulthood. In such a situation, correcting hypospadias in adults is not an easy task. This anomaly needs public awareness.



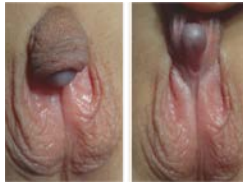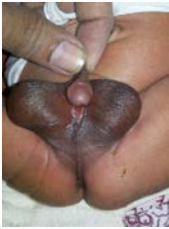### ▶ One in 200

Normally the urethral opening should be at the tip of the penis, the tip of the penis (glans) should be round and the tip should be covered by skin all around. In hypospadias anomaly, the urinary orifice will not be at the tip, it will open on the undersurface of the penis from just below the tip to area in front of the anus. The tip will be bean shaped. The skin will not cover all around but it looks like a hood on the upper part of the penis. Abnormal look of foreskin and penis, abnormal direction of urine stream and end of the penis curves downward.

It is not a rare anomaly it occurs 1 in 200 live male births. It is the second commonest birth defect in males after undescended testis. Many doubts will arise in the minds of the parents once their child is born with hypospadias.

### ▶ Sites where Hypospadiac Urethral Orifice can Present

Normally the urethral opening should be at the tip of the penis, the tip of the penis (glans) should be round and the tip should be covered by skin all around. In hypospadias anomaly, which is a birth defect, the urinary orifice will not be at the tip, it will open on the undersurface of the penis. Some can be minor and some may be more severe. In around 50% cases the orifice will open a short distance on the undersurface of the penis. They are called -glanular, coronal, subcoronal type of hypospadias (Distal type). In some around 30% they open more proximally on the under surface of the body of the penis – distal penile, mid penile and proximal penile hypospadias (Mid type). In around 20% cases the orifice will be more proximal – in the junction of penis and scrotum (Penoscrotal type), Mid scrotal (scrotal type), and in the perineum in front of anus (perineal type). Along with this, the penis may look smaller and in a downward bend.



## ► Why it Happens ?

The exact cause for the development of hypospadias is not known. It is a defective formation of the urethral tube, which is influenced by the male hormones released from the developing testis. Defective formation of the testosterone or defective conversion into active form or if hormone receiving receptors are not present in the target organ, external genital anomalies will occur in the males. Till 8 weeks of foetal life the genitalia are indeterminate. From 8-14 weeks depending on the chromosomal pattern, the sex assignment and external genital development will proceed. So, hypospadias development will happen between 8-14 weeks of development. Genetic abnormalities and familial factors also will lead to hormonal deficiency and hypospadias development.

some factors that affect the risk of having a baby boy with hypospadias:

- Age and weight: Mothers who were age 35 years or older and who were considered obese had a higher risk of having a baby with hypospadias.
- Fertility treatments: Women who used assisted reproductive technology to help with pregnancy had a higher risk of having a baby with hypospadias.
- Certain hormones: Women who took certain hormones just before or during pregnancy were shown to have a higher

risk of having a baby with hypospadias.

- Common in preterms and low birth weight babies
- In twin babies
- If father of the baby is having genitalia or other urinary anomalies
- Diabetic mother babies
- When exposed to cigarette smoking or pesticides before pregnancy

## ► What is the problem if it is like that ?

In hypospadias anomaly, the male child will have difficulty in urination. They can not stand and urinate as the urinary stream is downwards. This will lead to psychological issues in children. Some times the urethral orifice is narrow and it can lead to recurrent urinary infections. If there is severe chordee, it can lead to sexual problems when they become adult. But severe chordee will occur in only small percentage of cases. Usually children will start developing genital awareness by 3-5 yrs of age. In school going children, if their genitalia are abnormal they develop psychological upset and depression. So it is always better to correct hypospadias anomaly before school going age. The three main problems with hypospadias are ...

- **Abnormal urine stream.** The urine stream may point in the direction of the opening, such as downward. Or it may spray in many directions.
- **Curving penis.** As your child grows, his penis may curve. This can cause sexual problems later in life.
- **Infertility.** If the urethral opening is closer to the scrotum or perineum, your child may have problems with fertility later in life.

## ▶ **What is the solution? How it will be corrected surgically ?**

The main aim of surgical correction is to bring the urethral orifice to the tip of the penis. If there is bending of the penile curvature (chordee), it will also be corrected. There are many surgical techniques for correction of this anomaly. The final aim of surgical correction is, not only to have a normally appearing penis but also to have a functionally normal organ. Depending on the type of hypospadias, the surgical correction can be done in single stage or in staged manner. If the size of the penis is small, three doses of testosterone is given at monthly intervals to increase the size of the penis. Three locally available tissues are used usually for neo-urethral tube creation. The non-tubularised remaining distal urethral plate, inner layer of dorsally hooded skin or the dorsal skin itself can be used for creation of urethral tube till tip of the penis. The procedures are grouped under three headings.

**Urethral tubularization techniques:** in which the good distal non-tubularized urethral plate is tubularized by suturing the cut edges through parallel incisions

**Urethral augmentation techniques:** in which a rectangular bit locally available tissue is taken (like inner layer of dorsal skin) along with its blood supply and kept it over the existing non-tubularized distal urethral plate. This augmented tissue will act as floor of urethra.

**Urethral replacement techniques:** where the entire urethral tube is created from locally available tissues and one end is attached to the existing urethra and other end is brought till tip of the penis. A transurethral catheter is kept through neourethral tube for urinary diversion.

In cases where the child has undergone multiple procedures, and the locally available tissues are not adequate to be used (Hypospadias cripple) - the distant tissues

like wet layer (Mucosa) from lower lip or side of the cheek are used. This procedure is called Bracka procedure. This procedure is done in two stages. In first stage mucosa is kept on the undersurface of the penis, in second stage the laid mucosa is tubularized as urethra.

## ▶ **Timing of surgery**

Circumcision should not be done at birth, as the foreskin may be needed for repair. Surgical correction can be done between 6 months -24 months. but around the world the surgical correction is started around 1 year of age. The aim is to complete all stages of correction before the child enters the school. as the child develops genital awareness between 3-5 years of age, it should be corrected before 3 years of age. if it is done after that time, the children will have a feeling lifelong that something has been done on their genitalia. Some types of hypospadias needs staged procedure, so if the first stage is started at 1 year of age then all the stages can be completed by school going age. Children will not develop urinary control till 3 years of age. If surgery is completed before 3 yrs, urinary training will not be affected. If it is done after 3 yrs out of fear they will hold the urine and toilet training will be delayed. If it is delayed till adulthood, it will lead to sexual problems and infertility problems. so it is always better to correct hypospadias between 1 ye -2 years of age.

## ▶ **How will be the results ?**

With the olden techniques, results are only partially successful. Now with the latest techniques available around the world, the results are very satisfactory now. Except in more proximal varieties and in those associated with disorders of sexual differentiation (DSD) the appearance and function of penis will become normal after hypospadias correction. The potency and fertility capacity will become normal after surgery.

## ▶ Can we avoid development of hypospadias ?

The exact reason for hypospadias is not known. It is occurring in all races and in all societies. In some if father is having hypospadias, the child is born with hypospadias. For this to develop, in addition to genes the environmental factors are also having an affect on the developing baby during pregnancy. During development in mothers womb, the genitalia are indeterminate till 8weeks of life. Later under the influence of presence XX or XY chromosomes, the gonadal development will proceed. These gonads will produce hormones which will lead to development of external genitalia. During this development, if the hormone production is defective in males it will lead to underdevelopment of male external genitalia and anomalies like hypospadias will develop. So, in the early weeks of pregnancy, the mother should not get exposed to medicines, chemicals, pesticides, and should take good & hygienic food, stay away from industrial areas, not to take foods with artificial colours. these things will help to some extent to reduce the incidence of hypospadias anomaly

## ▶ Technique & experience is the key

Children are very delicate and their external genitalia are more delicate. That's why any corrective surgery on external genitalia in children particularly Hypospadias will be very delicate. So, for hypospadias surgery experience and technical skill is very important. The first surgical attempt is very crucial in hypospadias. If it is corrected at that attempt it is well and good. Multiple surgeries will lead to development of scar tissue and loss of locally available tissue for repair. Finally they land up as- Hypospadias cripple. So it is always better to have the hypospadias being corrected by experienced and technically skillful person.

## ▶ What are the complications that can occur after hypospadias surgery

If it is done by an experienced person,the complications are less. But still even in experienced hands certain complications can occur. The common complications that occur after hypospadias repair are.. urethral fistula formation (urine coming as drops again from undersurface after surgical correction). This will happen if the urethral tube repair has not healed well. If there is infection after surgery or if wound has not healed well,it will lead to scar formation which can later leads to stricture development. Diverticulum (ballooning of urethral tube while passing urine is the another complication noted following hypospadias repair. These complications can be reduced if certain precautions are taken and if it is done by dedicated team of experts.

## ▶ Will they have normal potency and fertility when they grow up ?

Hypospadias is an anomaly of urethral tube formation, at the same time the other structures of the penis are not affected at all. Above the urethral tube,there will be erectile tissue like two cigar bundles (Corpora Caverosa). They are not affected in hypospadias anomaly. So in most of the cases of hypospadias, the potency and fertility will not be affected. Only in those cases where the penis is very short or the bending (chordee) is very severe, there will be problems with the sexual life. Even severe chordee can also be corrected to a reasonable extent with surgery.

## ▶ If hypospadias anomaly is not corrected till adult age...

Most of the hypospadias cases are distal type (80%). In these type cases the urethra opens a short distance from the normal location. so most of the cases which are

not corrected in childhood if they grow up, don't face much problem in sexual life or parenting. But in proximal cases, where the urethral opening is present in the middle of the penis, or penoscrotal junction or more proximally, will have a lot of problems if the anomaly is not corrected at the right age. Surgically correcting hypospadias anomaly

in grown up is a challenging task. It is not an easy thing to do. Complications chances are more, even though they are in adult age, the anomaly is congenital. So it is better for them to consult a pediatric surgeon even in adult age. For surgical correction of hypospadias, as pediatric surgeons are more experienced in hypospadias repair.

### Key Points :

1. Hypospadias anomaly in children has to be corrected between 12 to 18 months of age.
2. Circumcision should not be done in children when there is Hypospadias anomaly, as this skin may be useful for surgical correction of Hypospadias.

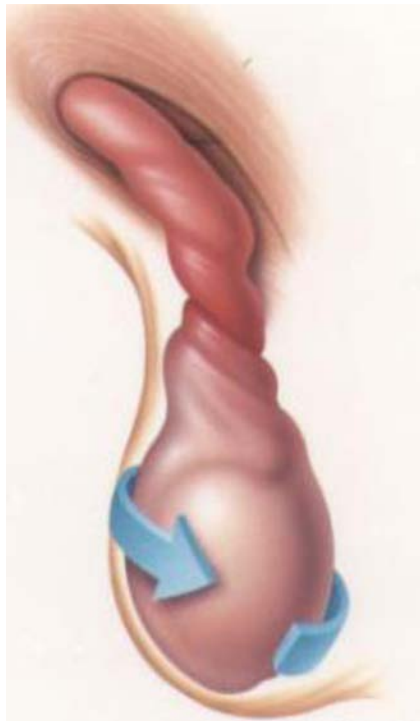
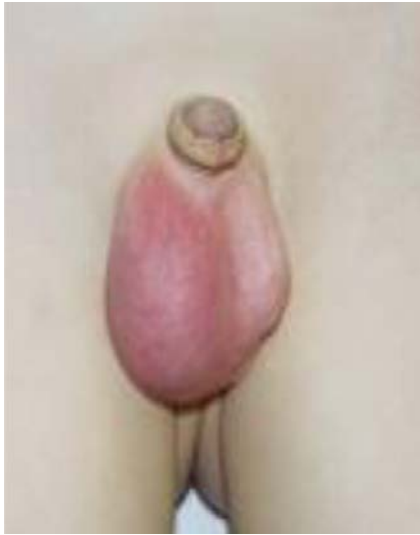




## TORSION TESTIS IN CHILDREN

## Torsion Testis in Children

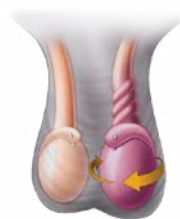



# 07

## TORSION TESTIS IN CHILDREN

Some conditions in children, the parents may not give much importance until and unless they cry with pain. At that time the parents will become tense and panic. This is not good for the child in some situations. Typical example is torsion testis. This is one of the emergencies in children. Parents need to have an awareness about this condition.



If a child cries with history of pain in scrotum, never ignore. It may be a torsion testis in which the testis rotates on its blood vessels leading to swelling of the scrotum and gangrene of the testis. If it is torsion testis it has to be intervened with in 6 hours otherwise the testis if it becomes gangrene it has to be removed. Remember Torsion testis is an emergency situation. If the condition is not treated quickly, it can lead to loss of the testicle.

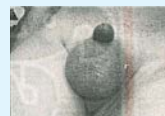### ▶ What is torsion testis

Testicular torsion is a painful twisting of a boy's testicles and spermatic cord. The spermatic cord is a set of nerves, ducts, and blood vessels that leads from the groin to the testicles. Torsion can happen to one or both testicles. Torsion causes blood not to flow to the testicles.

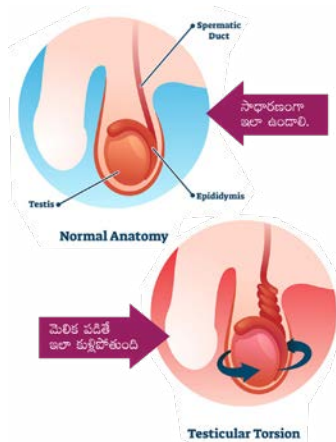
testicular torsion is a medical emergency. It happens when the testis and spermatic cord, which provides blood flow to the testicle, rotates and becomes twisted. This cuts off the testicle's blood supply and causes sudden pain and swelling. Testicular torsion usually requires immediate surgery to save the testicle.

### What Causes Torsion Testis

Both testes are present in the respective hemiscrotum with a covering of a layer called tunica vaginalis. This tunica vaginalis fixes the testes to the scrotum so that testes moves up and down but not around. Testicular torsion in a baby happens when the tunica vaginalis around the testicles doesn't attach properly to the scrotum. Most cases of testicular torsion are in males have a condition called the bell clapper deformity. In this deformity, the tunica vaginalis covers all around and high without fixing the testes. This allows the testes to turn and twist within the scrotum. When testes undergoes torsion, the spermatic cord which is attached to the testes will also get rotated along with its blood supply. Torsion testis is more common also in testes which are not descended completely in to the scrotum (undescended testis).



It can also occur in testis which has developed a tumor or mass. The weight of the mass can rotate the testis. Sometimes severe trauma to the testes can rotate the testes and cause torsion. In severe cold conditions also the testes will undergo torsion because of the contractions of the scrotal muscle and skin.



sudden pain and redness in scrotum without any reason- torsion testis has to be ruled out.

### ▶ How to confirm

History of sudden pain and redness with swelling of the scrotum will give a clue that it may be -torsion testis. On clinical examination by the doctor -the testes will not be in its position and it will move up a little bit. On lifting the scrotum up the pain will be increased. The immediate and urgent evaluation needed is ultrasound examination with doppler study. On ultrasound, the size of the testis will be enlarged with decreased or absent blood flow in the testis. Immediate exploration is advised rather than losing time with investigations because the first 6 hours are very important.

### ▶ Who will develop torsion

Torsion can happen to boys and men of any age, but is most common in 12- to 18-year-olds. It can happen after strenuous exercise, while someone is sleeping, or after an injury to the scrotum. Often, though, the exact cause isn't known. There are two common ages at which torsion testis can occur. one in neonatal period and other at adolescence.. It can also happen when a baby is growing in the mother's uterus, or shortly after a baby is born. Torsion testis is more common on left side.

### ▶ How torsion testis is treated

Emergency exploration is the only option for the torsion testes. The testis is derotated and observed for viability. If the testis is frankly gangrenous and not viable, then the testis is removed (Orchidectomy). If the testis is viable and blood supply is regained and testis has changed its colour, then the testis is fixed in the scrotum (orchidopexy). The opposite testes is also fixed at the same time as the abnormality of fixation may be there on the otherside also.

### ▶ When to suspect torsion

Sudden pain in scrotum with development of redness are the two important symptoms for torsion testis. Some may feel pain in lower abdomen. Associated with this, there may be fever, nausea and vomiting. If the scrotum is touched, the child will cry with pain. On examination the testes seems to be moved up.

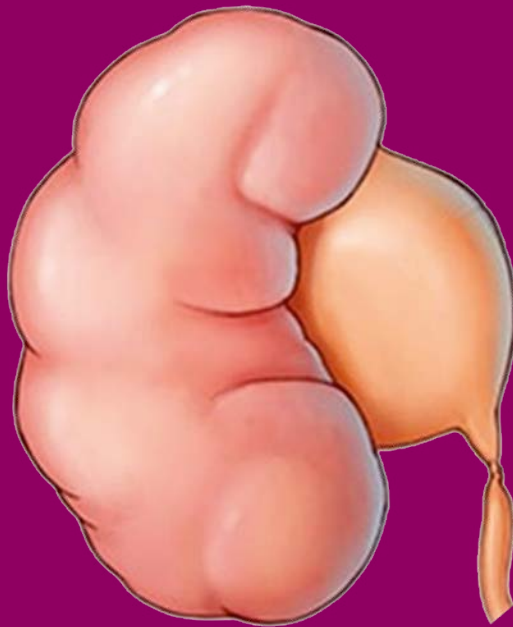First 6 hours are crucial for saving the testis. If it crosses 12 hours, possibility of saving the testis is remote. So, suspecting, identifying and intervening surgically immediately is very important in torsion testis.

Pain in scrotum, redness, and pain on touch are the three characteristic features of torsion testis. Later the redness and swelling will spread to the entire scrotum, this is called angry scrotum. Because of this if there is

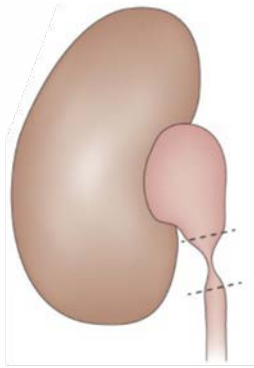
If one testis is removed, there is no problem with the male function. as far as potency and fertility is concerned loss of one testis will not create trouble but loss of both testes can lead to infertility.

### Key Points :

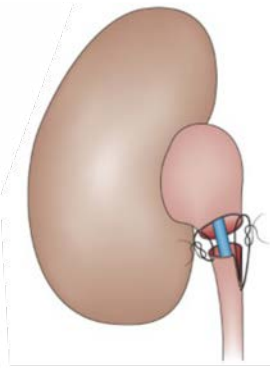
Any Red, Painful, Angry looking scrotum has to be taken seriously. Boys need to know that genital pain is serious. Ignoring pain or simply hoping it goes away can lead to severe damage to the testicle and even its removal. The loss of one testicle won't prevent a man from having normal sexual relations and is unlikely to interfere with fathering children.



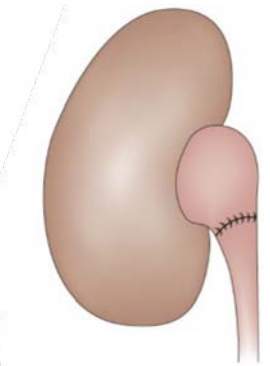
## HYDRONEPHROSIS IN CHILDREN



**PUJ Obstruction**



**Pyelo Plasty Operation with DJ Stent**

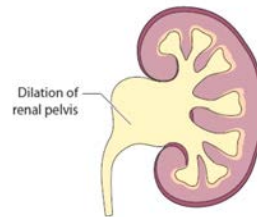


**Pyelo Plasty Operation**

# 8

## HYDRONEPHROSIS IN CHILDREN

Ramya got married two years back. She was confirmed by gynaecologist as pregnant one month back. Everything seems to be alright till second trimester ultrasound. The attending lady doctor said there is a problem in baby's one of the kidneys. The right kidney is swollen (hydronephrosis). Her dreams are shattered and she is panicking.



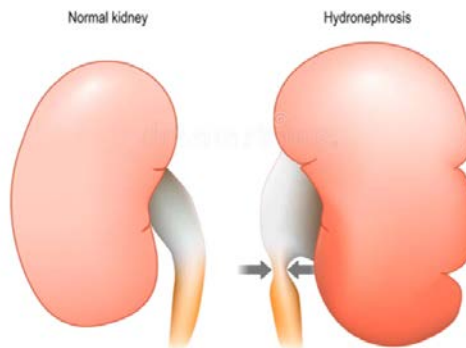
Many questions arise in her mind about the baby's health

- why this happened to my baby ?
- How will be my baby's health after birth ?
- How the right kidney will function? Will it function at all ?
- Will it regress itself before birth ?
- will the baby need surgery to correct the kidney problem ? if it needs can my baby withstand the procedure ?
- Is there a need to remove kidney after birth ?

This problem is in one of the major & important organs but it will not create trouble in all. In some of them, it regresses on itself by the time baby is born. In some cases, it may progress and needs surgical correction. Here we will give a detailed picture on how such kidney's problem (hydronephrosis) will progress and how doctors will manage such problem. This will clear the doubts from the minds of mothers like Ramya, who carry the babies with hydronephrosis.

Hydronephrosis is a condition affecting the kidneys. In this condition, the kidneys are abnormally dilated or overfilled with urine as the urinary passage down is not clear. It is dilatation of the kidney specially the renal pelvis (the place where urine is collected & stored after its production). It is diagnosed and its severity is graded based on the width (antero-posterior diameter - APD) of foetal renal pelvis. Hydronephrosis is diagnosed

antenatally if renal pelvic diameter is more than 4mm in second trimester and more than 7mm in third trimester. It can affect one kidney or two kidneys (on both sides). It is transient and resolves on its own in about one third to half of all cases. But in some cases (roughly one-third cases) it progresses to cause kidney damage. So, it is important to distinguish infants with significant obstruction to urinary passage, who require long-term follow up/ surgery from those who have a transient hydronephrosis with minimum need for invasive investigations.



### ▶ Why this hydronephrosis will develop ?

Abdomen is like a two-compartment room. The area where intestines and other solid organs reside is called Peritoneal cavity. The area behind that containing the kidney and ureter is called retroperitoneum. So kidneys

are present in a separate compartment in the abdomen behind the intestines. Urinary system have two parts. Urine forming system which is the functional area of the kidney called - cortex, and after that to carry the formed urine down we have urine collecting system. Both units will form separately. renal functional unit will develop locally in retroperitoneum from middle (mesodermal) layer of the body in the pelvis. It ascends up to reach the adult position of loin area during ninth week of gestation.. The collecting system develops as ureteric bud from below and ascends up. Both will meet and cross-signaling will lead to development of both units in correlation.

Foetal kidneys starts to form urine from the end of first trimester i.e 11-12 week of gestation and continues throughout foetal life. This urine will flow from kidneys in to the bladder through ureters. With bladder contractions, the urine will get emptied in to the amniotic fluid. Urine is the major source of liquor (amniotic fluid) from 14 th week of gestation onwards.

Any embryological insult during this complex renal system development can lead to various abnormalities. These insults can be due to abnormal genes, gene mutations, nutritional factors, environmental factors or drugs used during pregnancy. Exact etiology in individual case can not be detected. One such abnormality is Hydronephrosis due to pelviureteric junction obstruction, in this there is a narrowing at the junction of renal pelvis (urine collecting bag attached to the kidney) and ureter (the tube which carries urine down to the urinary bladder). This anomaly will lead to stasis of urine in the pelvis leading to raised hydrostatic pressure in the pelvis leading to backpressure changes on the functioning tissue of kidney. If the obstruction is not relieved in critical time it will lead to renal functional damage.

## ▶ If it is diagnosed during pregnancy ?

Once it is diagnosed antenatally, it needs a detailed foetal evaluation by TIFFA SCAN. evaluation includes

- At which term of pregnancy, hydronephrosis is detected
- Unilateral or bilateral renal involvement.
- Amniotic fluid volume (presence of oligohydramnios)
- Renal pelvic diameter
- Presence of Renal cortical cysts
- Bladder status –thickening / hypertrophy of bladder
- Other structural anomalies like gastrointestinal/ cardiac/ musculoskeletal anomalies.

Once it is detected – the parents are counselled about the condition and the further evaluation plan is explained to them.

The foetal kidney pelvis size in antero-posterior diameter is normally less than 4mm in second trimester and less than 7 mm in third trimester. Hydronephrosis is diagnosed if the anteroposterior diameter is more than 4mm in second trimester and more than 7 mm in the trimester. Hydronephrosis is graded as mild /moderate /severe depending on the diameter.

If hydronephrosis is detected, repeat antenatal scan is done at 16-20 weeks. This scan sees hydronephrosis measurements and also sees –any lower urinary tract obstruction/ renal dysplasia/ extra-renal structural anomalies. if hydronephrosis is unilateral – one more scan is done in third trimester. If it is bilateral hydronephrosis, antenatal scan is done every 4 weeks.

## ▶ Post Natal Follow Up

Early detection of infants with significant disease allows initiation of interventional therapy that may minimize the adverse effects on the kidney. Post-natal evaluation includes clinical examination and the use of imaging studies to detect abnormalities that will require postnatal management. Overall 3 tests are done after birth, to assess the hydronephrosis. They are Renal ultrasound, Diuretic radioisotope renography and Micturating cystourethrogram

Once the baby is born, all patients with antenatal detection of hydronephrosis should undergo ultrasound scan after 3 days and within 7 days. Renal ultrasound is the preferred imaging study for evaluation of hydronephrosis. This baby's scan will give an idea whether the hydronephrosis is persisting or resolved ante-natally. Ultrasound can detect most of the congenital anomalies of the kidney with good accuracy and without risk of radiation. Before 3 days (within 48 hours), urgent ultrasound should be done in cases with bilateral hydronephrosis and hydronephrosis in a single kidney.

If the hydronephrosis is persisting, the intensity of further evaluation depends on the diameter of kidney pelvis on ultrasound (APD) and Society for foetal urology grading (SFU). The hydronephrosis is graded from zero to four. Zero indicates no hydronephrosis and grade 4 indicates severe hydronephrosis. Repeat scan is done at 6 weeks of age of the baby. If diameter of renal pelvis is more than 10mm and SFU grading 3-4, they need further evaluation to rule out upper urinary tract / lower urinary tract obstruction or vesicoureteric reflux (urine going in a reverse direction from below up).

Mild hydronephrosis if it is less than 10mm, needs to be followed up with repeat ultrasound after 4-6 weeks and after 4-6 months. No antibiotic prophylaxis is given.

Diuretic renography if there is increase in pelvic diameter on follow up scans. Usually they regress by 18 months of age. Moderate hydronephrosis if the renal pelvic diameter is between 10-15mm. no antibiotic prophylaxis is needed. needs to be followed up with repeat ultrasound after 4-6 weeks and after 4-6 months.. Diuretic renography if there is increase in pelvic diameter on follow up scans. Usually they regress by 18 months of age. Severe hydronephrosis : if renal pelvic diameter is more than 15 mm. these severe cases need further evaluation by renal radioisotope study (DTPA / EC scan) and if indicated Micturating cystourethrogram (MCUG)

## ▶ Diuretic Renography

(renal radio-isotope scan with administration of diuretic) is used to diagnose / rule out urinary tract obstruction and also to assess kidney function. It is usually done between 4-6 weeks of life. It measures how the kidneys are taking the radioisotope dye from blood, how it is transiting through the kidney, the drainage time from renal pelvis and to assess the relative function of each kidney to the overall renal function. This test requires intravenous access for administration of fluids, radio-isotope and diuretic. Bladder catheter has to be introduced. The preferred radio-isotope is technetium 99m tagged with DTPA or EC isotope. The wash time of dye after diuretic injection is less than 15 minutes it is normal and non-obstructed. If the washout time is 15 -20mts it is indeterminate and more than 20 minutes washout time indicates obstructed kidney and needs surgery.

## ▶ Voiding Cystourethrogram

a voiding cystourethrogram is not done in all cases with hydronephrosis, it is done in only selected cases with persistent hydronephrosis to detect bladder outlet obstruction and to rule out vesico-ureteric reflux. It is usually done between 4-6 weeks of life. For this

procedure, a urinary catheter is inserted in to the bladder and contrast material is instilled. X-ray films are taken while filling and also during voiding of urine. Children tolerate this procedure well. This procedure gives important information about bladder size, shape, bladder neck ureters and urethra. This is done mainly to rule out urethral obstruction (posterior urethral valves) and ureteral incompetence (vesico-ureteric reflux).

if there is a normal post-natal ultrasound scan or mild hydronephrosis, with normal ureter and normal bladder, the babies should undergo ultrasound after 3 days and second ultrasound after 6 weeks. third ultrasound after 4-6 months. If the scan findings show regression or static, next ultrasound is done at 1yr and 18 months of age. If it is normal no further follow is needed.

## ▶ Surgical Management

Surgery is indicated when there is significant renal pelvic dilatation or increasing renal pelvic diameter on follow up scans, obstructed picture in renogram (renal diuretic radio-isotope study) and obstructed picture with split renal function (SRF) below 40%. Surgery is indicated even if there is further fall in split renal function on serial follow up scans. So, ultrasound findings of pelvic size & drainage pattern and split renal function on DTPA/EC renal radioisotope study are crucial for taking decision on need for surgery.

The surgical procedure is called Anderson-hynes pyeloplasty. it can be done either by open/ laparoscopic method. The advantage of laparoscopy is it is scarless, less hospital stay and magnified vision for surgeon during the procedure. Laparoscopic pyeloplasty is done under general anaesthesia. It takes around 2- 3 hours for the surgical procedure. The endoscopic surgery is performed through three small incisions made on the abdomen through which three endoscopic instruments

(one 5mm and two 3mm) are introduced for performing surgery. In this procedure, the obstructed pelvi-ureteric junction is removed and a new, wide, funnel shaped and dependent pelvi-ureteric junction is created. Excessively enlarged renal pelvis is trimmed. Water tight anastomosis is done between pelvis and ureter. after the procedure, 3-4 french size stent is placed across the anastomosis. The stent carries the urine from the pelvis to the bladder, gives rest to the anastomosis and allows the anastomosis to heal without stenosis.

The results after pyeloplasty procedure are generally good. it allows the urine to flow down across the pelvi-ureteric junction without obstruction. this will relieve the pressure in renal pelvis and back pressure on renal cortex. The improvement in renal function and decrease in renal calyceal dilatation may take time.

## ▶ Post Surgical Follow Up

These patients are given a low dose antibiotic at bedtime daily for 3 months. The double J stent kept across the anastomosis is removed after 4 weeks. This needs a short anaesthesia and cystoscopy. It is done as an out patient procedure. These patients are followed up with ultrasound regularly. First ultrasound is done after 3 months after surgery. Ultrasound will show the anatomical improvement in kidney like reduction in renal pelvic size. The other anatomical factors like cortical thickness improvement will take time. After 6 months functional study by Diuretic renogram is done. This will show the relief of obstruction at pelvi-ureteric area. The dye will pass across the newly created pelvi-ureteric junction without stasis (satisfactory drainage). After these initial studies and after documenting the flow across pelvi-ureteric junction yearly ultrasound was done for 5 years.



## ▶ Long Term Follow Up Results

The babies with hydronephrosis who are either operated by pyeloplasty surgery or followed up conservatively should be followed up for a minimum period of 3 years. The longterm results following pyeloplasty is excellent in various studies.

## ▶ When Kidney Has to be Removed

Kidney is very rarely removed in hydronephrosis due to pelvi-ureteric junction obstruction. Even when the renal function is low and poor, a trial procedure like percutaneous nephrostomy / double J stent placement is done. A waiting period of 4 weeks is given. Again functional study is done after 4-6 weeks. If the function is improved a "trial" pyeloplasty is done. If the function is not improved and if it is the causing recurrent UTI, it has to be removed. This situation arises very rarely in hydronephrosis in children.

The kidney is removed when the hydronephrosis is associated with dysplastic kidney like multicystic dysplastic kidney. As a dictum – in children, hydronephrotic kidney is rarely removed.

### Key Points :

Do not get panic with ante-natal scan report of foetal hydronephrosis.

Foetal kidney swelling (hydronephrosis) is a common finding in ante natal checkups.

No need to get panic. Not all cases need surgery. Not all cases will cause renal damage.

Outcome depends on etiology (what causes the renal swelling).

Only in one third of the cases(30%), it will need a detailed follow up and surgical correction.

Hydronephrosis is a correctable anomaly, most of the babies(kidney function) will do well, after surgery with relief of urinary flow obstruction.

Termination of pregnancy is not recommended in fetuses with unilateral / bilateral hydronephrosis.

Early delivery is not indicated.

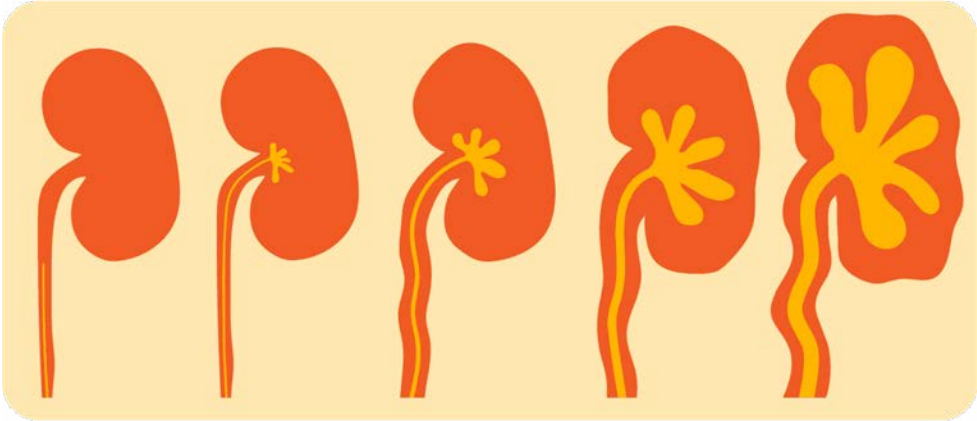
Kidney is rarely removed in hydronephrosis in children



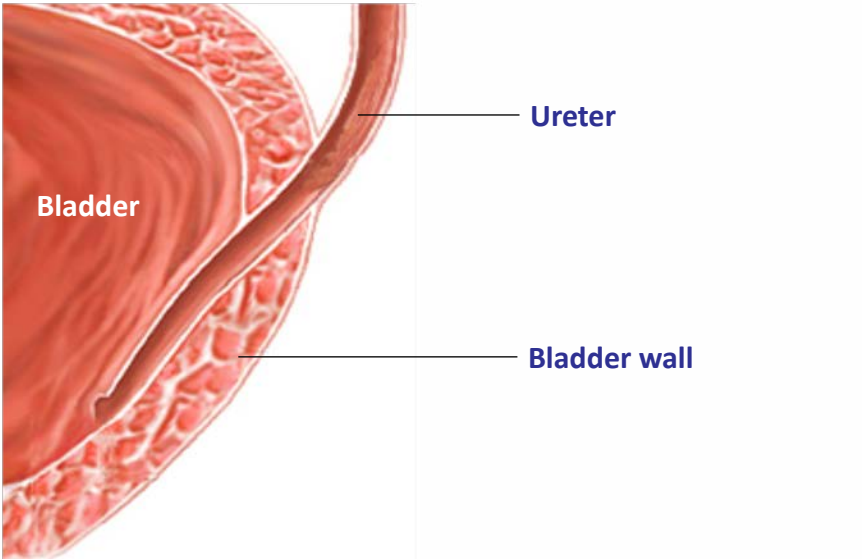


**IF URINE GOES UP IN CHILDREN**

### Urinary Reflux Up Into Kidney - Its Grades of Severity

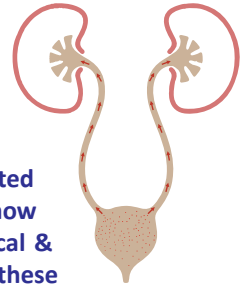


### Normal Ureteric Entry Into Bladder





## IF URINE GOES UP IN CHILDREN (VESICO-URETRIC REFLUX)



Urinary infections are common in children particularly in girls between the age of 1 -5 years. The usual tendency of the parents is, to take the child to a pediatrician, get the infection treated and forget about it, once the infection is under control. This is not a correct and right approach. Once there is a documented urinary tract infection, the entire urinary tract should be evaluated, to know the root cause of urinary tract infection. This is because sometimes anatomical & functional abnormalities in urinary tract can lead to infections in children. If these anomalies are not detected and corrected in time, they can lead to recurrent urinary tract infections and kidney damage. One such problem leading to recurrent UTI in children is Vesicoureteric reflux. VUR is a condition in which the urine flows back from bladder into one or both ureters and sometimes into the kidney. This condition may get corrected by itself, or should be treated with medication or it should be corrected surgically otherwise it will lead to kidney damage in the long run. This condition needs public awareness and early detection.

### ▶ What is the problem? How common is it ?

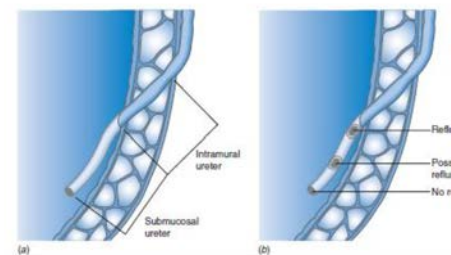
Kidneys are located in the loin area on each side. The urine formed in the kidneys will flow down in boluses into the bladder from each side. Whenever the bladder is filled and when the place is convenient, the bladder contracts and empties the urine through a tube called urethra. This is the normal way of urinary flow. It should be always in one-way direction from above -downwards. But in some children as an unusual way the urine goes up into one or two ureters, sometimes into the kidney itself. This condition is called – Vesico-ureteric reflux (VUR). 30% of children with urinary tract infection, when evaluated, will be found to have VUR. VUR leads to stasis of urine as urine always moves up and down in the urinary pathway, leading to recurrent urinary infections. The upper urinary tract, i.e. kidney, is always at risk due to this VUR. That is why this condition should not be neglected.

The ureter enters the bladder wall at an angle, runs through the bladder muscle, then it runs in a tunnel under the mucosa (layer covering the bladder cavity). This tunnel length

(submucosal tunnel length) is very important in maintaining the one-way travel of urine. When the bladder is filled and expanded, the ureter in the submucosal tunnel is compressed and closed against the bladder wall muscle. In vesicoureteric reflux cases, there is short or no submucosal tunnel. In such a situation when the bladder is filled with urine, the ureter is not compressed efficiently and urine will reflux into the ureter during micturition.

### ▶ When we have to suspect vesico-ureteric reflux ?

- Any child with one attack of documented urinary tract infection should be evaluated for Vesicoureteric reflux.
- If there is swelling in the kidneys detected antenatally (Hydronephrosis) -postnatally such babies should be evaluated.
- If there is any cystic changes in one kidney, such babies should be evaluated to rule out VUR in the other kidney.



- If one child is born with VUR, other siblings should be evaluated for VUR

After controlling the urinary tract infection, after a gap of 3 weeks an ultrasound and micturating cystourethrogram (MCUG) is done to rule out vesicoureteric reflux. All antenatally detected swellings in the kidney (Hydronephrosis) should be evaluated after birth to rule out VUR. If one child is having VUR, the other children should be evaluated even if they are without any urinary symptoms. Because “silent Reflux” may be present in them.

### ▶ Kidney injury

Vesicoureteric reflux results in reverse flow of urine in to ureters or in to kidneys. With each reflux the bacteria are carried from lower urinary tract in to kidneys. This will lead to infection of the kidneys (Pyelonephritis). Each Pyelonephritis attack will lead to scar formation in the kidneys. This scar formation in the long run will lead to contraction of the kidneys. This will lead to loss of kidney function and development of hypertension (Renal Hypertension). If the Vesicoureteric reflux is bilateral, or if the treatment is not initiated in time the renal damage will start early.

### ▶ How to detect / confirm Vesicoureteric Reflux ?

Even with a single documented urinary tract infection, the entire urinary tract should be evaluated. After controlling the infection,

all these children should be subjected to ultrasound abdomen test. Ultrasound is a simple low cost non-invasive test without any radiation risk. It can be done any number of times. In this test the anatomical status of the kidney, ureter and bladder can be assessed. Any dilatation anywhere in the urinary tract can be detected with accuracy in U/S examination. If there is a suspicion of VUR, the next investigation is Micturating urethrogram (MCUG). In this a dye is injected in to the bladder and films are taken in different views, when the child is voiding the urine. If there is a reflux of dye up in to the ureters the diagnosis of VUR is confirmed and its severity is graded. There are 5 grades of severity of VUR based on upto what level the urine is refluxing . Urinary reflux can be on one side or in to both kidneys.

Once it is confirmed and severity graded, next step is to know the damage already done by VUR on kidney. This is detected by a functional study called DMSA radionuclide renal isotope scan. In this scan, the radiopharmaceutical material is injected through intravenous injection. This is exclusively taken up by the kidneys and it will show the function of each kidney and the existing scars due to repeated urinary infections . By this study the severity of VUR & the degree of renal damage can be assessed.

### ▶ How to know the severity of Vesicoureteric reflux ?

The severity of the VUR can be assessed by MCUG and DMSA renal isotope study. If there is gross dilatation of renal pelvis and ureter in its entire length, if there is higher grades ( grade III and IV) in MCUG test, if there are scars and contracted kidney, if the VUR is bilateral it is considered as severe and a word of caution is given to parents regarding lonterm follow up.

## ▶ How it we be corrected?

The main aim of treatment in VUR is to protect the upper tracts ( Kidneys). If we see that there are no bacteria in the bladder urine and urine is sterile, even if the urine is refluxed it wont cause much damage to the kidneys. So the first line of treatment for Vesicoureteric reflux is giving prophylactic antibiotics after controlling the acute infection with medication. The prophylactics antibiotics are given in the dose 1/3 of the dose routinely given as to treat infection( theurapeutic dose). It is given at bedtime to get maximum concentration of drug in the urine. In less than 6 months age infants the drug is given in 2 divided doses and above 6 months it is given as a single dose at bedtime. This should be continued till the VUR is resolved.

If there is high grade reflux ( grade V or VI), if the VUR persists beyond 5 years of age, if the medical management is failed or if there are breakthrough infections inspite of antibiotic use,if there is development of renal scars due to VUR, or if the split renal function is falling the vesicoureteric reflux should be corrected by surgery. The surgery is called -Ureteric reimplantation . In surgery the ureter is disconnected from bladder and rerouted in such a way that there will be sufficient submucosal tunnel length. This can be done by opening the bladder or by vesicoscopic method. The results of surgery is usually good. The vesicoureteric reflux can also be corrected by deflux injection method. In this procedure called STING the chemical is injected at one or two places in the ureteric orifice in the bladder. This will raise the ureteric orifice and prevent the reflux.

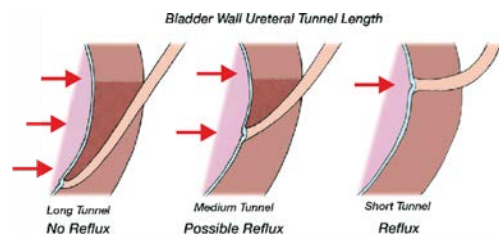
## ▶ Longterm affects and follow up

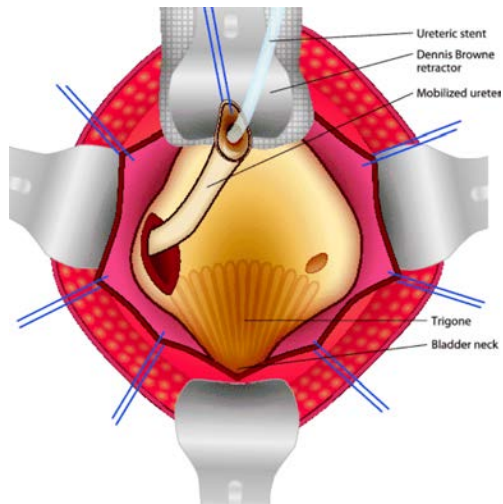
Children with vesicoureteric reflux, should be under medical care till 15-20 years of age. Wheather the VUR has resolved spontaneously,or it is corrected by surgery, every year medical checkup should be done. At visit, the doctors will check the general growth of the child, renal growth and renal function .

## ▶ Precautions to be taken by parent

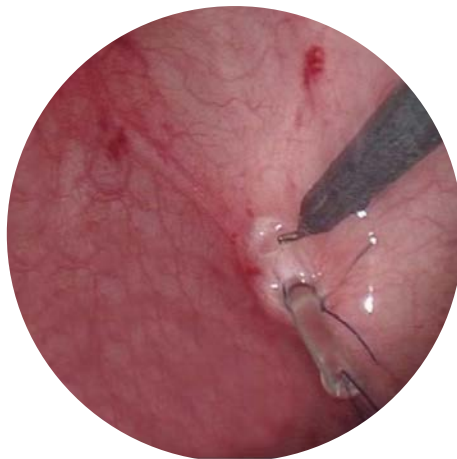The following precautions has to be taken by the parents when their child is suffering with Vesicoureteric reflux.

- Daily the prophylactic medicines has to be taken without fail.
- Encourage the child to take plenty of liquids
- Encourage the child to empty bladder once in 3hours in grown up children
- Take measures to avoid constipation in the child
- Encourage the child to take plenty of fruits and vegetables
- Maintain a break through infection record and enter when ever there is a fever, wheather it is due to respiratory tract or due to UTI.





**Open Ureteric Reimplantation**

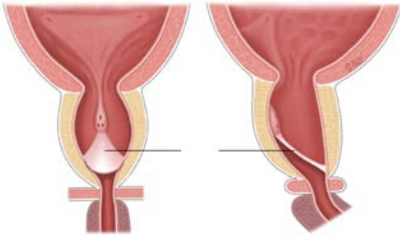


**Laparoscopic Ureteric Reimplantation**

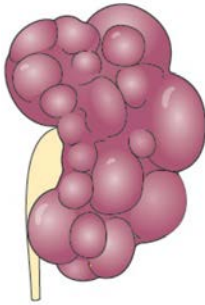




## URINARY TRACT INFECTIONS IN CHILDREN



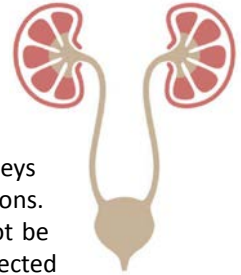
**Posterior Urethral Valves**



**Multi Cystic Dysplastic Kidney**



## URINARY TRACT INFECTIONS IN CHILDREN



Health problems in children .if we neglect them in early stage, they will lead to longterm medical issues. They may trouble through out lifetime. Urinary infections in children will be the true example of such a situation. They may bring unseen and silent damage to the kidneys. From anatomical abnormalities in kidneys to unhygienic practices,many things can cause recurrent urinary tract infections. If the children complains of pain & burning sensation in the urine, it should not be neglected. It may be a sign & symptom of UTI in children.They should be detected early . the story does not end there, the causative factor for UTI should be identified and corrected,otherwise in longterm it will lead to renal damage. Each infection will lead to development of scars in the kidney, which later leads to kidney contracture, renal hypertension, proteinuria and renal failure.

### ▶ **Body protective mechanisms against development of UTI ...**

For development of infections urine is a good culture medium. But urine infections doesnot develop in all. There is an affective defence mechanisms in the body which prevents UTI development. For infection to develop, urinary stasis is needed. But as most of us will empty bladder frequently the risk is eliminated.but if urine stays for 6-12 hours it will get infected. The protective mucus secretion by the bladder mucosa, the antibacterial properties of the urine will also give protection.

### ▶ **The bacteria comes from .....**

The kidney filters the blood, separates the waste products from blood and forms the urine. Because of this function of the kidneys,our body will get rid of waste products. In normal situation no bacteria will be found in urine.then from where the bacteria are entering the urine. It is from the gut. The Bacteria causing urinary infections will come out from anus,passes through the perineum and stays on the perineal skin. This will enter the urinary tract through urethra and proliferate there in bladder urine. Normally when we pass urine frequently

(once in 3hours atleast) these bacteria have no time to proliferate and gets flushed away. If by any reason, there is stasis of urine in the urinary tract, it will give time and place for bacteria to proliferate and produce infection. In Neonates the UTI may be secondary to systemic infection spreading through blood.

### ▶ **More common in girls**

The commonest infections in children are respiratory and are due to virus infection. The second commonest infections are due to bacteria and they affect urinary tract. Urinary tract infections are 3 times are more common in girls. The reason for this is due to short length of female urethra. By the time the children reach 12 years of age, it is 4 times more common in girls. Depending on the extent of urinary tract involvement, UTI are considered as two types. Lower urinary tract infection- when the infection is confined to urethra and bladder. It usually presents with bladder irritability symptoms like – frequency & urgency of urine, dribbling of urine, passing urine in drops with pain and lower abdominal pain. Upper urinary tract infection – when the infection spreads to kidney,it presents with fever with chills and rigors, and loin area pain. Upper UTI is more dangerous than lower UTI as the kidneys got involved.

## ▶ What are UTI symptoms

In case of children below 2 years of age...the symptoms are non-specific .symptoms are vague and not linked to the urinary system.

- Unexplained high grade fever
- Diaper urine smells bad
- Loose stools and doesnot look healthy.
- Persistent vomitings
- Sudden loss of weight
- Irritability and crying while passing urine

In case of above 2 years of age, specific symptoms told by the child will be helpful...

- Difficulty in passing urine with pain and burning sensation.
- Bad Smell in urine
- Frequency of urine
- Pain in lower abdomen
- Fever & vomitings.

there are two types of UTI. Bladder infection and kidney infection .in bladder infection, there will be swelling and pain in the bladder it is called -cystitis.it will presents with frequency and urgency of urine associated with pain while passing urine. If the infection spreads to kidney it is called pyelonephritis. it will present with fever,chills and rigors. Kidney infection is more dangerous than bladder infection.

## ▶ How to detect

Urinary tract infections are detected by urine analysis and urine culture & sensitivity. Collection of urine for these two tests is very important, otherwise erroneous reports will occur. Midstream, clean catch urine should be collected. The beginning and ending of the urinary stream should be left and only midstream of urine should be collected. It should be collected in a sterile container. In

small kids collection of urine is a challenge as they pass urine without notice. The best way of collecting urine in small kids is direct aspiration of urine from bladder.the common bacteria causing UTI are E.coli, Klebsiella, Proteus and Pseudomonas . 85-95% of UTI are due to this infection. 5-10% cases UTI is due to streptococcus and staphylococcus.

After confirming and controlling the infection, ultrasound examination and MCUG test should be done to find out the cause for the urinary infection. In ultrasound the normal anatomy/ any anatomical abnormalities of the kidney will be evaluated. MCUG test will detect the any evidence of vesicoureteric reflux .in this test,a small tube is introduced in to the bladder and filled with a dye. When child is passing urine films are taken to see for any VUR.if there is any evidence of VUR, renal radioisotope study called DMSA scan is done to know the size & shape of kidney, kidney function, and scars in the kidney.

## ▶ Problems with UTI

Urinary infections in children are more dangerous than adults. This is because, the kidneys are in developing stage. They develop till 8years of age. If they get damaged at this stage, lifelong affects will be there.that is why the UTI in children should be detected early, the causative factor for infection should be find out and infection should be treated aggressively. No amount of slackness or negligence is acceptable in this regard. If the UTI are recurrent, it will lead to

- **Reflux nephropathy** : if UTI is due to vesicoureteric reflux and if it is not detected in time, it will lead to renal scarring and later the kidney will become contracted. That means one kidney is normal size and other kidney is contracted.
- **Renal hypertension** : common in cases with infection in both kidneys and

sometimes even in infections in one kidney can lead to renal hypertension due to changes in blood flow in the kidney. Due to hypertension, heart failure, paralysis or blood vessel damage in eyes can occur.

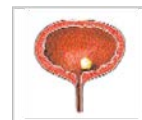- **Proteinuria** : proteins are normally retained in the body . if kidney cells are damaged, proteins will be filtered and lost in urine .this can lead to hypoproteinemia and swelling of the body.
- **Renal contracture and small kidney** : with each scarring in the kidney due to infection, the kidney size will be reduced. This will severely affect the split renal function later.
- **Renal failure** : this is the end result of recurrent urinary tract infections particularly when they are neglected.

## ► Reasons for UTI in children

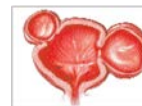For UTI in children there are 3 reasons - congenital defects in the anatomy of the urinary tract, urine refluxing back up in to the kidneys ( vesicoureteric reflux) and habit of holding urine and stools for a longer periods ( Dyselimination syndrome).

- **Congenital anomalies in the anatomy of urinary tract** : **Phimosis** : in some children, the skin at the tip of the penis is not opened properly. This will lead to collection of dead skin cells under the skin (smegma collection ) which can lead to infections ( Balanoposthitis). This condition is usually treated successfully with steroid ointments but if it doesnot respond it is corrected by a minor surgical procedure called -circumcission.
- **Posterior urethral valves** : some male newborn are born with a membranous obstruction in the posterior part of the urethra. These membranes will cause

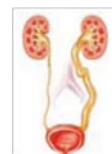obstruction to the outflow of urine and cause urinary stasis leading to UTI. The bladder will get thickened due to obstruction. Urine may flow back in to kidneys. This condition is corrected by cystoscopic procedure called - fulguration of valves.



- **Bladder diverticulum** : some children are born with an additional pouch attached to bladder called diverticulum. This can develop even after birth also. This pouch gets filled with urine but doesnot empty freely leading to stasis of urine .this will cause repeated UTI. Surgical removal of the diverticulum is the treatment of choice.

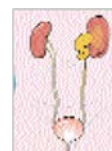

- **Obstructive megaureter** : there will be narrowing and obstruction at the place where the ureter enters the bladder wall leading to proximal dilatation & stasis of urine leading to repeated UTI. This will be corrected by disconnecting the ureter and doing uretric reimplantation so that urine will flow freely without obstruction.



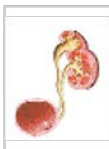- **Hydronephrosis** : in this condition, there is obstruction at the junction urine collecting bag attached to kidney ( pelvis) and urine draing tube ( ureter) pelvi-ureteric junction leading to stasis of urine. This causes pressure atrophy of kidney and UTI. This condition is relieved by a surgical procedure called pyeloplasty where the pelvi-ureteric junction is removed and a new, wide funnel shaped junction is created.

- **Duplex moieties** : in this condition, there will be additional renal units instead of single kidney on each side. Each unit will have their own pelvis and ureter. These



units may not be located normally, may not join the bladder normally, may not function normally. They may be a source of recurrent UTI. These additional units are corrected by surgical removal if they are the source of recurrent UTI

- Multicystic dysplastic kidney (MCDK):** in this condition, one side kidney will be normal and the other side kidney will not develop (dysplastic) and it will be replaced by a bunch of grape-like cysts. These cystic units are not connected to the ureter. They may become a source of recurrent UTI.



- Reflux of urine back in to the kidney (vesicoureteric reflux):** normally urine should flow down in one way direction from kidney to bladder and out. In some children, when the bladder is contracting to empty the urine, some urine will flow up in to the kidney- this is called vesicoureteric reflux. This is mainly due to weakness at the junction of ureter in to bladder. Based on its severity the VUR is graded into five grades. Grade 1,2 &3 usually will regress with age but grades 4 & 5 may need surgical correction called - ureteric reimplantation.

- Dyselimination syndrome:** children withhold urine when they are busy watching TV, or while playing in the playfield or if the toilets in the school are not clean. This will lead to chronic stasis of urine and they lose the sensation we get when the bladder is full. This will lead to recurrent UTI. After some time they will withhold the motion also (Dyselimination syndrome). It will be treated with reassurance of child, aggressive management of constipation, and toilet training.



- Other causes:** urinary tract stones, passage of calcium through urine (Hypercalciuria), spinal defects, neurogenic bladder will be the cause of recurrent UTI.

## ▶ How UTI is treated

Urinary tract infections in children, once they are documented should be treated with empirical antibiotics till the urine culture & sensitivity report comes. Once the urine C/S report comes antibiotics are changed according to culture report. Antibiotics are given usually for 2 weeks .one week intravenous and second week oral medication. Once the UTI is under control the child should undergo ultrasound abdomen, Micturating cystourethrogram (MCUG) and DMSA depending on the MCUG finding. if the UTI is secondary to any surgical condition it should be corrected by surgery .

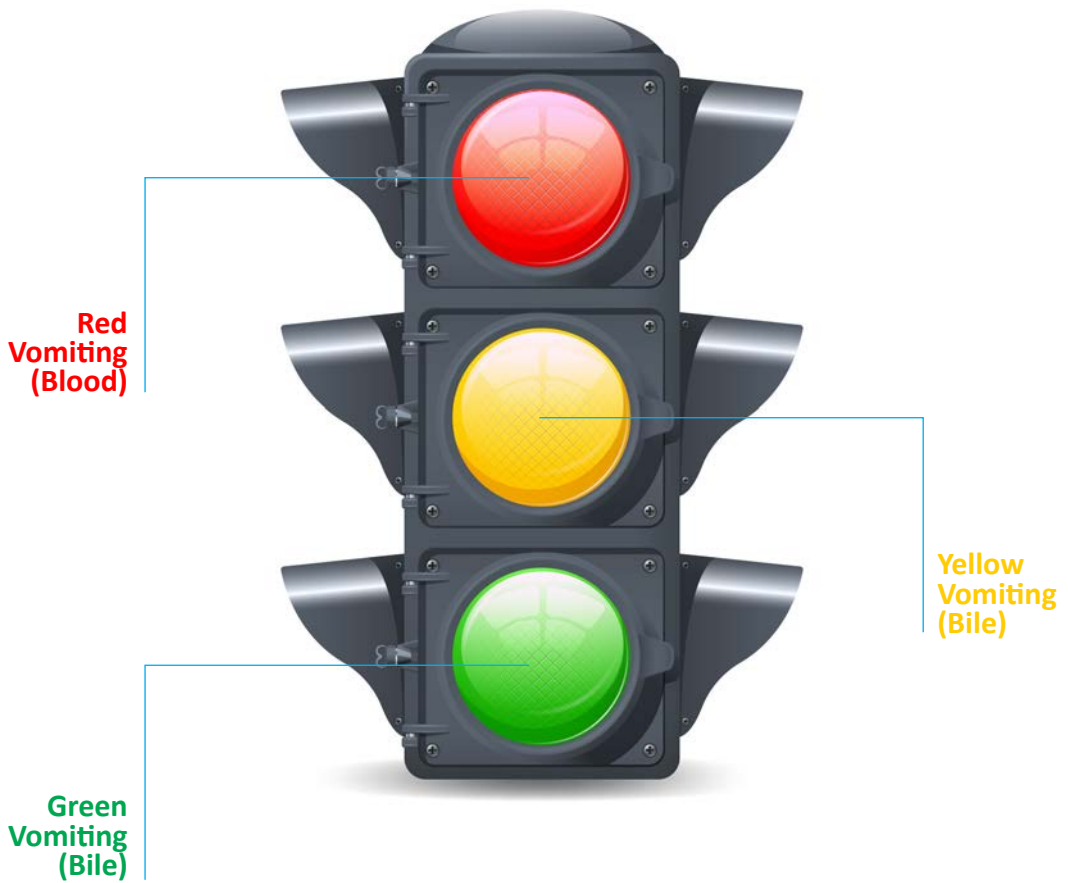
## ▶ Precautions to be taken by the parents

- Children above 3 years of age ( toilet trained) should empty their bladder once in 3 hours. This should be followed even in school time.
- Children should be encouraged to take plenty of liquids
- Children should be encouraged to take more vegetables and fruits
- Daily cleaning of genitalia and perineum of children is very important. In males the tip of the penis should be cleaned regularly.
- In females the perineal washing should be done in a backward swipe. The cleaned water should not come to front and cause UTI as the female urethra is very short.
- When ever UTI is suspected in children, doctor should be consulted immediately.



## VOMITINGS IN CHILDREN

## Dangerous Vomiting





If the child is taking food properly and tummy is full the parents happiness will not have any boundaries. This is the scene we all see whether the child is a small baby taking mothers feed, infant taking semisolid food or it is in the case of children taking solid food. if the childs stomach is full the parents feel as if their tummy is full. But parents are panicked when their baby is vomiting all the milk consumed or vomiting out all the food which was taken.



Most of the times, the reason for vomitings in children is simple and they are not dangerous. Faulty feeding technique, gastrointestinal infection and intake of unhygienic food will lead to vomitings in children in majority of the situations. But even in rare situations, vomitings may be a sign of dangerous disease that is why it is always better to have a knowledge on when we have to take vomiting seriously.

### ▶ How vomiting occurs

In simple words, vomiting is a protective mechanism. Ingestion of contaminated food, drinking of contaminated water, entry of bacteria or viruses in to the gastrointestinal tract even without our knowledge can lead to infections of GIT. Such foreign bodies will be thrown out of the body in the form of vomiting. In children most of the vomitings are due to this reason only. They are not dangerous. Taking anti-emetics and ORS will relieve the vomitings in one to two days. sometimes vomitings recur after getting controlled or they may be persistent without relief. They cause lot of discomfort to the children and anxiety to the parents. Such type of vomitings needs to be taken seriously.

All of us have a vomiting center in the brain called – chemical trigger zone. it is in the area below the fourth ventricle in the brain. The allergic and irritant signals from various parts of the body will go and stimulate this chemical

trigger zone. The nerves in the CTZ will get excited and send signals below to facilitate vomiting. These signals will forcefully contract the abdominal muscles,

### ▶ Types of vomitings

**Persistent vomitings** : vomitings occasionally in children is common. Sometimes vomitings will not get relieved over a significant period, or if they relieved for a short time only to be recurred again, such vomitings are called persistent vomitings. These type of vomitings will lead to weight loss and dehydration.

**Projectile vomitings** : regurgitation of feeds are common in neonates. They are not projectile and they just slip over mothers shoulders. But when ever there is an organic cause, like intestinal obstruction, the vomitings will be projectile and forceful. They will fall a distance away. These vomitings are significant and needs evaluation.

**Bilious vomitings** : The digestive juices produced from the liver (Bile), will enter the gastrointestinal tract at the level of Duodenum. If there is any obstruction below this level, the vomitus contains greenish or yellowish bile. The fresh bile is golden yellow in colour and if it stays for a period due to obstruction it will turn to dark green. These type of bilious vomitings needs to be evaluated. If the obstruction is proximal to the entry of bile in to the intestines, the vomitus is non-bilious.

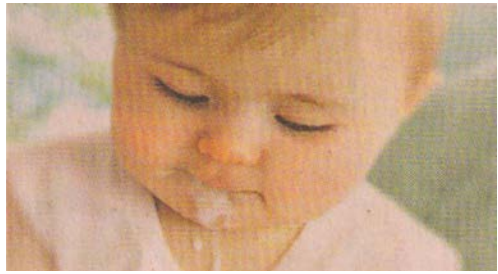**Blood mixed vomitings** : in newborns, sometimes the blood in vomitus may be due to ingested maternal blood or blood from small fissures over mother's nipple. Sometimes they develop transiently due to immature clotting mechanism, which will be corrected by Vit K injection. These vomitings associated with blood are not dangerous. But if the vomitings contain significant and persistent blood, it may be a sign of gangrenous bowel. Sometimes bleeding may come from liver due to liver damage called cirrhosis or due to raise in pressure in blood vessels leading to liver (portal Hypertension). These vomitings should not be taken lightly and should be evaluated urgently.

**Feculent vomitings** : If there is obstruction in the lower part of the small intestine or in the large intestine, the faeculent material cannot progress further and will come in a reverse way up. The vomitings in such a situation will contain feculent material. This is a real emergency and needs to be tackled urgently by emergency surgery.

### ▶ **Age related causative factors**

There are many things that can lead to vomitings in children. Faulty feeding techniques, gastroesophageal reflux, gastrointestinal infections, intestinal obstruction, luminal obstructions in intestines can lead to vomitings. These lesions will depend on the age.

**Neonatal age** : faulty feeding technique is the main cause. Along with milk the neonates will ingest air. When the ingested air is coming out, it brings out the milk along with it. If the mother takes the baby on to the shoulders and does the burping properly, this regurgitation of feeds can be reduced. GIT infections, reflux of milk due to incompetent Gastroesophageal sphincter are the other causes for vomitings in neonates. Milk protein lactogen intolerance also can lead to vomitings. Introduction of Lactogen free milk will control the vomitings.



Infections in lungs, brain, or blood can lead to vomitings.

- All of us will have intestines placed in a particular pattern but in some children the intestines are in a different pattern called malrotation of midgut. This anomaly can lead to rotation of intestine leading to gangrene (volvulus). This is a surgical condition needing surgical correction at the earliest.
- Any obstruction to intestine can lead to bilious vomitings. Interruption in the development of the intestine (intestinal atresia), infection in the intestinal walls due to failure of immune system (necrotizing enterocolitis), absence of nerves in the walls of bowel (Hirschsprung disease) all these lesions will require immediate surgical intervention.
- Another common condition is thickening of the muscles in the wall of the bowel (congenital pyloric stenosis), this leads to progressive narrowing of the intestinal lumen leading to vomitings. In these neonates, after giving feeds a small visible mass moves from left to right. This condition can be corrected by a simple surgical condition called pyloromyotomy.

### ▶ **Age related causative factors**

**In Infants** : **GERD** – incompetence of the muscles holding the gastroesophageal junction will lead to reflux of acid juices up into the esophagus leading to damage. Mainly liquids will get refluxed. If it is mild – no specific treatment needed. Early initiation of

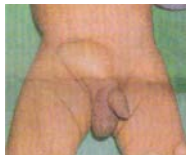solids, keeping the babies in head up position can correct the problem. When the problem is moderate, prokinetic drugs which leads to fast gastric emptying, anti-emetic drugs which stops the vomitings, feed solidifiers powders which makes the milk to turn into solids will help to relieve the problem. When the problem is severe, fundoplication surgery which strengthens the gastroesophageal junction will help to strengthen the junction.

**Intussusception** : in this condition one part of the bowel will get in to the segment which is distal to it. This presents with abdominal pain, greenish vomitings, and in later stages- blood in stools. This is an emergency needing an emergency exploration.

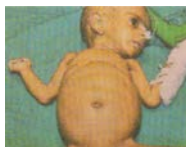**Obstructed inguinal hernia** : if the child is crying excessively with bilious vomiting it is better to examine the entire abdomen as it may be obstructed inguinal hernia. Usually in children, the inguinal (groin) hernia gets obstructed, sometimes umbilical hernia gets obstructed.



**Intestinal obstructions** : intestinal obstructions due to adhesions, congenital bands running across the intestines, luminal obstruction due to intestinal worms (Helminths) can lead to bilious vomitings and needs surgical correction.



**Raised pressure in the brain** : hematoma collection in the brain, infections in the brain can lead raised pressure and can lead to projectile vomitings.



**Deficiency of enzymes** : enzyme deficiencies like Galactosemia which is a metabolic condition can lead to vomitings

**Childhood age** : appendicitis is the main cause. this is more common between 5-8 years. in this condition -fever, pain abdomen and vomiting. If appendicitis is acute and severe it should be corrected by appendectomy.

Congenital bands, obstructed hernias and luminal obstructions can lead to vomitings in childhood age also. Diabetic ketoacidosis is the another reason in diabetic children which can produce vomitings.

## ▶ What happens when vomitings are neglected

If vomitings are neglected, it will lead to Dehydration (status of loss of water from body). This will be indicated by sunken eyes, dry tongue, extreme weakness, and low urine output. Electrolyte levels in blood will fall. It may lead to life risk, if it is not treated at this level. Persistent vomitings will lead to ulcers in the gastrointestinal tract and can produce bleeding in vomiting. In neonates and infants, the protective mechanisms are not very effective and some amount of vomited material may enter the lungs -leading to aspiration pneumonia. This may lead to respiratory distress and fall in oxygen levels. Along with vomiting, the acids in the stomach may get regurgitated up in to the upper gastrointestinal tracts leading to burning sensation in the chest, bitter taste in the mouth and loss of teeth enamel. If vomitings are persistent, it will lead to loss of weight. Rarely vomitings in preterm and low birth weight neonates can lead to sudden infant death syndrome in sleep

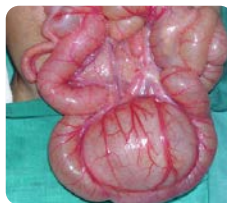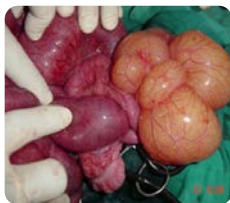## ▶ What the parents has to do?

When children are having vomitings, they get discomfort and are irritable. This is the time, the parents needs to give reassurance and support to the kids. In case of infants, the milk feedings should be continued in small quantities along with ORS and anti -emetic

medication. Only when the vomitings are severe, the feedings should be stopped and intravenous fluids should be started. In grown up children ORS (oral rehydration solution) should be the main management along with anti-emetic medication. If ORS is not available, little amount of salt and sugar added to water and should be taken frequently (Home made ORS)

## ▶ When we have to take vomitings seriously ?

- Persistent vomitings
- Vomitings associated with weight loss
- Forceful,projectile vomitings
- Greenish or yellowish vomitings
- Blood in vomitings
- Vomings associated with pain abdomen
- Vomitings followed by seizures (fits)
- Vomitings associated with dehydration
- Vomitings associated with abdominal distension.





## CONSTIPATION IN CHILDREN




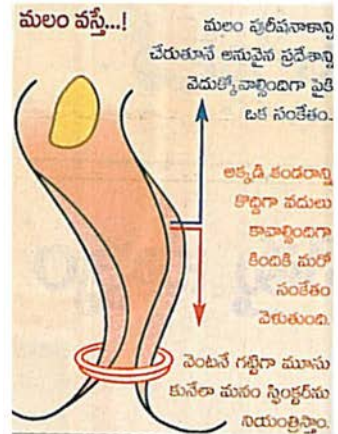
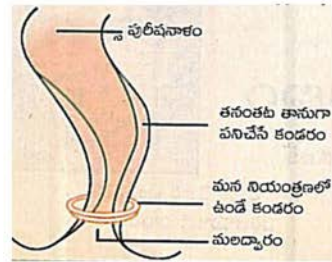
### ► Introduction

Mild degree of constipation is common in children. But if it recurs again and again or if it is persisting for a longer period it becomes a distress for the child and the family will go in to despair. In real words, the constipation is a cyclical condition, in which origin of one problem will leads to another. Because even a single day of not passing stools will lead to hard stools. Next day while passing the stools the children will pass stool with difficulty, discomfort and pain at the anal verge due to the development of ulcers ( anal fissures). This leads to postponement of going to the toilet. The postponement of stools will further aggravate the problem. So, it is always better to avoid the development of constipation in children. The parents should always have an awareness about the development of constipation in children, to avoid the distress and despair.

### ► Constipation

means passing hard stools with difficulty and or pain, less often than normal. Regular soiling of undergarments with liquid stool, may indicate that a child has constipation with blockage of stools ( impaction). Constipation has to be recognized early to prevent it from becoming a longterm problem. The following situations can be considered as constipation in children...

- Difficulty / Straining while passing stools
- Pain while passing stools with a tiny amount of blood
- Passing less than 3 proper complete stools per week.
- Stools that are hard, very large or small and pellet like
- Stool withholding. Child holds on to the stool trying to ignore the desire to empty the bowels.
- Not passing stools regularly with pain abdomen, tiredness and general malaise ,poor appetite, and restlessness ,avoidance of going to toilets.



## ▶ At what age it is common?

Constipation can develop at any age. Starting from newborn to adolescence anybody can get affected. In newborns, the neonates on top feeds are prone to develop constipation because mother's milk will be more suitable for bowel movement. In children aged 3-4 years, the constipation is secondary to faulty technique of toilet training. At this age, it is more common in boys than girls. Children less than 3 years can pass stools 4-5 times per day. It may be normal, even if they do not pass for 4-5 days but if they are accepting feeds well, if there is no abdominal distension, if there is no discomfort while passing stools and if there is no vomitings. If any of these are present then it will be considered as constipation. These symptoms will lead to loss of appetite and weight. Treatment should be started at this stage aggressively.

## ▶ How stool is formed?

The food we eat, will travel from the mouth to anus all along the gastrointestinal tract in a long journey. During its journey the food will be broken down and made into smaller particles to be absorbed into the blood vessels in the wall of the intestines. After all the particles which are useful to the body are absorbed into the blood vessels, the remaining waste material is the faecal matter. The large intestine (Colon) will move this waste material to the last part (Anal canal) to be expelled out. During its journey the body absorbs the water from the fecal matter, making it little solid. If we take food rich in fiber, it will lead to increase in stool volume and makes the stool more soft. If the child takes more milk, sweets and chocolates, the stool will become hard, due to the absence of fiber. If the intake of water is less, the large intestine will absorb more water from formed fecal matter leading to their hardness.

Once stool reaches the last part of the rectum, one signal goes up to the brain to locate the

convenient place and at the same time one more signal goes down to the sphincter muscle in the last part to hold the stool till the place is convenient. The intestinal movement is not under our control but the sphincter muscle is voluntary it is under our control. Once the place is convenient, the sphincter muscle relaxes and stool is passed. The differences in the passage of these signals and the reaction of sphincter to that will lead to the development of constipation in children.

In newborns it is slightly different. Once their stomach is filled, the bowel empties automatically. This is a reflex mechanism. Newborns pass about 8-10 stools per day. As the age advances mother can notice the facial changes when the baby wants to pass the stool. Later, the parents take them to the convenient place and make them to pass the stool. This is how they get the toilet training.

## ▶ How constipation begins?

If children do not take sufficient water, stools will become hard and small pellets like. This will lead to delay in sending signals to the brain regarding the need for passing stools. While passing these hard stools, small & multiple tears occur in the last part of the gut called anal verge these tears are called Anal Fissures. This is a sensitive area and it leads to pain during passing hard stools because of these fissures. This painful sensation will lead to postponement of passing stools. This leads to stasis of stools. When the stools stay for a longer time, the water in the stools gets absorbed leading to hard stools. This is a cycle in which one leads to the other. This will lead to a feeling that passing stools is a stressful sensation for them. The parents put pressure on the child when he is not passing stools regularly and when school attendance is affected. If the child is fussy and not responding, it will become a major issue in the house. Sometimes the absence of nerves in the wall of the intestine (Hirschsprung disease) will also lead to constipation.



## ▶ Conditions that can make a child constipated

- Low intake of fiber rich foods like vegetables and fruits
- Inadequate water intake
- At the time of toilet training and when the child starts going to school
- Due to medications, which the child is taking
- Unfamiliar surroundings like going in to public toilets
- When the baby starts taking solid food after weaning
- Improper sitting posture at the time of passing stools.

## ▶ What tests are needed to evaluate constipation?

If the constipation is mild and not causing much trouble, if the child's food intake is good and abdomen is soft, no need for any special tests. But if constipation is present since birth, if it is associated with vomitings, if the child is not accepting feeds, if there is abdominal

distension, and if the constipation is persistent – it needs to be evaluated. The usual evaluation is plain X-ray abdomen, which may show fecal matter loaded large intestine. The plain X-ray also helps in following those children who are treated with regular enemas, to see how much loaded colon got relieved of fecal matter with enemas. Later Barium enema test is done to rule out a condition called Hirschsprung's disease. Hirschsprung's disease is a condition, where intestinal wall develops without nerves. This causes functional obstruction in the movement of the intestine leading to constipation. In Barium enema, a small tube is introduced into rectum and dye is injected and films are taken. This test will confirm or rule out Hirschsprung's disease. In selected cases another test called -Anorectal manometry is done. This test will detect the intact nerves in the gut wall. This will measure the pressures in the rectum and anal canal. If nerves are present, once rectum is filled, the pressure in the anal canal will fall. This is called rectoanal inhibitory reflex (RAIR). It is intact in normal persons and absent in Hirschsprung's diseased children. If still doubts persist and constipation is severe, then a small bit of rectal wall is taken for Biopsy to see for the presence of nerves (Rectal Biopsy).

## How to treat constipation in children ?

The constipation in children is treated with **3 methods** – 1. Fiber rich diet 2. Toilet Training & 3. Laxative medication.

**Diet management** : there are three F's in the diet plan for constipation.

**Fiber rich diet** : the main reason for constipation is lack of proper diet particularly the diet rich in fiber. The readily available fiber diet is green leafy vegetables. All vegetables can be

taken but fiber is more in bendi, beans, drumsticks, cabbage and cauliflower. These vegetables should be given regularly to children. Second F is **fluids**. Sufficient fluids should be given to children in the form of water, fruit juices, and soups. Third F is **fruits**. Fruits should be served two times a day. After lunch and after

dinner. A ripe banana per day should be given after dinner.

**Toilet training** : Toilet training has got an equal role in the management of constipation. Toilet training should be started around 3 years of age. They should be made to sit on toilet at a regular time. The child should not be forced or pressurized to pass the stool. Simply he is made to sit in toilet daily for 5-10 minutes. This will take away the painful experience and the fear complex ,the child has towards toilet. After 2-3 months when the child is used to the toilet, the positive cortical signals will move the large intestine. It has got a major role in the management of constipation. The main component of toilet training is

Single time, single person (either father or mother) and Single toilet. Child should not be forced to empty the bowel, otherwise it will have a negative effect.

**Laxatives medication** : laxatives are the drugs used to make the stool soft and make it to pass easily. There are various types of laxatives are available based on their mode of action. Bulking agents, lubricant agents, osmotic agents ,emollients and colonic stimulents.usually in children osmotic agents and emollients ( stool softners ) are used. These drugs are used under physician guidance . along with these meedications.. other methods of treatment like diet and toilet training should be continued.

### ▶ **Tips that may help in relieving constipation in children**

- Look at the child's diet menu & see that enough fiber rich diet is included in the diet.
- Encourage the child to be physically active ( daily body physical exercise 1 hour per day)
- Try to get the child in to a regular toilet habit
- Try to allow plenty of time so that they do not feel rushed.( let them get up early before school time)
- Give some reward / praise when ever he passes stool in a potty or toilet (with small treats). This will have a positive reinforcement.
- Parents not to make fuss in the house over toilet issue. Try to keep calm and solve the issues.

### ▶ **Is surgery needed ?**

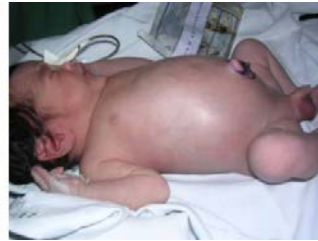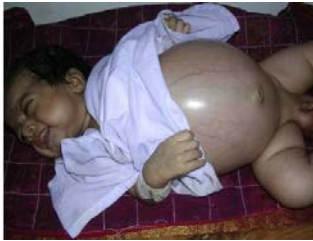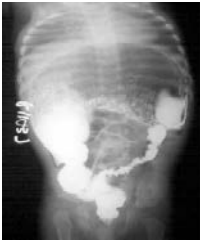Surgery is done when the cause of constipation is Hirschsprungs disease. In Hirschsprungs disease, a part of the intestine lacks nerves. In surgery, the segment lacking nerves is removed and segment containing nerves is brought up to the anal canal.This surgery is called -pull through surgery. In all other cases constipation is treated with medical management ,Toilet training and dietary advice. Pull through surgery is a major surgery can be done by open method or laparoscopic assisted method.

▶ **Important food material to eat in constipation children**

**Fiber rich diet** : Raw rice, pulses with peel, aloo with peel, fiber rich vegetables like beans, bendi, drumsticks ,cabbage and cauliflower, fiber rich fruits like ripe banana, grapes , dry grapes and apple. Plenty of water should be given to children. When fiber food is taken ,along with it more liquids should be taken.

▶ **Food to be avoided in constipation children**


Junk food like-chips, lays,and fried snacks should be avoided. More fat and sugar containing food should be avoided.







## RECURRENT ABDOMINAL PAIN IN CHILDREN



## 13

## RECURRENT ABDOMINAL PAIN IN CHILDREN

### Introduction

Abdominal pain is a common symptom in children affecting approximately 10% of school children and adolescents. 1 out of the 3 children is seen by a doctor for the abdominal pain complaint by the time they are 15 years. Abdominal pain is often frustrating and frightening for the parents. Many times it is hard to find the exact cause of the abdominal pain in children.

Abdominal pain is one of the most common painful gastro-intestinal problem in children. Children study during the examination period, after completing exams they play and enjoy a lot during vacation period and they do not complain of anything. After the playtime or during the time of food intake or at the hour of going to school – children start complaining of pain in the abdomen. This pain is repetitive and disturbing to the parents. Is this pain is real? or they are acting? How serious is this problem? When should we take this as serious problem? Is there anyway we can prevent such repeated attacks? These are the nagging questions in the minds of the parents. Recurrent abdominal pain is very common, very disruptive to the families and often not accompanied by easily definable organic pathology. It is a condition comprising of both organic and functional disorders and is therefore clinically challenging to diagnose and treat.

### ▶ What is Recurrent Abdominal Pain?

J. Apley a British pediatrician, studied extensively the abdominal pain pattern in 1000 school children in Bristol (England) and coined the following definition- Recurrent abdominal pain (RAP) is defined as - at least 3 separate episodes of abdominal pain, severe enough to affect their activities over a period longer than 3 months. These episodes are often severe, and the child is not able to do, his or her normal activities. It may affect up to 30% of children between the ages of 4 and 12.

Recurrent abdominal pain in children is of significance because:

- It is one of the most common symptoms in childhood worldwide.

- It is responsible for considerable morbidity, missed school days and high use of health resources.
- It is made up of functional disorders (those which cannot be explained by structural or biochemical disorders) and organic disorders. Apley -recorded that only 8%-10% of children with RAP had any organic pathology, after extensive investigation.
- Diagnostic uncertainty, chronicity and increasing parental anxiety often follow the unremitting course of the condition. This can make management of the child by the paediatricians very difficult, time-consuming and expensive.

Two situations can lead to Recurrent abdominal pain. One is organic and other

is functional. In organic type of pain some pathology or abnormality in the organ will lead to pain. In functional type the organ is normal without any pathology but there is change in the organ function . Gut is more sensitive to triggers that normally do not cause significant pain (such as stretching or gas bloating).

## ▶ Epidemiology

Studies have shown that the incidence of RAP is 10-12% of school children in developed countries. In asia also similar reports are noted. more in rural children than urban. More in girls than in boys.The diagnosis of RAP ,may differ in developing countries from western countries as infective causes are more common than inflammatory bowel disease.studies from india & Pakistan have shown that Giardiasis (helminthiasis) as major underlying condition of RAP.

## ▶ Clinical Profile

Most common is peri-umbilical pain associated with autonomic and functional symptoms like nausea,vomiting, limb pains, headache and pallor.

Symptoms of RAP are different for every child and may change with each episode. Generalized pain abdomen occurs over half or more of the abdomen, where as localized pain abdomen occurs in a specific area of abdomen.

- Sharp or dull pain.
- Severe pain that causes the child to look pale, become sweaty, or cry and bend over in pain.
- Pain that lasts a few minutes or hours.
- Pain in the belly button area or anywhere in the belly.
- Pain that may or may not be related to eating.

- Pain that occurs anytime of the day .
- Abdominal pain that occurs with vomiting & headaches.
- Pain in the arms or legs.
- Lack of appetite ,without losing weight.

RAP has found to be common in the setting of school phobia, sibling rivalry, family history of pschycological problems ,and disturbed inter-personal relations. Non-organic RAP ( NORAP) is more common in Indian children.

RAP was found to be due to organic cause when

1. An abnormality is detected in an organ (organic) is detected.
2. Clinical and laboratory evidence of response to treatment.
3. Remission for atleast 3 months from pain after relief with treatment.

All other children with RAP, who donot have relief as above criteria are considered to have non-organic RAP.A physical cause is found in less than 10% of children diagnosed with RAP. The physical exam and routine tests often do not show any abnormal problems. Pain may get worse with stress, anger & excitement. The commonest pattern of abdominal pain was -periumbilical pain of steady, non-radiating character, each lasting 5 -30 minutes ,occurring daily with no specific aggravating or relieving factors. Charecterstics of pain did not differentiate between organic or non-organic abdominal pain.interference with sleep was more common in organic pain.

## ▶ Difference in Presentation Between Toddlers and Children .

Babies and toddlers they behave to abdominal pain differently than older children. A baby can become fussy , draws his or hers legs up towards the belly , eat poorly. Older children may be able to point to the area of the pain and describe how severe it is.



## ▶ Common Causes For Rap ?

studies show ( Indian & western ) shows that children with non-organic RAP are living in a different pschyo-social environment at school and at home. This may have some role in the genesis of this pain. Children who lived in larger joint families , where overcrowding may account for a higher prevalence of parasitic and other infections ( infective etiology), which can cause RAP.Children with RAP, less than 2yrs of age will usually have organic cause, while above 2yrs of age –only 10% have organic cause.Emotional components like- school phobia, single parent, sibling rivalry, stressful life events will play a role in non-organic RAP. Mesenteric adenitis, chronic constipation, abdominal migraine are the other causes.

### Organic Causes

The common organic causes found for organic RAP are ...peptic ulcers ( Helicobacter pylori infection), parasitic infestations, urinary tract infections, vesico-ureteric reflux and abdominal epilepsy ,urolithiasis, appendicitis, pancreatitis, meckels diverticulum , , abdominal TB, gastritis and cholelithiasis ,ulcerative colitis, and crohns disease .

Mean duration of illness was longer , in patients with non-organic RAP. Interference with sleep due to pain is not noted in functional pain ( non-organic RAP). Nocturnal enuresis (bedwetting at night),sleep disturbances , generalized aches– symptoms which has got a pschycological basis is more common in non-organic RAP. This shows that the basis for the non-organic RAP in children( Indian or abroad ) seems to be underlying pschycological instability.

## ▶ How To Differentiate Between Organic And Functional Recurrent Abdominal Pain ?

### Site of pain

In organic diseases , pain can occur anywhere but more common in right upper and lower quadrant pain, flank pain and supra-pubic area pain is common.But in functional ( non-organic pain) abdominal pain usually occurs around belly button ( Periumbilical area).

### Family history

Family history of depression, abdominal pain and headache are common in functional non-organic RAP rather than in organic RAP.

### Pschycological factors

Like anxiety is more common in non-organic recurrent abdominal pain. Alarm symptoms are more common in organic recurrent abdominal pain. These symptoms are... Recurrent or persistant vomiting,Chronic severe diarrhea,Unexplained fever,and bleeding per rectum.

### Abdominal signs

Abdominal signs like tenderness, muscle guarding and palpable mass are more common in organic recurrent abdominal pain.

### Abnormal weight loss or weight gain

Abnormal changes in weight like loss or gain is more common in organic RAP. Normal apetite and weight gain is noted inspite of recurrent abdominal pain in non-organic RAP.

### Nocturnal pains

Sleep disturbances with attacks of pain in the night are more common in organic RAP. In non-organic RAP, normal sleep pattern with no attacks during the night once the child goes to sleep.

### Abnormal investigations

Investigations like ESR, urine examination, and Full blood picture are abnormal in

organic recurrent abdominal pain. Blood investigations are normal in functional & non-organic recurrent abdominal pain.

## ▶ Evaluation

The following basic tests are done in cases of recurrent abdominal pain

1. Complete blood picture ( CBP)
2. Complete urine examination / culture ( urinary tract infection to be excluded )
3. Stool examination.
4. Inflammatory markers - CRP & ESR.
5. Blood urea, creatinine & serum electrolytes.
6. Liver function tests
7. Screening ultrasound examination of abdomen.(rule out liver, renal pathology and TB abdomen )

Further evaluation depends on suspicion , presence of alarming signs and differential diagnosis

1. Upper and lower GIT endoscopy ( when inflammatory bowel disease , gastro-esophageal reflux and H.Pylori infection is suspected).
2. Contrast studies of Gastro-intestinal tract ( to R/o abnormalities of rotation of intestines )
3. Gut motility studies only in cases of motility disorders.
4. CT scan / MRI studies only when some organic pathology is found –which needs further evaluation.

## ▶ Management

Most cases of RAP, does not need any treatment except reassurance that there is no serious underlying pathology. In those with persistent and severe symptoms, finding an effective treatment is difficult. It needs multi-disciplinary approach with involvement of family.

## ▶ Medications

There are a few well designed, clinical trials studying the efficacy of drug trials in functional bowel disorders in children. Trial of analgesics and antispasmodics , antacids will help

## ▶ Dietary Management

Supplementing the dietary fiber in food , has lessened the attacks of RAP in scientific studies. The concept of Use of Probiotics ( foods that include live, health promoting bacteria) and Pre-biotics ( foods that encourage growth of endogenous health promoting bacteria) can reduce the imbalance within the gut and reducing the RAP attacks is gaining popularity now. Lactose –free diet is advised only in those children with proven lactose intolerance. Other wise restricting the diet will put the child at risk of deficiencies.

## ▶ Psychological management.

These childrens need Psychological counselling to found out the underline Psychological disturbances leading to constipation.

## ▶ When the Abdominal Pain Should be Taken Serosly ?

Pain without other symptoms, which subsides in 3hrs time is usually non-dangerous. But the presence of following symptoms will give a clue that the pain should be taken seriously and needs to be evaluated. These symptoms are.....

- Pain disturbing the sleep during night.
- Recurrent or persistent vomiting
- Greenish or yellowish vomiting
- Chronic severe diarrhea
- Unexplained fever.
- Gastro-intestinal blood loss.
- Pain with significant weight loss.

## ▶ What is Mesenteric Adenitis ?

Mesenteric lymphnodes are lymphnodes which are present in the mesentery ( layer attaching the small intestine to the abdominal wall.) they are about 4mm or less in size, and are of oval or disc shaped. Mesenteric adenitis is a self-limiting inflammatory process that affects the mesenteric lymphnodes in the right iliac fossa. Its clinical picture mimics that of acute appendicitis. Mesenteric adenitis is most frequently caused by viral pathogens. But other etiologies have been implicated like campylobacter, helicobacter and salmonella. An association with streptococcal infection of upper respiratory infection- particularly pharynx has been noted. In younger children, associated ileo-colitis may be present. This suggests that lymph node involvement is may be a reactive process to enteric pathogen.

Ultrasonography of the lower right quadrant is the mainstay of diagnosis. About 20% of children who underwent appendectomy , found to have mesenteric adenitis with normal appendix. Mesenteric adenitis is found to be self-limiting and if properly diagnosed , any interventional surgery can be avoided.

## ▶ General Tips & Pre-Cautions to Parents.


- Child with recurrent abdominal pain should eat regular diet.
- Should do normal regular activities.
- Avoid taking outside junk food, spicy food and stored food.
- Give anti-helminthic course, (ALBENDAZOLE -10mg/kg (200mg maximum) once in 6 months till 15 years of age.)
- Regular hand & legs-washing before taking food items.
- Proper washing of the vegetables before cooking or before children eat raw food.

- Sufficient quantity of liquids should be taken. ( studies show that we need -1 ml of water /liquids per 1 kilocalorie of energy requirement.)
- Teach the children, to empty their bladder once in 3 hours during the daytime . They should not hold the urine for long hours.
- Take measures to prevent constipation in children. They should empty their bowels on daily basis without strain. Good fiber food, intake of good quantity of leafy vegetables, and sufficient liquid intake will prevent constipation.
- Tell them to consider the recurrent abdominal pain like a routine headache without giving much importance

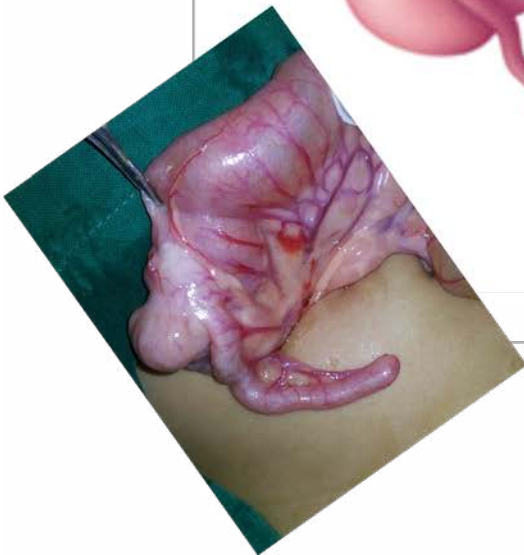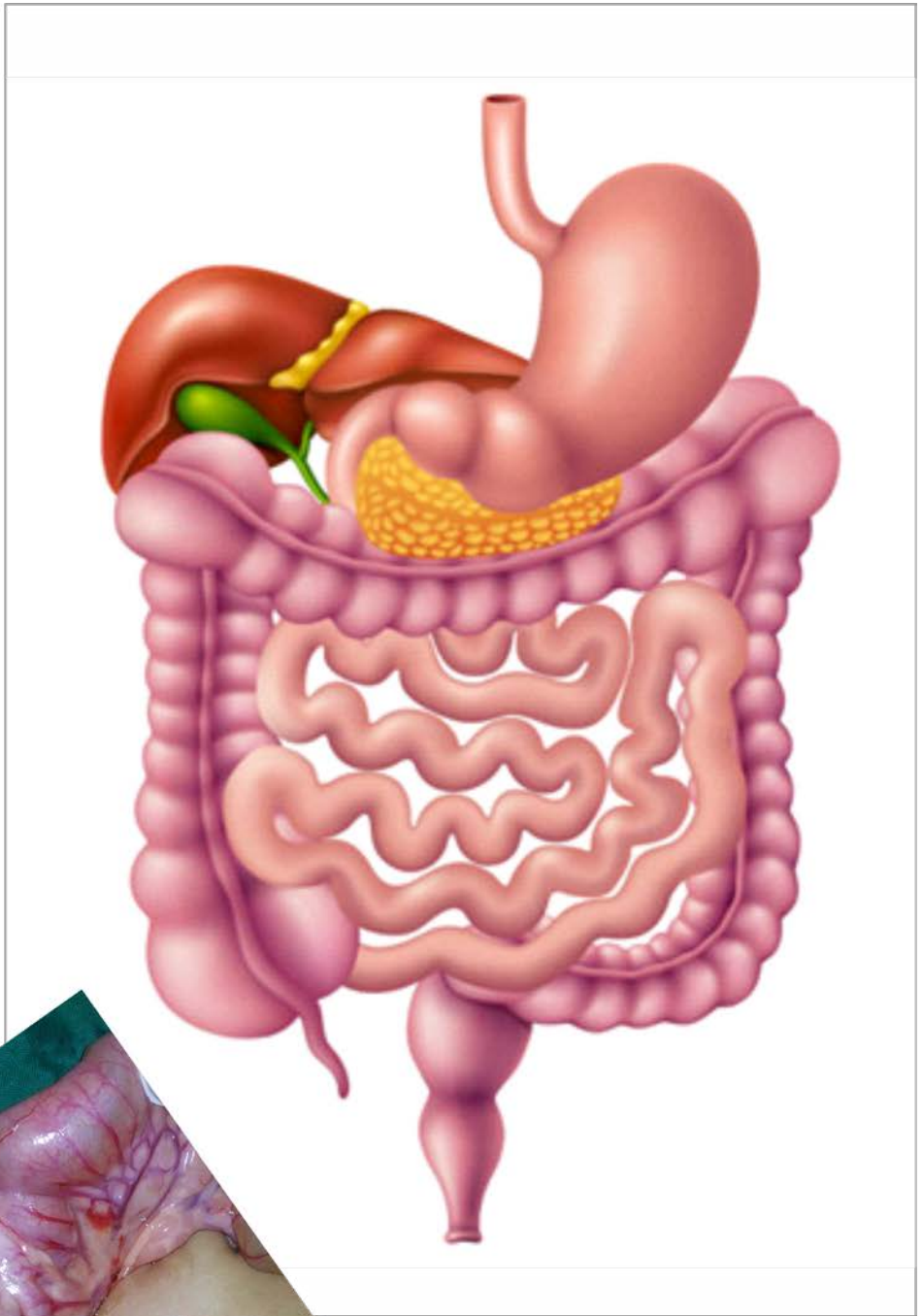
## ▶ Conclusion

- Not all recurrent abdominal pains in children are to be taken seriously. What they need is only counseling and reassurance.
- Pains with in specific areas, occurring during specific times associated with warning symptoms should be taken seriously and investigated further to find out the organic cause.
- If parents fail to differentiate the two types of pains and gives too much importance to the non-organic, functional pain- it leads to lot of anxiety to the parents, loss of education time to the students, asking for unnecessary investigations, financial strain and diagnostic dilemma to the treating physician.
- Although injury, pressure and stretching of our bodily tissues cause pain, the sensation of pain can also be made, increased or altered by the brain. There are pain 'centres' in the brain, which receive signals from body tissues but also from the thinking and emotional areas of the brain. The final pain sensation is created by the brain from all three.

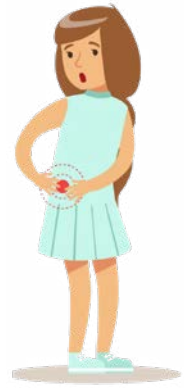




## APPENDICITIS IN CHILDREN



**Acute appendicitis** ... the name itself will raise fear in the minds of the parents because the appendix, a small segment from intestine may create trouble at any time with infection and perforation. Suspicion is easy but confirmation is difficult in case of appendicitis. Appendix is the first part of the large intestine. It is present at the junction of small and large intestine. It does not take part in the function of the large intestine ( Vestigial organ). usually it is about 6-12 cm in length. Its position & direction varies in each individual. Because its lumen is narrow and it is present at an acute angle intestinal contents does not enter the lumen of appendix. Mucus will be produced in the appendix which will enter regularly into the lumen of the large intestine but intestinal contents cannot enter the appendix. If the lumen of the appendix is obstructed it will lead to swelling and later infection- acute appendicitis.



### ▶ Types of appendicitis

There are two types of appendicitis based on the reason, by which acute appendicitis is developed. One is obstructive and other is infective. In obstructive appendicitis, the lumen of the appendix is obstructed by fecal matter or worms, then the mucous secretions within the appendix are retained and swell the appendix leading to its infection. In infective appendicitis, bacteria can enter the intestines through contaminated food or water and finally lodge in appendix leading to acute appendicitis.

be centered at umbilical area. That is why any pain in abdomen is initially will be referred to umbilicus, later due to development of local peritonitis pain will be shifted to the local area. Later fever develops. Fever will be high and unrelenting. Later patient develops reflex vomitings due to nerve signals. vomitings may be one or two or there may not be any vomitings. Later loss of appetite will occur as the infection is in the intestines. If these symptoms are there, then appendicitis should be suspected.

### ▶ Symptoms of appendicitis

To diagnose appendicitis, the symptoms are very important. It starts with Pain in right lower abdomen and later with fever, vomiting and loss of appetite. These are the 4 main symptoms. Pain in appendicitis is very peculiar. Pain starts around the umbilicus but later shifts to right lower abdomen as the time passes. This is called shifting pain. Usually it takes 6-8 hours for the pain to shift to right lower abdomen. All the nerves will

### ▶ All pains are not due to appendicitis

Pain in right lower abdomen is not always due to appendicitis. Other conditions that can produce the right lower abdomen pain are -urinary tract infections, ureteric stones, infective diarrhoea, mesenteric lymphadenitis, in girls pelvic inflammatory disease, referred pain from right lower lobe pneumonia and liver abscess. So when ever a child comes with right lower abdominal pain, it should be confirmed as appendicitis by clinical examination.

## ▶ Pain at Mcburneys point

Even when a battery of tests are available still the one condition which can be diagnosed with accuracy by clinical examination is acute appendicitis.

Whenever there is pain in lower abdomen the doctors wants to rule out appendicitis. For this there is a specific area on lower abdomen, where the doctors will examine to rule out appendicitis. This area is called Mcburneys point. If you imagine a line from umbilicus to tip on the highest point on pelvic bone( anterior superior iliac spine) and at the junction of 2/3 and 1/3 of this line from umbilicus is the Mcburneys point. If the doctors touch this area with a point of a finger,if there is appendicitis in the patient, they will complain of severe pain. This is the key sign in diagnosing acute appendicitis.

**Shifting pain:** as the appendicitis progresses,there will be spread of infection to the abdominal wall leading to local peritonitis. Initially the small intestinal pain will be felt at the umbilicus but later due to development of local peritonitis,the pain will shift from umbilical area to right lower abdomen.( shifting pain)

**Muscle guarding :** As the infection spreads to the abdominal wall muscles,the muscles will becomes hard to touch .this is called -muscle guarding.muscle guarding indicates perforation of appendix.

**Pain on coughing :** in acute appendicitis,if doctor asks the child to cough, they will point to the right lower abdomen while coughing,it is a sign of acute appendicitis.

**Pain on moving right leg :**in acute appendicitis, the children will move the left leg easily but when moving the right leg they will feel pain due to the contact of the inflamed appendix to iliopsoas muscle.

In chubby and fatty children, these signs may be difficult to elicit due to fat. So,the

diagnosis of appendicitis may not be easy in chubby children and chances of perforation is high in fatty children.

## ▶ ultrasound is the investigation of choice

Normal appendix is difficult to detect but inflamed appendix is easily detected. If the thickness of the wall of the appendix is more than 6mm it is suspicious, if it is more than 8mm it is confirmatory of appendicitis. Any collection around appendix can also be seen ( periappendicular collection).

**Blood tests will help :** in acute appendicitis, the white blood cells will increase. They will rise above 10,000/cmm . within white cells, the neutrophils will rise and will be more than 70% of all cells. C-reactive protein ( CRP) will rise to more than 6, in appendicitis as a reaction of body to infection.

## ▶ what is the treatment for appendicitis

Once it is confirmed as appendicitis by doctors examination and medical tests, surgery is the only option for acute appendicitis. Even if it is controlled with medication, it is likely to recur again. So surgery is the best option. Once it is confirmed as appendicitis it is better to undergo surgery within 24 hours. If we wait for more time, the appendix may burst leading to discharge of pus and fecal matter in to the abdomen ( fecal peritonitis ). This is a dangerous condition,it can lead to more suffering and also risk to life. Even if we give a thorough wash is given to take out all infective material,still there is a chance of development of adhesions of bowel. In females the pus collects in the pelvis,involving the fallopian tubes leading to infertility problems.

appendicectomy can be done in two ways. Either by open method or laparoscopic method. In laparoscopic method a camera is introduced through the umbilicus and



appendectomy was done using 5mm small instruments introduced through working ports. In this the cuts on the skin are very small, minimal muscle injury, less scar, less pain, early recovery. Because of these advantages, laparoscopy is the best way for appendectomy.

In cases where there is less pain, clinical picture is not clear, ultrasound is not able to confirm, it will be treated with medications for 24-48 hours. Then it will be reassessed, and a decision is taken to continue medication or to do surgery.

### ▶ No more a vestigial organ

At one time appendix is considered as a vestigial organ as it is not participating in any way in digestion . but with the advances in science the appendix is no more a vestigial organ.it is useful in many other areas as a conduit for the passage of the contents.

- Part of vigilance system: there is an extensive vigilance and immunity system in the gastrointestinal tract. Starting from tonsils in the mouth, Peyer's patches at the junction of small and large intestine, lymphatic glands associated with GIT, all are combinedly called " Gut associated lymphatic tissue " ( GALT). Any disease producing organisms entering the body will be picked up by these tissues and prevent them from producing infections.
- As a conduit : Previously, when ever an emergency laparotomy was done, appendix is used to be removed. There is a drastic change towards preserving appendix in the present days as it is used as a conduit where ever it is necessary. In ureteric repairs, fallopian tube reconstruction and as a conduit draining the bile from liver, appendix can be used. Appendix can be used as a

conduit to drain the urine from bladder in cases of neurogenic bladder, it is placed between bladder inside and skin outside ( Mitrofinoff procedure). It is used to give antegrade enemas when it is placed between colon ( large intestine) and abdominal wall outside ( Malones procedure).

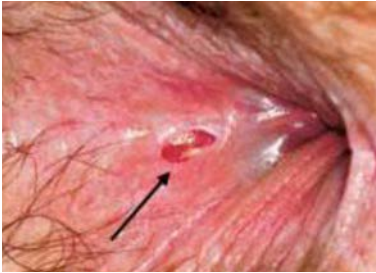### ▶ interesting facts about appendicitis.

- **More common in cities** : appendicitis is noted to be more common in cities. Probably the food habits in cities may be the reason. Low fiber diet in diet in cities will reduce the bowel movements leading to constipation, reduced movement of mucus in appendix and bacterial overflow will be the probable reasons.
- **More common in summer** : gastroenteritis like GIT infections will be more common in summer, which can increase the chances of appendicitis in summer.
- **More common in adolescence age** : appendicitis is more common in 12-19 years age group children. Less common in children less than 4 years. Can occur in age group between 6-12 years.
- **Treatment should be aggressive in girls** : in girls the internal genitalia like fallopian tubes and ovaries are very close to appendix. If at all the appendicitis occurs, it can spread to fallopian tubes and can lead to infertility problems. That's why the appendectomy surgery is 2.5 times more common in common in girls.
- **Risk is reduced** : Compared to previous years, at present because of awareness, the incidence of appendicitis and its perforation rates got reduced.



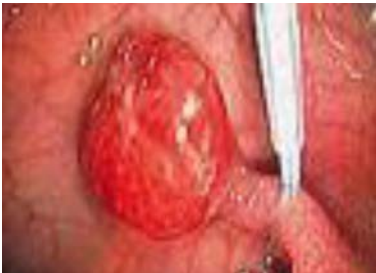

## **BLEEDING PER RECTUM IN CHILDREN**



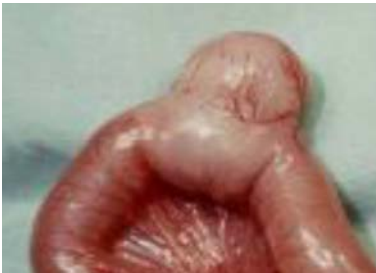**Anal Fissures**

---



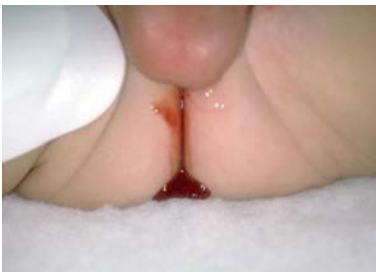**Rectal Polyp**

---



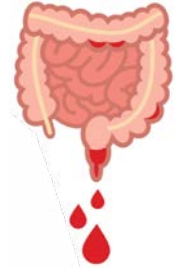**Meckels Diverticulum**

---



**Perianal Hemangioma**

## BLEEDING PER RECTUM IN CHILDREN



- A 6 day old male child was brought with history of greenish vomiting, excessive crying and history of passing blood in the stools. He had repeated attacks of passage of blood in stools. He was evaluated and found to be having - **MALROTATION OF MIDGUT WITH VOLVULUS**. He underwent an emergency surgery.
- A 8 month old female child presented with history of sudden attack of abdominal pain, followed by relief after few minutes. She had repeated attacks of such episodes followed by greenish vomiting and passage of blood in stools. Baby on evaluation, was found to be having -**INTUSSUSCEPTION**. She underwent an emergency surgery.
- A school going 5 years old boy had history of passing hard stools on alternate days. After few days he started passing small fresh bright red bleed per rectum. He was found to be having - **ANAL FISSURES**. He was treated conservatively.
- An 8 years old boy presented with history of intermittent attacks of pain abdomen associated with passage of bright red blood per rectum. On evaluation by colonoscopy he was found to be having - **POLYPOSIS OF COLON**. In all these case scenerios, the alarming symptom is - passage of blood per rectum.

Blood is essential for life but the same blood if we see we get panic. Particularly in case of children, if they pass blood per rectum, the anxiety and tension will be more. children because of their ignorance they are not panic but parents will be tensed if there is bleeding per rectum in children. Bleeding per nose is a common complaint but bleeding per rectum is not so common, but still it is a frequently heard complaint. Bleeding per rectum is a fairly common complaint in pediatric age group and accounts for 10 – 20% of referrals to pediatric gastroenterologists. The causes for the bleeding are extensive and varies according to the age. The bleed can be bright red (HEMATOCHEZIA) when it comes from the

lower part of the intestine, Or it can be altered blood (MALENA) when it comes from the higher up level of gastrointestinal tract. Even a small bleed can appear large when mixed with stools and it can be alarming for both parents and attending physician. But luckily most of the bleeds in children are selflimited and its cause can often be determined with a careful history and physical examination.

Even though the bleeds can stop spontaneously or during the course in the hospital, as the blood volume in children is small it is important to begin resuscitation as early as possible. Any bleed containing blood more than 10% of blood volume should be monitored in an intensive care unit.

## ▶ Causes according to the age

**NEWBORN CHILDREN..** ano-rectal fissures (most common reason in this age group)

Swallowed maternal blood.

Necrotizing enterocolitis.(infection of the intestines)

Malrotation with midgut volvulus.(bowel will be fixed in a different pattern with a short attachment at base)

**INFANT (FROM 1 MONTH TO 1 YEAR)** Ano-rectal fissures (most common)

Intussusception

Meckels diverticulum

Henoch-schnlein purpura

Gastro- intestinal duplication

infectious colitis.

**PRE-SCHOOL GOING CHILDREN** juvenile polyps (most common)

Infectious colitis.

Intussusception

Meckels diverticulum.

Henoch- schnlein purpura.

**SCHOOL AGE/ ADOLESCENCE** juvenile polyps.

infectious colitis

inflammatory bowel disease

things to remember is sometimes massive upper GIT bleed can give rise to lower GIT bleed. Trauma to abdomen can give rise to lower GIT bleed. Coagulopathy can give rise to generalized bleeding including lower GIT.

## ▶ Anal Fissures

Most common cause of lower GIT bleed in the first 2 years of life.

Anal fissures are common at both the extremes of age. These are due to lack of the

anorectal angle. This angulation is formed by the bowel being pulled to front by the continence muscle called- Puborectalis. This angulation will slow down the oncoming stool force. In newborns anorectal angle is not formed and in old people, because of the muscle weakness the angulation is lost. Due to this, the oncoming stool coming with force will hit the anal verge without slowing down. This leads to the development of anal verge cuts -called anal fissures. Blood is usually bright red in colour. Bright red blood will come out as drops at the end of the defecation and blood will stain the outer surface of the stool. Usually it follows passage of a large constipated stool. it is caused by a tear in the superficial layer of the anus.

Usually it is painful condition and leads to withholding of the stools further. Hard stool causes anal fissures. Anal fissures leads to sphincter spasm and withholding of stools, which again produces or activates the existing anal fissures while passing hard stools. This will lead to a vicious circle leading to a severe constipation in newborns & children. Anal fissures needs immediate attention. The stool has to become soft to give rest to the ulcers to heal, the sphincter spasm has to get relieved for the ulcers to heal. This can be achieved with the help of laxatives, ulcer healing ointments, local anaesthetics and in grown up children, with fiber rich diet.

## ▶ Meckels Diverticulum

It results from the non- closure of the omphalomesenteric duct (communication of the GIT through the umbilicus during the embryonic period of development of gastrointestinal tract). the remains of this communication can present in various ways. One of the presentation is Meckels diverticulum. It presents as a pouch attache to the external side of the bowel. It is present in 2% of normal population. Usually it is present within 2 feet from the junction of small &

large intestines. There will be secretions developed within the Meckels diverticulum due to ectopic mucosa. Bleeding occurs from the ulcers developed in the adjacent normal small intestine due to acid secretion from the Meckels diverticulum (ectopic mucosa). It is characterized by painless passage of large amount of bright blood per rectum.

Diagnosis of Meckels diverticulum is slightly difficult. Is diagnosed by diagnostic laparoscopy done when there is a suspicion of Meckels. Supportive investigations like ultrasound abdomen, CECT abdomen, Meckels radionuclide scan done during bleeding episode will not be able to rule out presence of Meckels diverticulum. Only 2% of Meckels diverticulum will be symptomatic. Only symptomatic Meckels diverticulum will be treated, otherwise asymptomatic Meckels diverticulum should be left alone. The treatment of symptomatic Meckels diverticulum is surgical excision. The bowel segment containing the Meckels has to be resected along with Meckels diverticulum and bowel continuity is maintained by end-end anastomosis of the cut edges of bowel.

## ▶ Intussusception

Most commonly occurs below 2 years of age (more common between 6-9 months of age). It is due to passage of one part of the bowel (proximal bowel) into the other part which is distal to it. Usual type of intussusceptions is ileo-colic type i.e. the distal small bowel enters into large bowel and with each peristalsis (movement of bowel) moves further into the large intestine.

Intussusception is one of the real emergencies in the children's surgery. It is because, as the bowel enters the colon it takes its blood supply along with it into the colon which gets kinked at its entry point. Unless it is released immediately it will lead to loss of blood supply to the bowel (gangrene) which has entered inside.

Intussusceptions presents suddenly in a previously healthy child, who cries suddenly and excessively. It gets relieved spontaneously after a few minutes. Only to be repeated again after sometime. Later child develops abdominal distension, greenish/ yellowish vomiting and passage of blood per rectum. Once it is suspected, ultra sound abdomen is the investigation of choice to diagnose. Once diagnosed, intussusception has to be treated immediately because of risk of gangrene. Intussusception can be relieved by non-operative methods in the early period following diagnosis (3-6 hours). It is done by hydrostatic reduction under ultrasound guidance in which fluid is introduced into the rectum through a tube from a height. This water pressure pushes (reduces) the oncoming small bowel from large intestine. If it presents in later period or if hydrostatic pressure fails to relieve then surgical correction is required. During surgical correction, if the bowel is not gone into gangrene, simple manual reduction of intussusception will be done. If the bowel intussuscepted has become gangrenous, it should be resected and bowel continuity is maintained by doing end-end anastomosis of the small intestine.

## ▶ Juvenile Polyps

Most common source of rectal bleeding between 2-8 years of age. Polyps are abnormal outgrowths from the intestinal wall. Polyps can occur anywhere in the GIT. Majority of them are located in the distal large bowel (recto-sigmoid area). Most common are solitary polyps in the rectum. They are benign (not cancerous). They cause bright red blood on the outer surface of the stools. The bleeding is usually painless. Bleeding occurs either due to trauma caused by hard stools or due to autoamputation.

Polyps in the rectum are diagnosed by digital rectal examination. Polyps high up in colon or distal small bowel can be diagnosed by

colonoscopy. Treatment of polyps involves removal of polyp (polypectomy) if they are single (solitary rectal polyps), resection of bowel containing polyps when they are multiple & occupying a large segment of bowel. Extensive intestinal polyposis is familial (tendency runs in families) and they are precancerous.

## ▶ Inflammatory Bowel Disease

Inflammatory bowel disease causes parts of the bowel to get inflamed, swollen and red. It is a chronic condition -it stays for a longer period, comes and goes. There are two types of inflammatory bowel disease present Ulcerative colitis and Crohn's disease. Ulcerative colitis involves only the large intestine (colon) and ulcers involve only superficial layers of bowel. Whereas Crohn's disease involves any part of the gastrointestinal tract and involves all layers of the intestine. Both these conditions will present with bleeding per rectum. The other symptoms are Painful cramps in abdomen, watery diarrhoea, loss of weight, fever and extreme weakness. They can cause other problems like eye problems, rashes, joint problems, arthritis and liver problems.

The exact cause of inflammatory bowel disease is not known. It is probably a combination of genetic predisposition, immune system and something in environment which triggers inflammation in the gastrointestinal tract. Diet and stress makes the inflammation worse. Tends to run in families. Usually occurs in teens and young adults. They present mostly before 20 years of age. Rectal bleeding will present in 100% of ulcerative colitis and 25% of Crohn's disease. They present with recurrent abdominal pain, loss of weight and bleeding per rectum. These conditions will be diagnosed by Diagnostic colonoscopy and colonoscopic biopsy. Goal of treatment is to relieve the symptoms, prevent future flare-

ups, and possibly heal the inflamed intestines. Treated by medical treatment, changes in diet and surgery. Medical treatment is required to treat bowel inflammation and infection. Surgery may be required if they present with perforation, intestinal obstruction or massive persistent bleeding.

## ▶ Vascular Malformations (Angiodysplasia)..

These are abnormalities in blood vessels supplying intestine. In this condition the vessels normally supplying the intestine will turn into a large mass of blood vessels projecting into the intestine. Bleeding occurs due to either trauma or ulceration of the vascular malformation. This anomaly can be detected either by angiogram or endoscopy. It will be corrected by surgery where the segment of bowel containing the vascular malformation will be removed and intestinal continuity will be restored.

## ▶ Necrotizing Enterocolitis

This condition occurs commonly in preterm newborn babies within 1 month. This condition typically starts after giving feeding to the baby.

Presence of substrate (feed) will lead a chain of events which finally end up with infection in the wall of the intestine. Infection produces ulceration, bleeding and perforation depending on the stage of infection.

When NNEC develops, babies will become dull, refuse feeds and abdominal distension develops. Later abdominal wall erythema (redness) develops. In the early stages this condition will be treated with antibiotics and supportive treatment. Later once complications like necrosis, gangrene or perforation develops then surgical intervention is needed.



## ▶ Intestinal Obstruction with Gangrene

intestinal obstruction can occur in children because of various reasons. If obstruction is not relieved in time, it leads to vascular compromise due to distension of intestinal wall. This vascular compromise will lead to bleeding inside the intestinal lumen and later to gangrene of the intestine. Bleeding per rectum with intestinal obstruction implies that either impending gangrene or established gangrene.

## ▶ Hemorrhoids

Rare in children. Hemorrhoids are engorged veins from the rectal wall. If they are present it indicates either presence of a condition called portal hypertension or a mass lesion in the pelvis causing extrinsic pressure over the rectal wall. They are extremely rare in children. Treatment depends on the cause of the hemorrhoids. If they are primary (which is very rare) hemorrhoidectomy will be done. If they are secondary manifestation of some other disease, the treatment directed towards the disease will relieve the hemorrhoids.

## ▶ False Positive Visible Blood in the Stools..

this can happen due to use of antibiotics (ampicillin, rifampicin), iron, chocolates, eating beets.

## ▶ Food Allergy

food allergies can lead to bleeding per rectum. They present with postprandial discomfort, nausea, vomitings, diarrhea and iron deficiency anaemia. May exhibit with malabsorption. GIT may be infiltrated with eosinophilia and peripheral eosinophilia may be present. Allergens may include cows milk or soya protein and sea food.

## ▶ How to Evaluate

### 1. HISTORY...

- Duration and amount of the bleed.
- Colour of the bleed and relation to stools,
- consistency of stools will give a clue.

### 2. PHYSICAL EXAMINATION ...

- presence of jaundice, anaemia.
- presence of Abdominal distension,
- presence of mass per abdomen
- presence of anal fissures ..... Will give clue to the diagnosis.

### 3. INVESTIGATIONS

- Blood investigations,
- Ultrasound examination,
- X-ray abdomen and
- Endoscopy
- Angiography
- Radionuclide studies
- Diagnostic laparoscopy ...will give the appropriate diagnosis.

## ▶ When to be Cautious.....

- If the bleed per rectum is continuous
- If the bleed per rectum is massive
- If the bleed per rectum is associated with pain
- If the bleed per rectum is associated with abdominal distension
- If the bleed per rectum is associated with organomegaly.

## Key Points :

Most of the bleeds per rectum are small bleeds.

Most of the bleeds per rectum are benign and self limiting.

Constipation is one of the major etiology in children, by producing anal fissures.

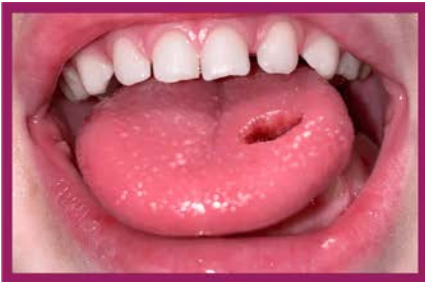Report immediately if bleeds are continous, massive or associated with pain

Endoscopy and ultra sound abdomen are the most important evaluating tools.

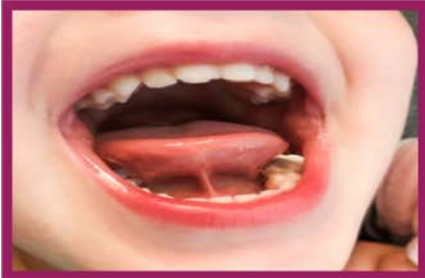



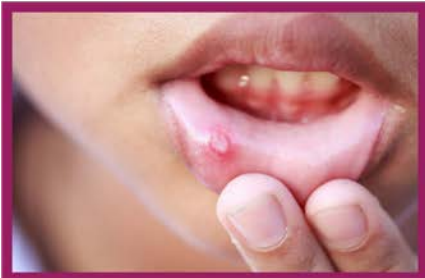## ORAL CAVITY LESIONS IN CHILDREN



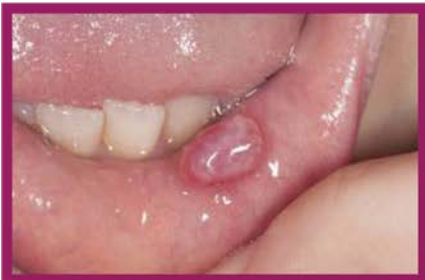▶ Tongue laceration



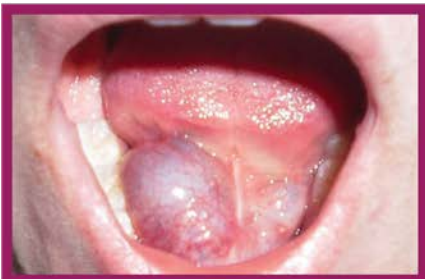▶ Tongue Tie



▶ Aphthous Stomatitis



▶ Mucous Retention Cyst

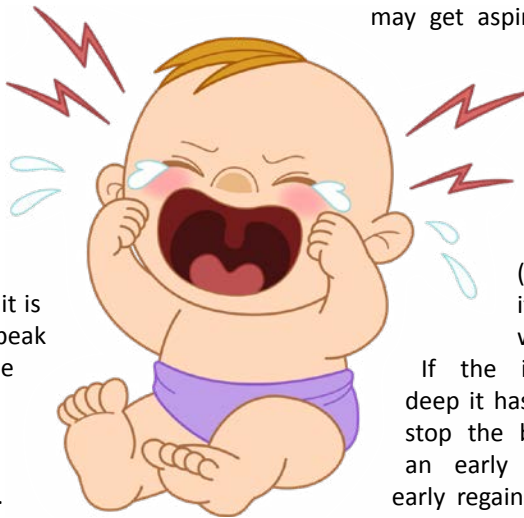

▶ Ranula

Childrens body is very tender and sensitive, particularly oral cavity. If a lesion occurs in the oral cavity of the children, parents will get panicked and tense. The easy swallowing of the diet we have taken, is due to the mixing of saliva secreted in oral cavity with the food. The tongue, mucosa over the lips and cheeks are lined by a moist layer. Any problem in this sensitive area will lead to pain and difficulty in swallowing. Wheather it is tongue injury, tongue attachment, infection in the mouth many things can affect the tongue in children. These oral lesions may interfere with food intake, interfere with speech, interfere with proper oral hygiene and some lesions if neglected may recur in future. Pain in oral cavity may be tolerated by the adults but not by the children. It is always better for the parents to have awareness about the oral cavity lesions,diagnose them early and get it treated early.

### ► Tongue laceration :

- Shravan is a 3years old boy. One day he felled and got hurt. Mother noticed a deep cut in the tongue. The neighbours told her not to get it stitched. If it is stitched child may not speak properly latter. Once the child is taken to doctor- he said it has to be sutured immediately. Parents got confused. What is correct ?



may get aspirated in to lungs.

During treatment any broken teeth if they are there,they have to be removed. If the injury is superficial (only Mucosal) it will be treated with medication.

If the injury is muscle deep it has to be sutured to stop the bleeding, to have an early healing, and to early regaining of the tongue movements. Tongue suturing will not lead to speech problems .it

is a misconception. If the tongue injury is more than 2cm, if it is through and through injury, U-shaped injuries, if a bit of the tongue is hanging,if the injury involves the edge of the tongue and if there is continuous bleeding the tongue injury has to be sutured. Usually it takes around 7 days for the swelling and it takes around 2-3 weeks for the healing. If the tongue tissuse loss is less than 30% the edges of the tongue are sutured together. If the loss is more than 30% it has to be has to be repaired by an expert .

Childrens tongue is injured in many occasions- due to falls, cycle injuries, putting sharp objects in the mouth, fall due to fits and hitting hard objects. Children will keep the mouth open during play time and if they get hurt at that time tongue is likely to get hurt. Tongue has got extensive blood supply, so even a small injury can lead to massive bleeding. Mouth can be filled with blood, the shape of the tongue may get altered, movements of the tongue may be restricted, infection and swelling of the oral cavity can occur. Some times if the bleeding is more it

## ▶ Tongue tie

- Trisha is a 9 months baby, when ever she is laughing and crying, the tip of the tongue is attached by a thick band to the floor of the mouth and she is not able to put the tongue out. Trisha's grandfather has the same problem and his pronunciation of the words will not be clear. Parents of the trisha are worried that her speech also will be same like grand father . They met the doctor,he said it is tongue tie and it has to be surgically released.

It is a birth defect. It is called Ankyloglossia. With tongue-tie, an unusually short, thick or tight band of tissue (lingual frenulum) tethers the bottom of the tongue's tip to the floor of the mouth. Typically, the lingual frenulum separates before birth, allowing the tongue free range of movements. With tongue-tie, the lingual frenulum remains attached to the bottom of the tongue. Why this happens is largely unknown, although some cases of tongue-tie have been associated with certain genetic factors. some cases runs in families. If it persists till tip it will lead to tongue tie. it may lead to difficulty in feeding and feeding time may be prolonged. Someone who has tongue-tie might have difficulty in putting out his or her tongue. Tongue-tie can also affect the way a child eats, speaks and swallows. Boys are more affected than girls. During feeding tongue will come between the nipples and gums .in tongue tie situation, as the tongue movement is restricted, it will lead to fissures on the nipples due to pressure affect of gums. If they put the tongue out, the tip of the tongue looks heart shaped. The movement of the tongue cleans the inner surface of the teeth. So, dental hygiene is affected in tongue tie cases. The initiation of speech may be delayed and also the slang of the speech may also be affected.

Tongue Tie is to be released between 8 moths -12 months. If it is thin only frenotomy -release of tongue tie is enough. If the tongue tie is

thich, it needs to be released and repaired- frenuloplasty. It will heal in 2 weeks time. Children are prevented from putting fingers, sharp objects in to the mouth during these 2 weeks time.

## ▶ Cyst over the lip (Mucous retention Cyst)

- 9 years old nidhi has developed a small cyst over the lower lip. It is painless . not increasing in size, and growing slowly. Nidhi has no complaints but parents are worried and got many doubts -will it increase, will it cause any further complications

This condition is called – mucous retention cyst or Mucocele. We have around 800-1000 minor salivary glands. Each salivary gland will empty their salivary secretions in to the mouth through a small duct. If the duct is blocked it will lead to retention of salivary secretions and a cyst formation. It will happen due to trauma to the oral cavity, injury to the lips or some children will have the habit of biting the lips and due to poor dental hygiene. This leads to retention of salivary secretions. They occur mostly on the inner side of lower lip. They will reach a size of 2-5 cm. occurs equally both in males and females. they will increase in size and then bursts only to be redeveloped after sometime. This is usually painless. present only as a raised, soft swelling. If it is large and if it is painful it needs to be removed surgically along with attached minor salivary gland. To prevent recurrence, children are advised to avoid biting of the lips.

## ▶ Cyst in the floor of the mouth (Ranula)

- Laxmi is a 3years old girl, noticed by the mother to have a swelling from the floor of the mouth which is growing and lifting the tongue to oneseide. The attending doctor said it is Ranula and needs to be corrected by surgery.

Ranula is a swelling arising due to injury to the major salivary gland duct. We have three major salivary glands. One of the major salivary glands will be below the tongue, called sublingual salivary gland. The produced saliva from this gland, will be poured in to the mouth from the duct opening on the undersurface of the tongue. If its duct is ruptured, the leaked saliva will collect and form a cyst below the tongue on one side, lifting the tongue. This is called -Ranula. Based on the extent of collection of saliva, the ranulas can confine itself to oral cavity ( simple ranula) or they may extend in to the neck ( plunging ranula). If it is small and asymptomatic, it does not need any treatment but if it is large causing compressive symptoms or if it extends in to the neck, it needs to be treated surgically.

### ▶ **Cyst under the tongue ( intraoral dermoid cyst)**

- Simran is 6 years old. Mother noticed since one month that her daughters tongue is projecting out a bit. When she examined simrans mouth, she noticed a white smooth rounded swelling under the tongue lifting the tongue up. She got panic. What is this swelling is it dangerous. Shae approached the doctor. Doctor examined and told her that it is dermoid cyst and needs to be removed by surgery.

The dermoid cysts are the result of developmental error. During developmental all our tissues are formed from three basic layers. Ectoderm, mesoderm and endoderm. During development if the ectodermal elements accidentally are entrapped in the below layers, it will lead to the development of dermoids . They occur usually in areas where embryonic parts will fuse together like midline of the body. They are slow growing lined with skin and filled with oil, hair follicles and old skin cells. 2-5 % of dermoid cysts will occur intraorally below the tongue. Until they reach significant size, they are not visible. If the cyst grows up, the tongue will be lifted up.

If the cyst grows down it projects through jaw. Usually they do not cause any pain. Infections also are rare in dermoid cysts. Malignant transformation can occur in some varieties of dermoid cysts. These dermoids have to be removed surgically.

### ▶ **Redness and ulceration in the lips and cheeks ( Recurrent aphthous stomatitis)**

- Ramesh is a 10 years old boy suffering with redness and small ulcers in the mouth once in 3 months. The parents are worried. The family physician told them it is aphthous stomatitis. What these ulcers are due to ?

Aphthous stomatitis is a common condition characterized by the repeated formation of non-contagious mouth ulcers (aphthae) in an otherwise healthy individual. The cause is not completely understood but involves a T cell-mediated immune response triggered by a variety of factors which may include nutritional deficiencies, local trauma, stress, hormonal influences, allergies, genetic predisposition, certain foods, dehydration, or some food additives. These ulcers occur periodically and heal completely between attacks. In the majority of cases, the individual ulcers last about 7–10 days, and ulceration episodes occur 3–6 times per year.

These ulcers may cause minor nuisance for feeding to severe debilitating symptoms with nutritional deficiencies. The condition is very common, affecting about 20% of the general population to some degree. Pain, which is often out of proportion to the extent of the ulceration and is worsened by physical contact, especially with certain foods and drinks. The onset is often during childhood or adolescence, and the condition usually lasts for several years before gradually disappearing. There is no cure, and treatments such as corticosteroids aim to manage pain, reduce healing time and reduce the frequency of episodes of ulceration.

## ▶ Ulceration at the angle of the lips (Angular cheilitis)

- Sarat is a 6 years old boy .he is found to have ulcers and redness in the angles of the mouth where the lips join .what are these ulcers ?

Redness and swollen patches in the angles of the lips are called Angular cheilitis. It is also called as perleche or angular stomatitis. It can occur on one side or both sides. There may be redness,swelling,bleeding, scaly, ulceration and cracks may be found. Lips may feel dry and uncomfortable. Fungal infection is the most common cause of angular cheilitis. It's usually caused by a type of yeast called candida, the same fungus that causes diaper rash in babies. Certain bacterial strains also can cause it. A deficiency in riboflavin (vitamin B2) may also lead to angular cheilitis. If we can't find the cause, it's called idiopathic angular cheilitis. It is more common in children with dentures, who lick their lips a lot, who produce more saliva,and in nutritionally deprived states. The goal is to clear out the infection and keep the area dry so your skin isn't infected again. Antibacterial or antifungal ointments are advised. Petrollium jelly creams are advised to protect the inflamed area from moisture.

## ▶ Infection in the floor of the mouth (ludwigs angina)

- 3 years old sujani developed swelling and redness in the mouth, followed by pain and fever. The swelling and redness has spread rapidly and has occupied the entire floor of the mouth. Later respiratory difficulty developed. Sujani was taken to hospital, the attending doctors wants to do emergency surgery. What is this condition? What is its significance? How dangerous it is?

This is called -Ludwigs Angina. It is the severe bacterial infection of the floor of the mouth.

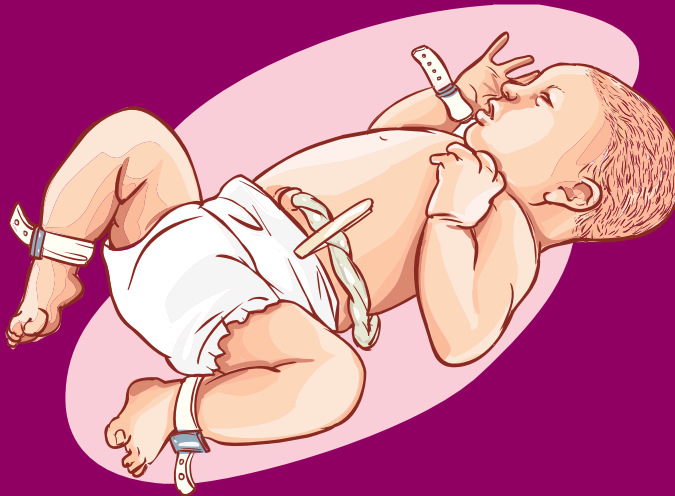
Later it spreads rapidly. Infection of the tooth and gums, injuries and lymph nodal infection will later leads to ludwigs angina. It is an emergency situation. The infection will raise the pressure deep to layers of the neck leading to the compression of airways leading to respiratory compromise. Clearing the airway, draining out excess fluids and controlling the infection are the three main goals of treatment. It needs immediate intervention by putting the child on ventilator or by doing emergency tracheostomy.

## ▶ Large Tongue ( Macroglossia)

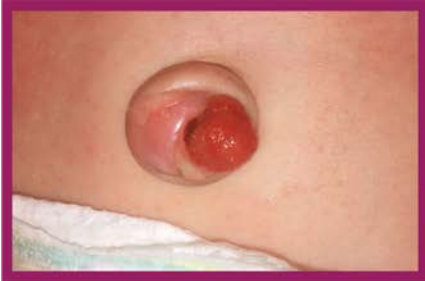- Prasad is 5 years old male child. After his tongue is gradually increasing in size and becoming thick. Small cysts are there on the tongue. Not able to eat spicy food. What is this condition and how will be the future of prasad ?

This condition is called – Lymphangioma of the tongue. This condition can affect a part of the tongue or the entire tongue. The cysts will be of various sizes. They may be superficial or deep. This condition is due to the abnormality of the development of the lymphatics. This lymphatic obstruction will lead to swelling of the tongue. This will lead to difficulty in taking food, difficulty in speaking and infection can occur. The enlarged tongue can be reduced by surgical technique ( Reduction Glassoplasty). Sclerosant injection can be tried in special situations.

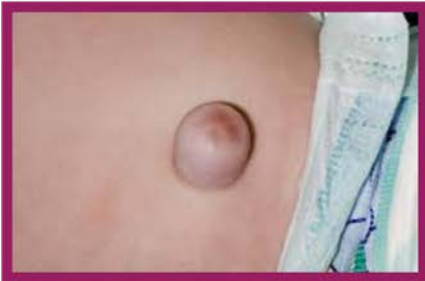



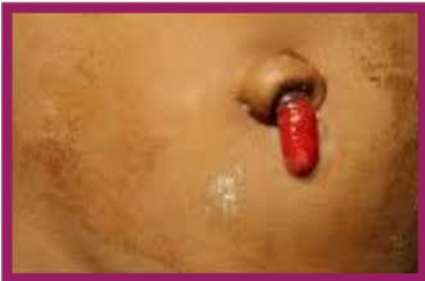## UMBILICAL LESIONS IN CHILDREN



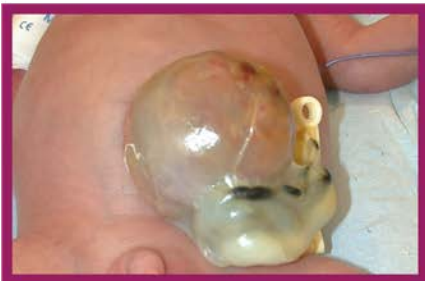**Umbilical Granuloma**



**Umbilical Hernia**



**Patent Vitello Intestinal Duct**



**Exomphalous**

Umbilical cord is the bond and complex lifeline between the developing baby and the mother. It gets separated and falls off after birth leaving only umbilicus as its remnant mark on the body. Umbilical cord is a wonder of all wonders, it forms temporarily to give nutrition to the baby from the mother and falls off once its purpose is over. Its mark remains lifelong on the body as umbilicus. After delivery, once he/she starts life on their own many problems can arise at umbilical site. It is always better to have awareness about these umbilical lesions. In adults problems at umbilical area are rare but in children if the umbilical area is wide, if the cord does not fall off and if secretions occur from the umbilical area, medical advice should be sought.

## ▶ Umbilical Cord

Once after the fertilization, the fertilized egg (Zygote) moves through the fallopian tube and reaches the uterine cavity. Then this zygote gets attached to the uterine wall for support and nutrition. This is the starting point of attachment between mother and developing baby. For 1-2 weeks it takes nutrients directly from uterine wall. But this is not sufficient for strength and nutrition for 9 months development. So within 4 weeks, the placenta and umbilical cord develops as a strong connection between mother and baby. By 7 weeks the umbilical cord is fully developed. All the blood and nutrients to the baby will come through umbilical cord only. This will continue till the baby is born and breathing on their own. After that it loses its importance.

Umbilical cord is about 50 cm in length. They are two arteries and one vein in umbilicus. They are wrapped by Wharton's jelly which is a soft jelly preventing injury to the vital structures in the umbilical cord. The arteries carry the deoxygenated blood from baby to the placenta where it gets purified (oxygenated). The pure blood comes back to baby through the umbilical vein. Placenta acts as a lung for oxygenation. Through this umbilical cord baby gets oxygen, glucose, electrolytes, minerals like calcium

and also immunity factors from the mother. The length of the umbilical cord depends on the activity and movement of the baby inside the womb. If the baby is more active then the umbilical cord length is more. Even if the baby moves no damage occurs to the umbilical structures due to the coiling of the umbilical cord.

## ▶ Umbilicus -an active part during baby development

During baby development, many changes take place rapidly at the umbilical area. It was a wide area initially. At one stage small intestinal loops from the abdomen will move out of the body into the umbilical area covered by a membrane. Later they will move back in to the abdomen, get accommodated and the muscles develop around umbilicus contracting it to a small depression.

Till the baby comes out of mother's womb completely and takes first breaths, the blood supply from the mother comes to baby through umbilical cord. 30-40 seconds after birth, the baby is kept at the mother's womb level and umbilical cord is cut in a sterile method. This disconnects the direct bond between mother and the baby. Later with contractions of the uterus, the placenta gets

extruded out. After the extrusion of placenta, the placenta and umbilical cord are examined carefully for any anomalies.

### ▶ Internal Connections

After the fall of the umbilical cord, only the umbilicus will remain as a remnant. The umbilical arteries, will get closed and persist for about 10 years as a cord like structure by the side of the bladder. The umbilical vein will get closed and persist as a fibrous cord in the lower part of membranes attached to the liver ( Falciform ligament). During development, blood vessels and nerves will develop around umbilicus, so the umbilicus will act as a central point. That is the reason for appearance of pain around umbilicus first, in any condition within abdomen. In tuberculosis, cancerous conditions and in liver diseases – secretions, blood may get discharged and blood vessels may get enlarged around umbilicus.

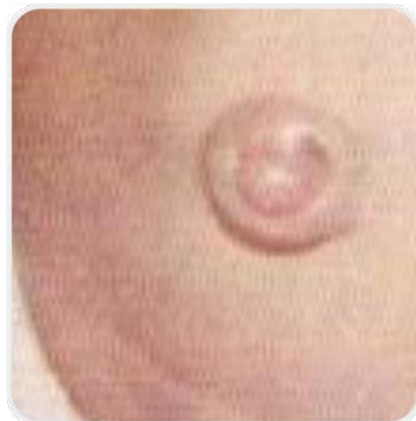### ▶ Problems that can occur at umbilical area.

- **Bleeding from the umbilicus**

Bleeding from umbilicus is a common complaint it may be due to improper clamping or tying of the umbilical stump. It should be properly tied with a ligature. If the bleeding is a manifestation of the bleeding mechanism, vit K injection will help in controlling the bleeding.

- **Umbilical granuloma**

After the separation of the umbilical cord, if there is infection at the umbilical stump, it will lead to exuberant growth of granulation tissue. It is called umbilical granuloma. It looks red and oozes blood on touch. It is controlled with application of salt ( which acts with hygroscopic action and produces dehydration in the granuloma) or with silver nitrate or copper sulfate application. These material will cauterize the granuloma and prevents its growth.



- **Umbilical sepsis**

Umbilical sepsis is usually due to infection acquired at the time of delivery, due to not maintaining the asepsis during cutting of the umbilicus. The infection causes redness and swelling around the umbilicus and if the infection spreads below it will lead to spread of the infection to the liver and it produces changes in the liver blood vessels in the long run ( Portal Hypertension). So, all cases of umbilicus sepsis should be treated aggressively. Initial treatment is with broad spectrum antibiotics, keep the umbilical area dry and if the infection is deeper and it is turned in to abscess, it has to be drained.

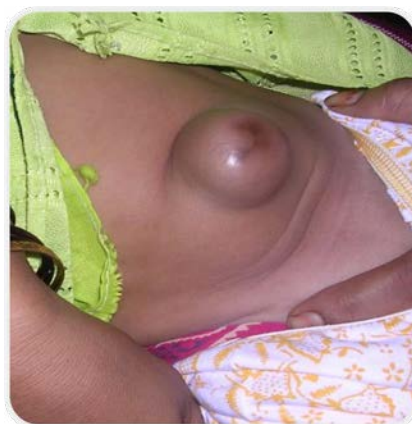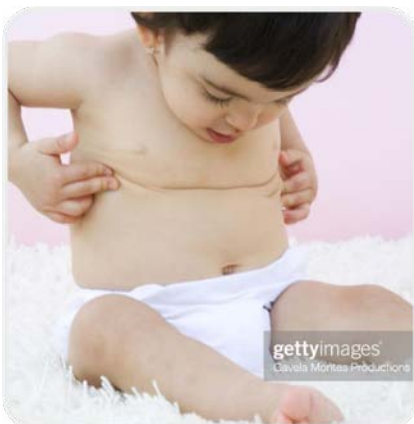- **Umbilical hernia**

If the umbilical area is weak due to the improper closure of the umbilical ring formed by the rectus muscles, the loops of small bowel may get herniated out covered by skin. This will be seen whenever the child is straining or crying. The chance of obstruction of herniated bowel are less in umbilical hernia due to the size of the defect. There is a chance that the umbilical area may get closed due to the muscle growth with age. So,

umbilical hernia can be safely observed till the age of 4 years. It will be corrected surgically only if it persists beyond 4 years of age, if it get obstructed or if its defect size is more than 2cm. umbilicoplasty is the surgical procedure done for umbilical hernia, in which umbilical defect is closed and umbilicus is created to near normal level.

- **Urine coming from umbilicus ( Patent urachus)**

The urachus is a tube between the bladder and the umbilicus that is present before birth. In most cases, it closes along its full length before the baby is born. In a patent urachus, there is an opening between the bladder and the umbilicus (navel) in its entire length. It occurs because of the failure of involution of this connection. In this condition urine comes from the umbilical area. This urinary seepage will produce smell and rash over the anterior abdominal wall. The ultrasonogram of the abdomen showed hypoechoic bands extending from the bladder dome to the umbilicus, suggestive of a patent urachus anomaly. Diagnosis of patent urachus can be made by the patient's presentation, a



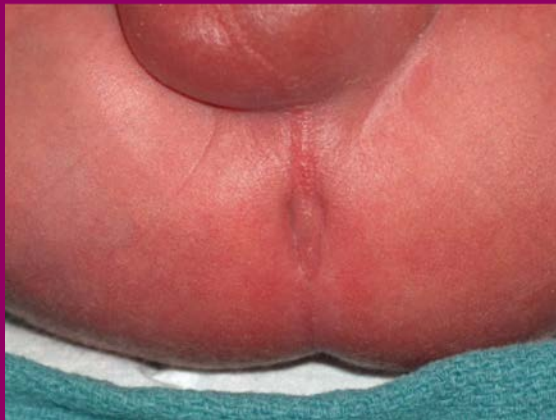physical examination findings, and the ultrasonography findings. patent urachus can be corrected surgically by complete excision with repair of the bladder dome. This can be done by open method or by laparoscopic method.

- **Fecal matter coming from umbilicus ( Patent vitellointestinal duct)**

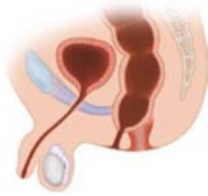During development, the source for the development of intestines will be around the umbilicus ( yolk sac) . later there will be a connection between the umbilicus and the small intestine called vitellointestinal duct ( VID). This tubular communication will be closed between 5-9 week of fetal development.. If the vitellointestinal duct is open throughout its entire length even after birth, it will lead to a situation where the fecal matter will come from the umbilicus. The diagnosis is obvious as the fecal discharge indicates the patent VID. It should be corrected by surgery.

- **Born with intestines outside (exomphalos)**

During development of bowel, there is a stage where the small intestine will form and develop outside the body. they will herniate outside in to the umbilicus covered by a membrane. This is called stage of physiological herniation. Later the bowel will return back in to the abdomen to get fixed in its permanent position. If the intestine fails to return back into abdomen and stays outside the abdomen through a defect at umbilical area it is called exomphalos. Most of the small bowel and sometimes part of the liver will be at umbilical area outside the body covered by a thin, transparent membrane. This needs to be corrected by surgical correction. In surgery, the bowels are accommodated in the abdomen and the umbilical defect is closed.



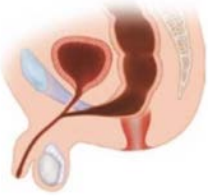## **ANO-RECTAL MALFORMATIONS IN CHILDREN**



Male perineal fistula

### Male - Perineal Fistula

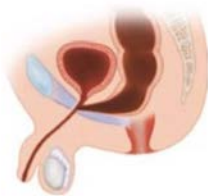---



Recto-bulbar fistula

### Male - Recto Bulbar Fistula

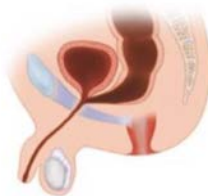---



Recto-prostatic fistula

### Male - Recto Prostatic Fistula

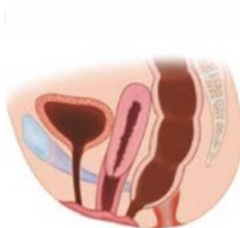---



Recto-bladder neck fistula

### Male - Recto Vesical Fistula

---



Vestibular fistula

### Female - Vestibular Fistula



## ANO-RECTAL MALFORMATIONS IN CHILDREN

Anorectal malformations otherwise called imperforate anus are wide spectrum of defects in the development of the lower distal portion of the intestinal tract. These children will be born with absence of normally developed and normally placed anal orifice. Occurs in 1 in 5000 live births. Slightly more common in males. The exact cause of the anorectal malformations is not known. Most of the anorectal malformations do not have a family history of this type of defects. Normally during a bowel movement, stool passes from the large intestine to the rectum and then to the anus. Muscles in the anal area help to control when you have a bowel movement. Nerves in the area help the muscles sense the need for a bowel movement. The nerves also stimulate muscle activity.

The severity of these anomalies, can range from mild to complex anomalies. These may include several abnormalities ...

@ Rectum (lower end of intestinal tract) may not reach the skin and forms the anus. (anorectal malformation without fistula)

@ Rectum may not reach the skin, at the same time connected by an abnormal fistulous connection to the urinary or genital tract. ((ano-rectal malformation with urinary / genital fistula)

@ Anal passage may be at abnormal location and narrow (Perineal fistula)

@ Anal orifice may be covered by a membrane (Bucket handle deformity / covered anus)

@ all three systems -rectum, genitalia or urinary will be fused and form a common channel and opens on to skin through a single opening (Cloacal Malformation)

These various types of anomalies can present as ...

- If the anal passage is narrow, baby may have a difficult time passing a stool, causing constipation and possibly discomfort.
- If there is a membrane over the anal opening, baby may be unable to have a bowel movement.

- If the rectum is not connected to the anus but there is a fistula present, stool will leave the baby's body through the fistula and enter the urinary tract instead of the anus. This can cause urinary infection. stool coming through urethra
- If the rectum is not connected to the anus but there is a fistula present, stool will leave the baby's body through the fistula and enter the vagina or vestibule in the female genitalia, instead of the anus. This can cause stool coming through genitalia.
- If the rectum is not connected to the anus and ends blindly without fistula, there is no way for the stool to leave the intestine. Then, baby will be unable to have a bowel movement and will have a blockage of the intestine presents as a newborn emergency after birth.

### ▶ Why ano-rectal malformations occur ?

the cause for an anorectal malformation is unknown, but in rare cases, it appears to run in families. Boys are at a slightly higher risk for this abnormality than girls. Certain steps have to take place in the **seventh to tenth weeks of gestation** for the rectum and anus to separate from the urinary tract and form

properly. Sometimes these steps do not occur as they should, and the rectum, anus or both may not develop normally.

The lower part of the large intestine and the urinary tract start off as one from hind gut. Certain steps must happen in the first 3 months of pregnancy or gestation. These steps are needed for the rectum and anus to break away from the urinary tract and form properly. Sometimes these steps don't happen as they should. Then the rectum or anus may not develop normally. The early embryo is like a two layered disc. On both sides, it is covered by fluid filled sacs called amniotic sac on back side and yolk sac on front side. The yolk sac is slowly drawn in to the developing embryo and forms the future gastrointestinal tract. The developing gastrointestinal tract is divided in to three parts – foregut, Midgut and Hindgut. Both the ends of the tube are covered by membranes called Buccopharyngeal membrane at mouth end and Cloacal membrane at the anal end. The Cloacal membrane later divides in to two parts. The defective development of the back portion of the cloacal membrane which is covering the hindgut, leads to the development of Anorectal malformations.

## Types of anorectal malformations

Each type of anorectal malformations have unique characteristics. ARM affects each child differently. Most common types of ARM are..

In boys

### **Perineal fistula**

In this anomaly babies do not have normally formed anus at normal site. Rectum ends with a fistulous opening in the area between the scrotum and anal sphincter area, in front of the area where anus should normally present. In this type of anomaly the muscle

surrounding the rectum are well developed and they achieve good control over stools after surgery.

### **Rectobulbar fistula (in boys) :**

In this anomaly in boys, the rectum and anal canal ends blindly at a moderate distance from skin level, and the distal end of the bowel opens as a narrow fistulous opening in to mid part of the male urethra. The surrounding voluntary bowel movement controlling muscles and bowel supplying nerves are reasonably well developed and these patients will have good bowel movement control after surgical correction.

### **Rectoprostatic fistula (in boys)**

In this anomaly in boys, the rectum and anal canal ends blindly at a high distance from skin level, and the distal end of the bowel opens as a narrow fistula high in the male urethra. The surrounding voluntary bowel movement controlling muscles and bowel supplying nerves are not well developed and these patients will have compromised bowel movement control after surgical correction.

### **Rectovesical fistula (in boys)**

In this anomaly in boys, the rectum and anal canal ends blindly at a very high distance from skin level, and the distal end of the bowel opens as a narrow fistula very high in to the base of the urinary bladder. The surrounding voluntary bowel movement controlling muscles and bowel supplying nerves are not well developed and these patients will have compromised bowel movement control after surgical correction.

### **Anorectal malformation without fistula (in boys & girls)**

In this anomaly which can occur in boys & girls, the rectum and anal canal ends blindly at a variable distance from skin level, and the distal end of the bowel ends blindly, do not open either on to skin/ urinary system or genitalia.. The surrounding voluntary bowel

movement controlling muscles and bowel supplying nerves are well developed and these patients will have reasonably good bowel movement control after surgical correction.

### **Rectovaginal fistula**

In this anomaly in girls, the rectum and anal canal ends blindly at a moderate distance from skin level, and the distal end of the bowel opens as a narrow fistula into the vagina. The surrounding voluntary bowel movement controlling muscles and bowel supplying nerves are moderately developed and these patients will have reasonably good bowel movement control after surgical correction.

### **Rectovestibular fistula**

In this anomaly in girls, the rectum and anal canal ends blindly from a short distance from the skin level, and the distal end of the bowel opens as a narrow fistulous opening into genital coverings. The surrounding voluntary bowel movement controlling muscles and bowel supplying nerves are well developed and these patients will have good bowel movement control after surgical correction.

### **persistent cloaca**

In this anomaly in girls, called cloacal malformation which is one of the complex anomalies, the rectum and anal canal, vagina and urethra all will join and form a common channel before opening on to the skin as a single opening at the genital area. The surrounding voluntary bowel movement controlling muscles and bowel supplying nerves are not well developed in these cases and these patients will have compromised bowel movement control after surgical correction.

### **▶ Associated anomalies**

50% of the babies with anorectal malformations will have associated anomalies. Sometimes

they are described as VACTERL anomalies. It stands for vertebral, anorectal, cardiac, trachea-esophageal, renal and limb anomalies. It is important for children with these associated anomalies to receive care from a multidisciplinary team of experts.

### **▶ Diagnosis of Anorectal anomalies**

Some babies are suspected to have anorectal malformation on prenatal ultrasound. Such babies should be delivered at special Maternal-Fetal medicine centers.

Most of the cases are diagnosed just after birth by clinical examination of the perineum by the attending pediatrician. Often the doctor notices that the child's anus is not present or is in a wrong place.

Later more tests are needed to understand the type of ARM and to plan the surgery.

**Abdominal Xrays (invertogram / prone cross-table lateral film)** provides an overview of location of bowel and type of malformation. Defects of the spine and tailbone (sacrum) can also be detected. Prone cross table lateral xray is taken by placing the baby in prone position with rolled cloth kept under chest and hip region with hip slightly raised. Xrays were taken from the side. The extent of gas in the blind rectum is taken in relation to pelvic bones. This xray is taken 18-24 hours after birth. By this Xrays, the level and type of the anomalies can be assessed with accuracy.

- **Kidney Ultrasound** : associated anomalies of the kidney, ureter bladder can be detected.
- **Pelvic Ultrasound** : associated anomalies of reproductive organs in girls can be detected.
- **Spinal Ultrasound** : detects tethered spinal cord or any presacral mass.
- **Echocardiogram** : to detect heart defects
- **MRI spine** : to detect tethered spinal cord or spinal vertebral anomalies.

## ▶ Treatment of Anorectal anomalies

Treatment plan is based on type of Anorectal malformation baby is having, presence & type of associated anomalies and overall health condition. Each child with anorectal malformation will have unique needs. When a malformation affects the development of rectum and anus, the muscle and nerves associated with the anus will have a similar degree of malformation. The associated spinal and urogenital anomalies will make the situation further complicated. The more important is the development of muscle of continence – levator ani muscle. The main aim of surgical correction is to create an anal orifice which is cosmetically good looking & functionally continent.

In case of **low anomalies**, anus is created in a single stage procedure called -Perineal anoplasty. In these anomalies the bowel ends closer to perineal skin and the surrounding muscles and nerves are well developed. So gaining bowel control (continence) is good after surgical correction.

- In case of **high anomalies**, where the bowel ends at a higher level either blindly or with a fistulous communication, the surgical correction needs to be done in two or three stages. Initially as a life saving procedure called colostomy was done and after 3-6 months a pull through procedure was done. **Colostomy.** With a colostomy, the large intestine is divided into 2 sections. The ends of the intestine are brought through openings in the skin. The upper section lets stool pass through the opening (stoma) and into a collection bag. The lower section lets the mucus made by the intestine, pass into a collection bag. A colostomy does not damage child's digestion. Child can also grow before the next surgery is needed. And when the next surgery is done on the lower section of the intestine, there won't be any stool there to infect the

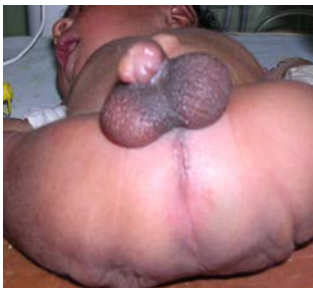area. The nursing staff can help to learn to take care of the colostomy.

- **Attaching the rectum to the anus.** . After 3-6 months a definitive procedure was done through midline back called posterior sagittal anorectoplasty. In this procedure, the midline back is opened like an open book, exactly in the midline to avoid injury to the muscles and the blind ending distal bowel is identified, mobilized after disconnecting the fistulous communication and brought through the sphincter muscle complex to the normal anal site. It can be done by open/ laparoscopic assisted methods. The important advantage of this procedure is surgery can be done under vision, the mobilized bowel can be placed exactly in the middle of the muscle complex. The colostomy will stay in place for a few months after this surgery. This is so the area can heal without being infected by stool. The rectum and anus are now joined. But stool will leave the body through the colostomy until they are closed with surgery. 3 weeks after surgery, the daily anal dilation programme has to be initiated.
- **Closing the colostomy.** This surgery is done about 2 to 3 months after the pull through procedure. After the surgery, child will start passing stools through the rectum. At first, stools will pass often, and they will be loose. Diaper rash and skin irritation can be a problem at this stage. A few months after the surgery, the stools happen less often and are more solid.

Following the correction of the anorectal anomalies, the created new anus (anoplasty), has to be calibrated or dilated daily starting from 3rd post operative week to 6 months. This will prevent the postoperative anal stenosis.

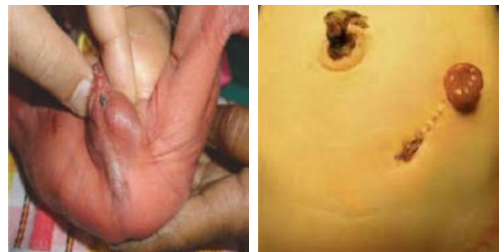## ▶ Toilet Training

Children with ARM, may gain bowel control, more slowly than normal children. In complex anomalies and in cases where the bowel ends high – bowel control is more affected and 50% of them will have socially unacceptable incontinence. Toilet training should be started around 3-4 yrs in children with ARM (like in normal children). If the child is not in normal underwear, when other children of his age are, the attending surgical care team may suggest a Bowel management programme (BMP). The aim of the Bowel management programme is to help children to achieve social continence through the use of laxatives /enemas /or special diet.



## ▶ Longterm outlook

Children with less complex anomalies (low malformations) are often able to gain good control over their bowel movements after the surgical repair. Those with more complex anomalies, may need to take part in a bowel management programme, to prevent constipation or incontinence and to gain acceptable social continence. Longterm follow up care for children with ARM, may include a team work plan tailored to the child's individual situation. In those cases where the anomaly is complex or in anomalies where the bowel is ending very high with poor muscle development, or in those in whom Bowel Management Fails, they develop severe incontinence for stools. Such cases may need various types of surgical procedures like antegrade colonic enema (ACE procedure), Muscle transposition procedures to strengthen the control mechanism or artificial sphincters placement.



### Key Points :

Anorectal malformations are birth defects. The anus and rectum do not develop properly.

An anorectal malformation causes problems with how a child has a bowel movement.

Most babies with this problem will need surgery to correct it.

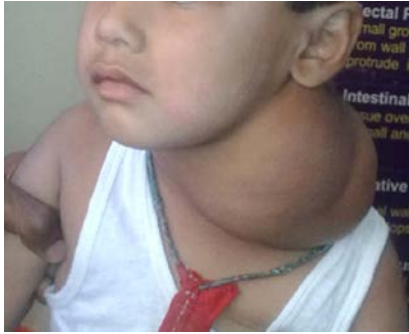Depending on the type of malformation, a child may have good control of bowel movements after the problem is repaired.

If a child can't control their bowel movements, a bowel management program can be very helpful.

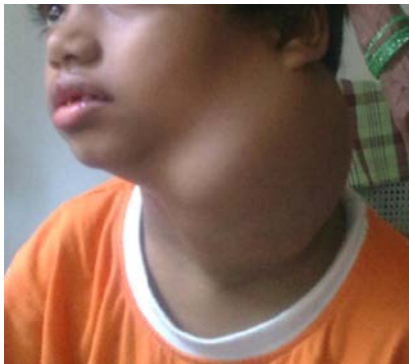



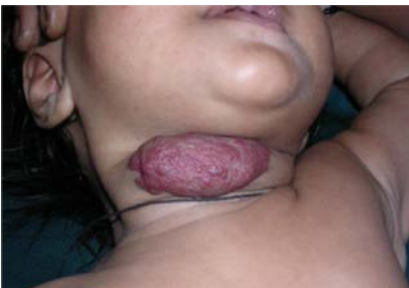## NECK LESIONS IN CHILDREN



**Cystic Hygroma**



**Lymphoma**



**Cervical Hemangioma**



Developmentally the size and length of neck varies from species to species in nature. Fishes have no neck. Zirafees have a long neck. Humans have got a moderate sized neck. Human Neck is one of the beauty area in the body. At the same time it connects the head with the body. Through the neck – the airway, foodpipe and major bloodvessels and nerves will get transmitted. So it is a vital link to the body. It is delicate, at the same time, it has got a wider movement capacity to make us to see our surroundings. So, neck is cosmetically and functionally an important area in the body. Such an important neck –if it becomes the site of pathology in children –the parents will get panic. Neck lesions can occur in any age of life but commonly seen in children. The differential diagnosis is wide. This article is to clarify the parents apprehensions, when their childrens neck is affected.



### ▶ Interesting Facts About Neck Development.

Neck development involves a complex process which occurs between 3rd to 8th weeks of human embryo development. Before 3rd embryonic week, there is no neck. Only head followed by heart bulge. In 3rd embryological week, two important events occur. The membrane (buccopharyngeal) covering the mouth area ruptures leading to formation of mouth. Second event is the developing foregut (pharynx) is surrounded by 6 pairs of thickenings in the wall they are called - pharyngeal arches. The 5th arch is small and disappears fast –leaving only 5 arches. these arches looks like gills of a fish. Each arch contains components which can give rise to artery, nerve, muscular and cartilageous structures which gives rise to all the structures of the neck and lower part of the face. So neck basically develops from –five pairs of pharyngeal arches–like gills of a fish (thickenings in the wall) during development.

### ▶ Congenital Neck Lesions

#### CYSTIC HYGROMA (lateral neck mass)

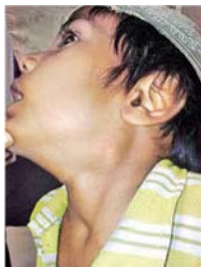These lesions will result from –Malformation during development of the lymphatic system. It occurs as a result of separation of a bit of lymphatic tissue from the mainstream during development and grows independently without controle, without boundries and without communication with the main lymphatic stream. Incidence is 1 in 4000 to 1 in 6000 live births. As the lymphatic system spreads throughout our body – lymphangiomas can occur anywhere in the body. Most common presentation is soft mass in lateral part of neck. But it can occur anywhere in the neck and grow to any size. Massive cystic hygromas can create trouble during delivery. They are typically lobulated. If light is passed through the lesion, it will transmit it brilliantly, as it contains clear lymph fluid.

These are innocent lesions. But if they can grow to massive sizes. they grow through the space inbetween the vital visceral and neurovascular structures in the neck. they can give rise to symptoms like airwar obstruction or food pipe obstruction. Infection and hemorrhage are the two complications of

lymphangiomas. Approximately 70% will present at birth. Foetal cystic hygromas are detected on antenatal ultrasound. Rarely a large lesion may cause obstructed labour. Surgical excision is the mainstay of treatment. The excision should be a complete, otherwise chances of recurrence is high. If they are inaccessible, or if there is recurrence then sclerotherapy is advised.

### Branchial Arch Anomalies (Lateral Neck Lesion)

The neck develops from 5 branchial arches, which are thickenings on the wall of the pharynx during development of upper part of gastrointestinal tract.. these arches gives rise to all the structures of



the lower part of the face and neck. After that these arches will disappear. If any component of these arches persist beyond their usual period they can give rise to branchial arch anomalies.. The congenital anomalies of 2nd branchial arch are more common than other arches (90% of the anomalies). The congenital anomalies that can arise from branchial arches –includes cysts, sinuses, fistulas or cartilaginous remnants presenting as skin tags. These skin tags are seen around the ears. The 2nd arch anomalies present, close to anterior border of sternocleidomastoid muscle. The branchial cyst is a painless cystic swelling in relation to upper third of sternocleidomastoid muscle. 1st arch anomalies may present in the upper part of the neck or like parotid salivary gland sinuses or fistulas.

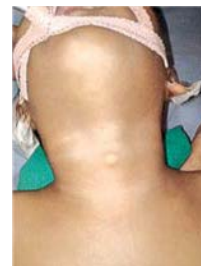Branchial sinuses and fistulas are mostly seen during the first decade of life. Branchial cysts will present during 2nd decade of life. Sinuses and fistulas are present at lower third of sternomastoid muscle (side muscle of the neck),but branchial cysts will present in the

upper third of the sternomastoid muscle border. The branchial fistulas can be bilateral. They present as a small, discharging opening in the lower third of edge of sternomastoid muscle. The discharge can be watery, mucous or purulent(if it is infected). The persistent discharge in the lower part of the neck through a small opening draws the attention of the parents. Sometimes these branchial fistulas will get infected leading to a inflamed swelling in the lower part of the neck.

The main treatment of branchial arch remnants is surgical excision. It is done as an elective procedure. the entire branchial fistula track from neck to its origin site at tonsillar fossa should be excised. If any bit of track is left behind it will lead to recurrence of the branchial fistula. This procedure can be done electively any time after 3 months of age of the child.

### Thyroglossal Cyst (Midline Neck Mass)

It is the second most common midline mass encountered in neck in children. The thyroid gland, during its development descends from the base of the tongue in to the neck. during its descent it



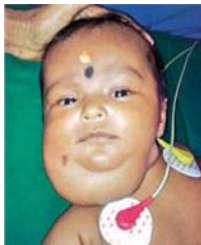is attached to the tongue by a thin tubular attachment called thyroglossal duct. After the descent of thyroid, the thyroglossal duct will disappear. If any remanant of TG duct remains, it will leads to the development of thyroglossal duct cyst. This cyst is attached above to the base of the tongue. That's why the cyst moves with swallowing and protrusion of the tongue. These cysts are usually of 5 -8cm in size, do not grow to large size.

Usually seen in the first 5years of life, but it can occur at any age. Usually presents as a small cystic swelling in the midline of neck at

the level of hyoid bone. There wont be any external openings to the cyst. It is a painless cyst unless it gets infected. Surgical excision is the treatment of choice Thyroid nuclear scan is done to confirm the presence of normal thyroid before the surgical excision the cyst.. During surgery – the cyst, its duct upto the base of the tongue and part of hyoid bone are removed together (**SISTRUNKS** operation).

### **Sternomastoid Tumor (Lateral Neck Mass)**

It is a fibrotic lesion of sternomastoid muscle (lateral muscle of the neck). This condition appears 2-4 weeks after birth. It presents as a pear shaped firm mass in the middle or lower third of sternomastoid muscle. Common on right side. It is associated with head bend on ipsilateral side and turning of chin to the opposite side (torticollis) with restricted neck movements. Exact etiology is not known. Thought to be due to traumatic delivery with hematoma formation in sternocleidomastoid muscle, which was later replaced by fibrosis. The mainstay of treatment for this condition is conservative- active and passive neck excercises (neck stretching) will resolve the lesion. If the tumor persists beyond 1yr, or if there is poor development of one half of the face, then surgical intervention is needed.



They may present as flat, slightly raised, asymptomatic, dark red lesions over neck. They feel warm to touch. They are not compressible but blanch on pressure (capillary hemangiomas). Some of them are more bulky, raised from the surface and are compressible. It gives a bluish colour through the skin (cavernous hemangiomas). Most of the hemangiomas will regress spontaneously. They will grow along with the child till 2years of age,then they remain static till 5years of age, starts regressing from 5 to 7 years. spontaneous regression will give good results. If the hemangioma is growing very rapidly, or if it is causing functional problem, or undergoing repeated ulceration and bleeding- then they need to be treated. Treatment options include propranalol therapy, sclerosant injection or surgical excision.

### **▶ Cervical Dermoid Cyst**

Dermoid cyst is a collection of tissue under the skin. they contain hair, teeth,oily material & sweat glands. Dermoid cysts can appear at birth or soon after. Dermoid cysts can occur anywhere in the body. They can occur in the neck also. They present as a small, cystic swelling in the midline of the neck around hyoid bone. Surgical excision is the treatment of choice.

### **▶ Cervical Teratoma.**

Teratomas are tumours arising from all 3 embryological layers. It can account for 3% of all teratomas occurring in the body. It presents as a large midline swelling in the neck in newborn. It is a firm swelling and nontender. Calcifications are seen on neck xray. Ultrasound is the main investigation antenatally and postnatally. Prompt surgical excision is the treatment of choice.

### **▶ Cervical Hemangioma**

These are congenital malformations which occur commonly over face and neck. These represent congenital excess of angioblastic tissue which fails to link up with normal circulatory system. They mostly develop a few weeks after birth and then grow progressively with the growth of the child.

## ▶ Acquired Neck Lesions

**LYMPHNODAL ENLARGEMENT** masses arising from cervical lymph nodes are by far the most common lesions of this region in infancy and childhood.

### 1. ACUTE SUPPURATIVE LYMPHADENOPATHY

It is very common in children. examination reveals –an enlarging lymphnode which is inflamed, tender, fluctuant accompanied by fever. Lymphadenopathy if it is due to viral fever, it is generally of shorter duration and have a self limiting course. Where as bacterial acute lymphadenitis is characterised by erythema, swelling and tenderness with gradual and persistent (3-4 weeks) enlargement. Most common offending organisms are group A beta hemolytic streptococci and staphylococcus aureus. Enlarging nodes usually respond to antibiotic course. however if the nodes continues to enlarge, they need incision and drainage or excision.

### 2. SUBACUTE (REACTIVE) CERVICAL LYMPHADENOPATHY

Non-suppurative lymphadenopathy may represent the response of the cervical nodes to a viral infection, either local or systemic.. It may also be caused by reactive hyperplasia due to parasitic infestation. These nodes are firm, discrete and painless. Treatment is mostly medical.

### 3. TUBERCULOUS (MYCOBACTERIAL) CERVICAL ADENITIS

Lymph nodal enlargement can be caused by either – typical mycobacterium tuberculosis or atypical mycobacteria. In typical TB lymphadenitis, the gland enlargement is associated with systemic symptoms like evening rise of

temperature, loss of weight and loss of appetite. Associated findings like abnormal chest xray, positive mantoux test and positive family history will support the diagnosis of tuberculosis. The TB lymphnodes are matted (adhere together) and slowly gets necrosed (caeseation). This leads to sinus formation at the affected nodes area.

### 4. HODGKINS LYMPHOMA

Hodgkins lymphoma is the cancer that starts in the lymphatic system. Lymphatic system helps the bodys immune system to get rid of waste and fight infections. Hodgkins disease starts in white blood cells called lymphocytes which normally fights the germs. In hodgkins disease, these cells grow abnormally and spread beyond the lymphatic system. Hodgkins lymphoma starts when an infection fighting cell called- B cell develops a mutation in its DNA. This mutation causes oversized, abnormal B-cells to accumulate in the lymphatic system, where they crowd out healthy cells and cause signs and symptoms of hodgkins lymphoma.

As the lymphoma progresses,it compromises the bodys ability to fight infection. Hodgkins Disease can affect at any age but most common age group is -15 years to 40years and second peak after 55 years. Exact etiology for the disease is not known but it is linked to cell mutations and Epstein –Barr virus infection. most common symptom of hodgkins lymphoma is painless enlargement of cervical lymphnodes. (other areas are armpits and groin). It is present in 80-90% of hodgkins lymphoma cases. Lymphnodes are swollen, painless and feel rubbery. Unexplained weight loss, fever,fatigue and itchy skin are other symptoms. For diagnosing lymphoma, certain tests are required like- complete

blood picture, Xray chest, lymphnode biopsy and bone marrow test. Once the Hodgkins lymphoma is confirmed – Staging is done to assign extent and severity of the disease. The treatment options depend on stage of lymphoma. Treatment includes – chemotherapy and Radiotherapy.

## 5. NON-HODGKINS LYMPHOMA

It is more common than Hodgkins lymphoma. It also arises in lymphatic system and from lymphocytes. Normally old lymphocytes die and body produces new ones to replace them. But in lymphoma, the abnormal lymphocytes do not die but continue to grow and divide. This oversupply will flood the lymph nodes and make them to swell. There are 2 types of lymphocytes – B cells and T cells. Non-Hodgkins lymphoma arises mostly in B lymphocyte cells. The disease can involve lymphatic system or organs outside lymphatic system also. The presentation is same as Hodgkins lymphoma – like enlarged, painless lymph nodes in the neck, fever, fatigue, loss of appetite and loss of weight. Treatment options depend on type of cell and stage of the disease. It involves chemotherapy and radiotherapy.

### ▶ Thyroid Swellings

Thyroid gland is located at the front of the neck. Thyroid gland is essential for life, growth and development. Thyroid hormone action is responsible for all metabolic and chemical processes in our body and affects every cell, tissues or organ in our body. Thyroid gland may get enlarged in children – due to inflammation, congenital or due to simple goiter. Rarely enlargement may be due to neoplastic (cancerous) lesions. The thyroid disorders either produce – less hormone (hypothyroidism) or more thyroid hormone (hyperthyroidism).

The most common cause for enlargement of thyroid in children is Hashimoto's thyroiditis. It is more common in girls. It is an auto-immune disease. In this condition, the body's own immune system attacks the thyroid and interferes with its hormone production. Treatment option is thyroid hormone replacement for life. Other causes of thyroid enlargement include – congenital goiter or simple physiological goiter.

### ▶ Ludwig's Angina

Any infective process in the neck can lead to Ludwig's angina. Acute submandibular infection and swelling extends under the deep fascia to the floor of the mouth. The swelling and collection under deep fascia will compress the vital structures in the neck. Pus collects under the tongue, pushing it upwards and backwards, which can cause breathing and swallowing problems. It is a medical emergency needing early tension releasing incisions and drainage. If not intervened early it will lead to septicemia and respiratory obstruction.

### ▶ Plunging Ranula

Ranula is a bluish swelling in the floor of the mouth. Occasionally it extends in to the neck. Ranula is a mucous retention cyst or mucous extravasation pseudocyst arising from obstructed sublingual salivary gland. It occurs due to the obstruction or traumatic rupture of the sublingual gland. This leads due to extravasation of mucus and formation of pseudocyst. This collection extends down through the dehiscence in mylohyoid muscle leading to plunging ranula in the paramedian or lateral part of the neck with or without oral cavity lesion.

Aspiration of cyst fluid will always reveal high protein content and salivary amylase. CT or MRI will demonstrate a unilocular cystic swelling arising from sublingual space.

extending in to submandibular and submental space.. Surgical excision in continuity with the sublingual gland of origin is the treatment of choice. Marsupialisation (deroofting of cyst)is the other option, with this recurrence rate is high

## ▶ Neck Abscesses

A neck abscess is a localized collection of pus, between the structures of the neck. A neck abscess occurs during or immediately after a viral or bacterial infection in the head and neck such as –cold, tonsillitis, there are several types of abscesses in the neck like-

### **Retro -pharyngeal abscess, -**

formation of abscess behind the pharynx. most common in younger children. Follows

upper respiratory infection. Lymphnodes get infected-bursts giving rise to pus collection behind pharynx.

### **Peritonsillar abscess(quinsy abscess)**

more common in adolescents and young adults, rarely seen in children. Abscess forms in the tissues, adjacent to tonsils.

### **Submandibular abscess (ludwigs angina)**

Collection of inflammatory edema and pus in the floor of the mouth, which lifts the tongue upwards and backwards –leading to airway and foodpipe obstruction. It needs immediate releasing incisions to relieve the pressure and drainage of pus.

## Key Points :

in children most of the neck lesions are benign (non dangerous). But it is important to rule out rare malignant (cancerous) lesions.

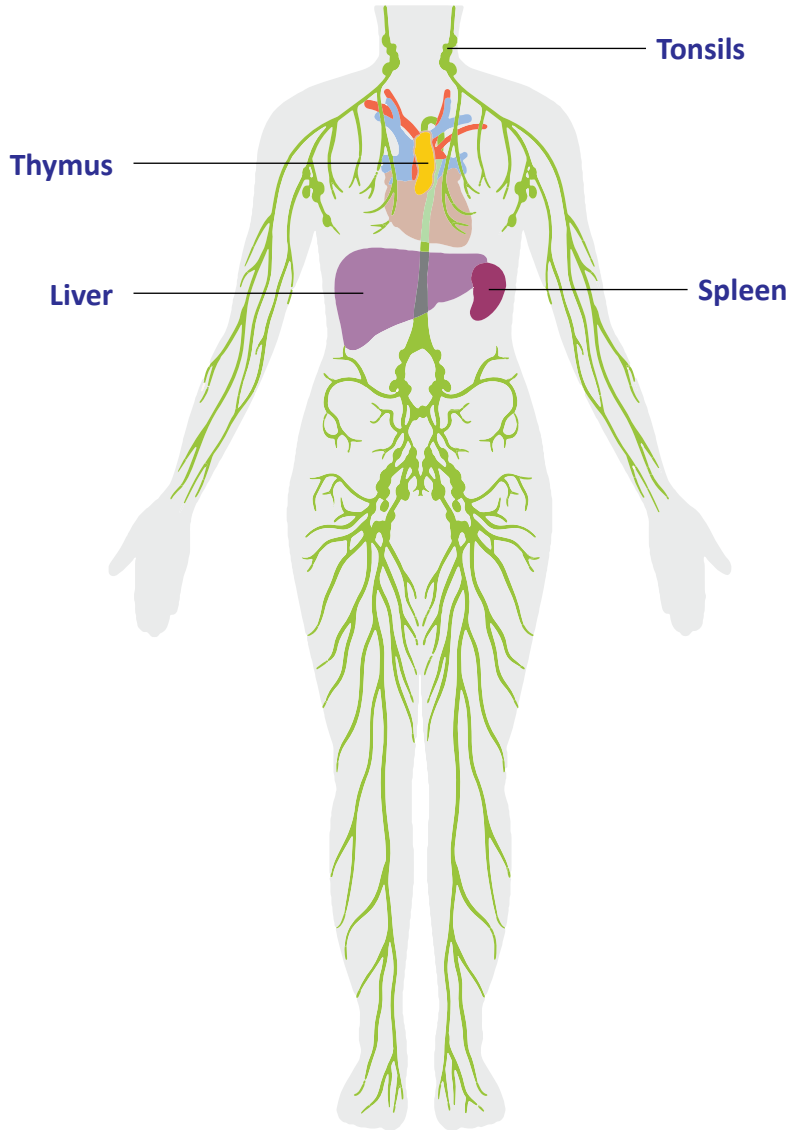
The lesions which are present since birth, or develops within a few weeks, presenting with recurrent discharge or intermittent swelling are usually congenital.

Swellings appear later in growth period, which are gradually increasing in size and presents with pain or inflammation are usually acquired.



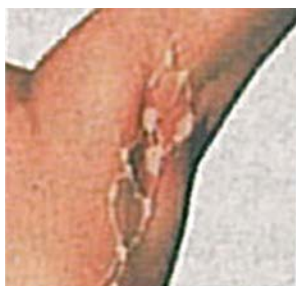## LYMPH NODES SWELLING IN CHILDREN

## Body Lymphatic System Distribution

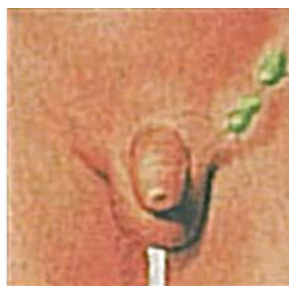



We know that our body is made up of blood vessels, nerves and muscles. But little is known about other system which is spread throughout our body. It is called the lymphatic system. Nodal enlargement is the symptom of this lymphatic system. Lymphadenopathy means swelling of the lymph nodes or glands. These are the bean-shaped glands in the neck, armpits, groin, chest, and abdomen. These glands act as filters for lymphatic fluid. This fluid contains white blood cells (lymphocytes) that help the body fight infection. Lymphadenopathy can occur in just one area of the body, such as the neck. Or it may affect lymph nodes throughout the body. The cervical lymph nodes, found in the neck, are the most common site of lymphadenopathy. Nearly all children will get lymphadenopathy at some time. That is because enlarged glands often occur with viral or bacterial infections like colds, the flu, or sore throat.



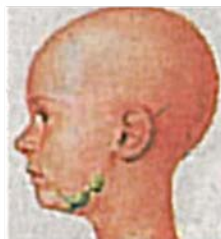Axillary  
Lymphnodes



Inguinal  
Lymphnodes

### ▶ Lymphatic system is an amazing structure

Looking just like blood vessels another system will present in the body called lymphatic system. It spreads throughout the body. The lymphatic system is part of the immune system. The immune system fights the infection and other disease. Cells and fluid build up in the lymph nodes to help fight infection or disease. This causes the lymph nodes to get bigger when they are fighting the infection. Lymphatic system includes lymphatic fluid, lymphatic vessels, lymph nodes, spleen, tonsils, adenoids, Peyer patches in the intestine, and the thymus. Lymphatic fluid consists of an ultrafiltrate of blood collected within lymphatic channels, which run throughout the entire body. The fluid is slow-moving and is transported from the head and extremities to larger vessels, which then drain into the venous system.



Cervical  
Lymphnodes

Along these channels reside approximately 600 lymph nodes. In children, lymph nodes reach their largest size at about the age of 8–12 years and get smaller after adolescence.

This entire system works like a “vigilance system” in the body. Lymph nodes contain an abundance of lymphocytes. Lymph is filtered through the lymph nodes, where particulates and infectious organisms are detected, filtered and fight begins with the filtered foreign organisms. In other words, lymph node is like a battle field.

## ▶ Nodes through the body

Lymphnode is a small bean shaped structure that is a part of immune system. Total around 600 lymphnodes are present in the body. They are present on the external surface as well as internally in relation to internal organs. Lymph nodes filter the fluid that flows through the lymphatic vessels and contains lymphocytes (white blood cells) that helps the body to fight infections. These lymphnodes are connected to one another by lymphatic vessels. Clusters of lymphnodes are found in the axilla, groin, neck, chest and in the abdomen.

Lymph glands, play a vital role in body's ability to fight off infections. They function as filters, trapping viruses, bacteria and other causes of illnesses before they can infect other parts of the body. Common areas where we might notice swollen lymph nodes include neck, chin, armpits and groin. The internal lymph nodes are present in relation to all organs like -lungs, liver, heart and intestines. They get enlarged when ever there is a pathological disease in the organ.

## ▶ Enlargement of lymphnode

Swollen lymph nodes usually occur as a result of infection from bacteria, viruses, parasites, and . Rarely, swollen lymph nodes are caused by cancer. Common infections are -Sore throat, Measles, Ear infections, Infected (abscessed) tooth, Skin or wound infections, such as cellulitis, Human immunodeficiency virus (HIV) — the virus that causes AIDS, Mononucleosis. Rarely cancerous conditions like- Lymphoma (cancer that originates in lymphatic system) Leukemia (cancer of the blood-forming tissue) Other cancers that have spread (metastasized) to lymph nodes.

Sometimes lymph nodes can swell when there is an infection in the area. For example, the lymph nodes in the neck, under the chin, or behind the ears may swell when child has a cold or sore throat. And an injury or infection in a leg or foot can make the lymph nodes

in child's groin to swell. Any infection in the hand or following BCG vaccination to the upper arm, the lymph nodes in the axilla may get enlarged. It is an indication that they are fighting the infection. They may swell a bit, pain a bit on touch and regress on their own but to totally disappear it may take longer time. The rapid enlargement of the gland during the acute stage is the cause for the pain. Not only the external glands even internal lymphnodes will get enlarged due to infection. For example, if there is infection in the intestine, the associated lymphnodes called mesenteric lymphnodes will get enlarged. The infection in the intestine and the enlarged lymph nodes along with intestine will cause colicky pain in the abdomen when ever intestinal movement occurs.

Rarely cancerous changes may start in the lymphnodes. This is called -Hodgkins lymphoma. The reason for its development is not known. It is common between 15-35 years and again between 50-70 years aged. If delayed, it may spread to other organs. So, any lymphnodal enlargement without reason, painless firm nodes, with history of loss of weight we should look with suspicion. If needed biopsy to be done.

## ▶ Lymphnode enlargement- what to do?

Lymphadenopathy is abnormal size, number and stiffness of one of more lymph nodes. It may be local lymphadenopathy in which a single or multiple lymph nodes adjacent to each other are involved or it may be extensive lymphadenopathy in which more than two lymph nodes which are not adjacent to each other are involved. If the lymph nodes are mildly enlarged and not significant, there is no need to worry. It is common in childhood to have some lymphnodal enlargement in the neck. But when the lymphnodal enlargement is significant, We should look with suspicion.

- If the lymph nodes are enlarging progressively without regressing. In

young children, 2 cm in the neck, 1 cm in the axilla and 1.5 cm in the inguinal region are considered normal values and they do not require investigation

- If they are red and tender to touch
- If there is change in the colour of the skin over the lymph nodes.
- If they are stony hard and painless
- If the enlargement of the lymphnodes is there throughout the body
- Enlarged lymphnodes causing pressure symptoms.
- If the lymph node size is more than 2cm and associated with fever and loss of weight.

They need further evaluation.

### ▶ **Mesenteric lymphadenitis**

Mesenteric lymphadenitis is an inflammation of the lymph nodes which are present in a membrane that attaches the intestine to the abdominal wall. These lymph nodes are among the hundreds that help the body to fight diseases . They trap and destroy microscopic “invaders” like viruses or bacteria. Mesenteric lymphadenitis causes abdominal pain. It is most common in children and teens. Infections that cause mesenteric lymphadenitis may be located in one place (local) or throughout the body (systemic). The infections may be caused by Viruses, Bacteria, or Parasites. The most common infections are gastroenteritis and yersinia enterocolitica.

Mesenteric lymphadenitis is confirmed by ultrasound abdomen. Blood tests , urine tests and CECT abdomen will help in ruling out other causes. It is treated according to the causative factor. Some may be simple and rarely others are serious like in any other lymphnodal enlargement.

### ▶ **How to evaluate and treat lymphadenopathy in children ?**

Lymphadenopathy is a common problem in the childhood and necessitates a careful physical examination and follow-up. Laboratory and imaging methods should be used when ever necessary. Although lymphadenopathy is mostly related with infections, care should be taken in terms of malignancy where ever it is suspected. In young children, 2 cm in the neck, 1 cm in the axilla and 1.5 cm in the inguinal region are considered normal values and they do not require investigation.

When ever lymphnodal enlargement occurs, they should be treated with 2 weeks of antibiotics and followed up. If the lymphnodes regress in size, they should be further followed up for a period of 3 months. If the lymphnodes does not respond, or increasing in size and number , they should be evaluated by ultrasound examination of the lymphnodes, fine needle aspiration cytology ( FNAC) and biopsy. In the ultrasound , the number of the nodes enlarged, status of the nodes , is there any pus, are the lymphnodes got stuck together ( Matting), is there any associated liver and spleen enlargement should be seen. Under the ultrasound guidance, the cells from the glands can be aspirated and examined under microscope . This is called FNAC -fine needle aspiration cytology

If there is any doubt, one of the gland is removed and sent for histopathological examination. This will decide whether the gland enlargement is due to infection or due to other reasons. The treatment of lymphnodes depends on the cause of the enlargement.

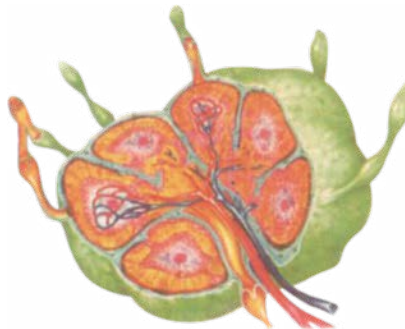### ▶ Remember these points in lymph nodal enlargement

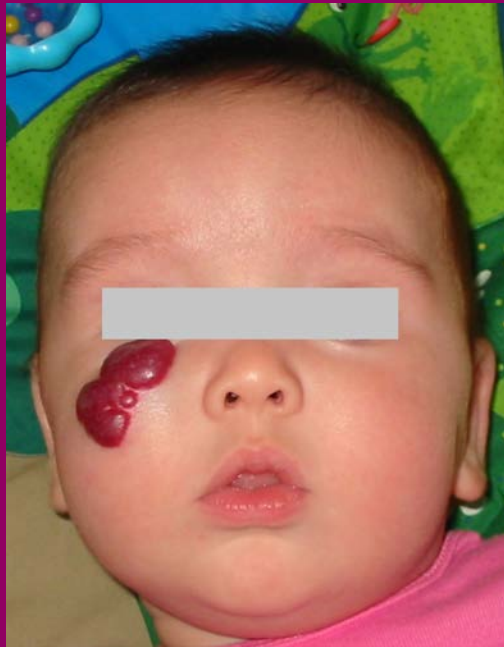- Lymphadenopathy is the swelling of the lymph nodes in the body.
- The lymph glands are part of the immune system and help to fight infections and other disease. They are like local police station.
- They are enlarged when the body is fighting infection or other diseases. If they are enlarged in throat infections, it indicates they are doing their job.
- Since enlarged lymph nodes are often near the source of infection, their location can help to find the cause.
- Do not press and look for lymphnodes frequently. Examine them only when they are enlarged and tender.
- Lymphnodal enlargement is not a contagious disease.
- After controle of infection, it takes 3-6 weeks for the lymphnodes to reduce in size but total disappearance may take a longer time.
- Treatment is usually based on the cause of the lymphadenopathy.
- Do not ignore if lymph nodal enlargement is painless, firm & rubbery, and increasing in number and size.it may be a sign of dangerous disease.

### Key Points :

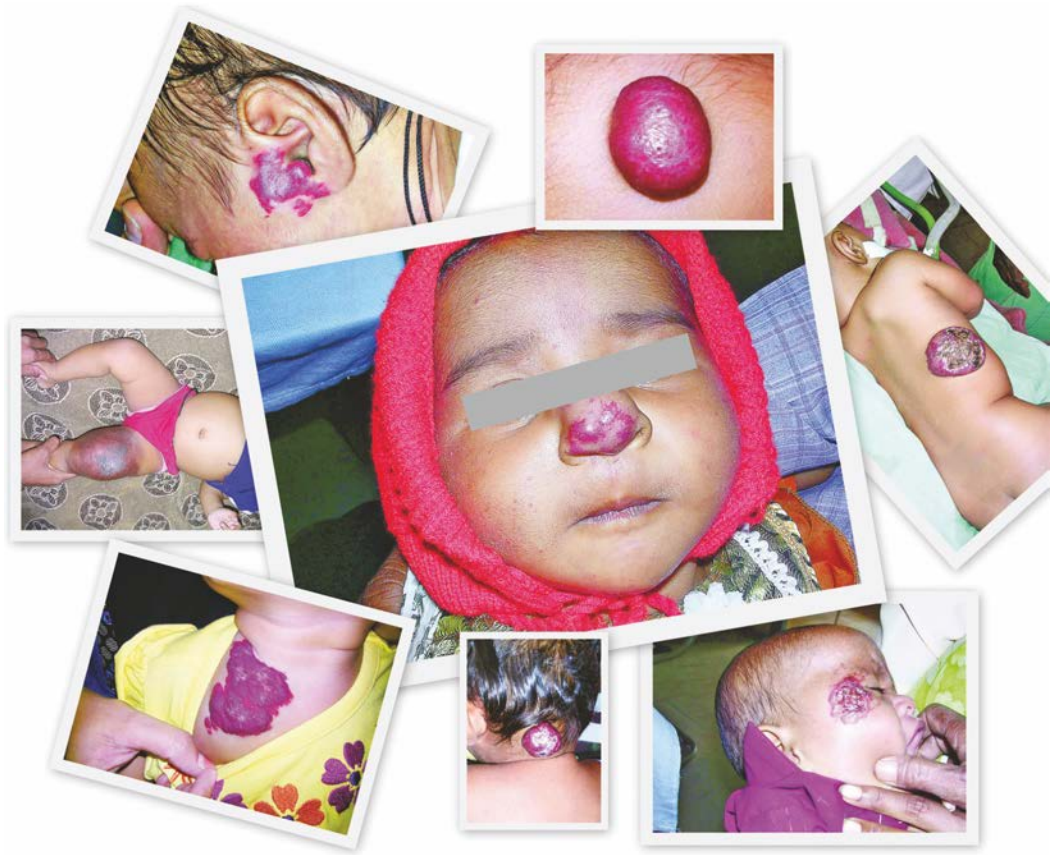Children may get swollen lymph nodes if they're fighting infection or inflammation. if we are not sure why the nodes are swollen, or the nodes are painful or getting bigger- doctor has to be consulted.

Treatment will depend on what is causing the swollen lymph nodes.





## HEMANGIOMAS IN CHILDREN



**Hemangiomas on Various Parts of the Body**

## HEMANGIOMAS IN CHILDREN

- Mrs. Renuka was blessed with a beautiful girl baby. Everything was normal at birth. But after 2 weeks a small red spot appeared over the baby's right cheek. It was growing rapidly. The parents are alarmed.
- Similar situation to Mrs. Smitha. Her daughter was normal at birth but within one week developed multiple red cherry spots over her body. These are growing daily.

In such situations, parents get panicky and many questions arise in their mind.

- What are these angry looking lesions?
- Why they occur ?
- Are they dangerous ?
- Are they a sign of concern ?
- Why they are growing fast ?
- Is there a permanent treatment for these red lesions ?

These lesions are called .... Hemangiomas. In real terms, Hemangiomas are panicky in appearance but they are not dangerous. Parents need to know about these lesions & their natural course.

### ▶ **Whats Is A Hemangioma ?**

Hemangiomas are benign masses arising from blood vessels (vascular neoplasms), that have a characteristic clinical course, marked by early rapid proliferative growth and followed by slow spontaneous involution. Hemangiomas are non-cancerous (benign) growths arising from blood vessels, usually appear as a red birthmark anywhere on the body within one to two weeks after birth. Most of the

hemangiomas do not cause problems and go away without treatment. They may be involving only skin (cutaneous) or sites other than skin & internal organs like liver.

Skin hemangiomas occur mostly in head & neck area- in 60% of cases, followed by trunk (25%) and extremities (15%). 80% of hemangiomas are solitary & focal. Most of them are 0.5 to 5cm. Rarely they are segmental involving more than 5cm of the skin area. They grow rapidly in the first few months of life. Later when the baby starts growing, they start shrinking and go away by five to seven years. These hemangiomas have a characteristic course – early rapid growth (proliferation) followed by later spontaneous reduction in size (involution). During the early growing phase (proliferative stage) rapidly dividing cells which line the blood vessels (endothelial cells) are responsible for rapid increase in size. Hemangiomas of the skin can form from the top layer of the skin or involve the deep fatty layer underneath also. In the beginning it appears as a red birth mark on the skin. Slowly it will start to protrude from the skin. While internal hemangiomas like in liver form in the liver or on the surface of liver. These hemangiomas are thought to be estrogen sensitive. Hemangiomas can occur in other areas of the body like lungs, kidneys, gastro-intestinal tract, pancreas & brain. Hemangiomas which grow in cavities like brain are called -Cavernous hemangiomas.

### ▶ **How Common are Hemangiomas ?**

Infantile hemangiomas occur in approximately 2% at birth to up to 10% at one year of age of pediatric population. Hemangiomas are more common in preterm babies (22- 30% in those with weight less than 1.5kg). more common in multiple gestation children. Hemangiomas

are 3 to 5 times more common in girls. 10 times more common in white children than in black race children. 30 % hemangiomas are present at birth where as 70% develop a few weeks later. Incidence of hemangiomas in children increases with increase in maternal age, placenta previa births & with preeclamsia mothers. When chorionic villus sampling is done in pregnant mother – increased chances of hemangiomas in baby increases.

### ▶ Why Hemangiomas Occur ?

Hemangiomas of the skin develop, when blood vessels group together in to a lump. The exact cause or cell of origin of hemangiomas has not been definitely elucidated. But studies shows that the proteins required for this will develop from placenta during development in the womb. Studies shows that embolic placental endothelial cells,(angioblasts-cells which give rise to blood vessels) that have reached fetal tissues from chorionic villi,will lodge in any tissues or any skin area of the developing baby and give rise to hemangiomas locally. Mesenchymal stem cells,which have got capacity to differentiate in to numerous mesodermal cells like fat & blood vessels,may also play a role in the formation of the hemangiomas. Genetic or hereditary role in hemangiomas development is not substantiated by studies. Most of the hemangiomas are sporadic.

### ▶ Symptoms of Hemangiomas ...

Hemangiomas usually do not cause symptoms during or after their formation. However they may cause symptoms, if they grow large, if they are multiple, or if they grow in a sensitive area. Hemangiomas of the skin appear as small red scratches or bumps. As they grow their appearance is like a reddish brown birthmark. Hemangiomas in internal organs of the body, usually go unnoticed until they grow large or multiple hemangiomas form. Common symptoms are ... nausea, vomiting,

loss of appetite, abdominal distension, abdominal pain, unexplained weight loss or feeling of fullness in abdomen.

### ▶ How They Progress ?

Usual maximum size of hemangiomas is 0.5 to 5cm. it can reach to a size of 20cm. most of the hemangiomas are focal and well circumscribed. They characteristically exhibit early rapid proliferation followed by spontaneous involution. The hemangioma becomes elevated, and dome shaped, lobulated, plaque like, tumoral or any combination of this can occur. Maximum growth occurs during first 4 -6months. Proliferation slows between 6 -12 months of life. Complete involution occurs in 50% cases by 5years and 70% by 7years. In remainder of cases, complete involution occurs by another 3 to 5years. There are different kinds of hemangiomas. They have different appearances. Superficial hemangiomas – raised bright red patch, sometimes with textured surface. Colour fades out slowly over a period of 7yrs. Deep hemangiomas- appear like a bruise or bluish in colour.

### ▶ How Hemangiomas are Diagnosed ?

Hemangiomas on the surface - does not require any special tests as they are visible on skin surface as red scratches or growths, detected by the parents or physician. Hemangiomas in the internal organs –are usually spotted during imaging studies like ultrasound examination, CT scan or MRI study. Ultrasound helps in differentiating hemangiomas from other deep seated dermal or subcutaneous growths and also help in assessing the extent and magnitude of hemangioma. MRI study with contrast is the modality of choice, can delineate the extent and magnitude of hemangioma of cutaneous and extra cutaneous hemangiomas. it will differentiate the high flow hemangiomas from other vascular anomalies like arterio-venous malformations.



## ▶ What are the Complications Of Hemangiomas ?

Most of the hemangiomas are benign or asymptomatic. But occasionally they can lead to complications like.

- Ulceration (common in neck area & trunk)
- Bleeding (mucosal areas, diaper areas & neck)
- Impinge on vital structures (vision, hearing, feeding, breathing)
- Significant structural abnormality/disfigurement. (tip of the nose, ears & lips)
- High output cardiac failure. (internal hemangiomas due to increased vascular flow).
- Segmental hemangiomas occupying more than 5cm of skin area may be associated with underlying congenital anomaly (spina bifida, PHACE syndrome)

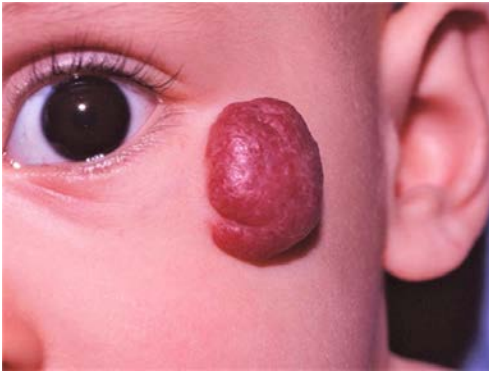## ▶ Treatment Options for Hemangiomas.....

Vast majority of hemangiomas do not require any medical or surgical intervention. Small, single & those located in non-traumatic areas are to be left alone and observed. They will undergo spontaneous resolution over a period of time, as the child grows. Treatment options for clinically significant hemangiomas include....

- Corticosteroids administration
  - Sclerosants injection.
  - Laser treatment
  - Propranolol therapy
  - Surgical removal.
- o Oral steroids are preferred over intra-lesional steroids. Oral steroids can slow the growth and decrease the size of proliferating hemangiomas. Use of steroids have associated side effects. Children may develop – Moon Face with steroids.
- o Lasers is used for superficial hemangiomas and ulcerated hemangiomas. Laser treatment results in reduced pain, rapid reepithelialization & early involution. Lasers are used especially in areas likely to result in significant functional or psychological impact like.... Tip of the nose, eyelids, lips, & ears. It is done once in 4 weeks till lesion is healed. Disadvantage with laser treatment is, it may result in scarring or residual skin changes. May worsen ulceration in deep lesions.
- o Propranolol therapy – Propranolol is used in the treatment of proliferating hemangiomas. It has revolutionized the management of hemangiomas and became the treatment of choice now. Studies have shown total or near total regression of lesion in 60.4% of cases when treated with 1-2mg/kg/day of propranolol.. It is better to avoid in children with bronchospasm, cardiac anomalies & CNS anomalies.
- o Surgery is done in the following situations
1. Well Localized, rapidly proliferating lesions with risk of bleeding.
  2. Excision of Involved residual skin lesions- for cosmetic purpose to reduce fibrofatty tissues.
  3. Excision of cosmetically disfiguring lesions like eyelids.
  4. Excision of Functionally involving lesions like in joint areas.
  5. Excision of lesions Where there is a risk of hemorrhage and damage to vital structures.
  6. Symptomatic hemangiomas in internal organs.

Early excision in selected cases may save lives, preserve vision, eliminate a cosmetically disfiguring lesion.

Hemangiomas in internal organs require treatment – when they grow large or when they become symptomatic like development of pain or bleeding. Treatment options for hemangiomas in internal organs include .... Surgical removal of hemangioma, Surgical removal of organ, embolization of the feeding blood vessels to the hemangioma.



## ▶ When should parents consult a pediatric surgeon ?

1. When the primary physician is not sure about diagnosis.
2. When the hemangioma is on the prominent part of the face.
3. When the hemangioma gets infected, bleeding or develops a scab.
4. When the hemangioma is growing rapidly.
5. When your child is having multiple hemangiomas (it may be a sign of presence of other internal hemangiomas like in GIT or liver, which requires attention)
6. If the hemangioma is along the spine. (this can be a sign of malformed spine)
7. If the hemangioma is in a functional areas like – elbow, knee, eyelids & over lips.

## Key Points :

Hemangiomas are innocent lesions occur any where on outside or inside of the body.

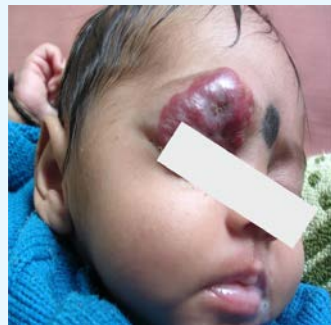Hemangiomas are due to localized grouping and rapid growth of the blood vessels.

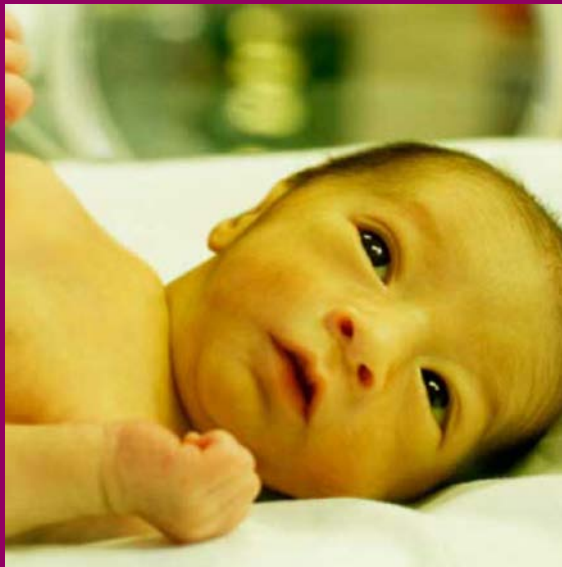Most of the hemangiomas do not cause any trouble except looking ghostly

Hemangiomas have predictable natural course- initial rapid growth followed by slow regression. It takes 7yrs -9yrs for complete involution.

Medications will help in early resolution

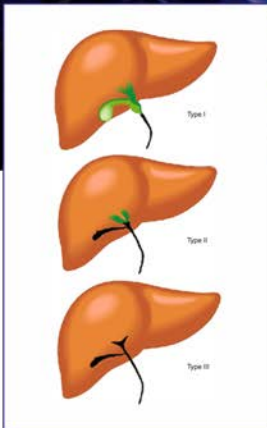
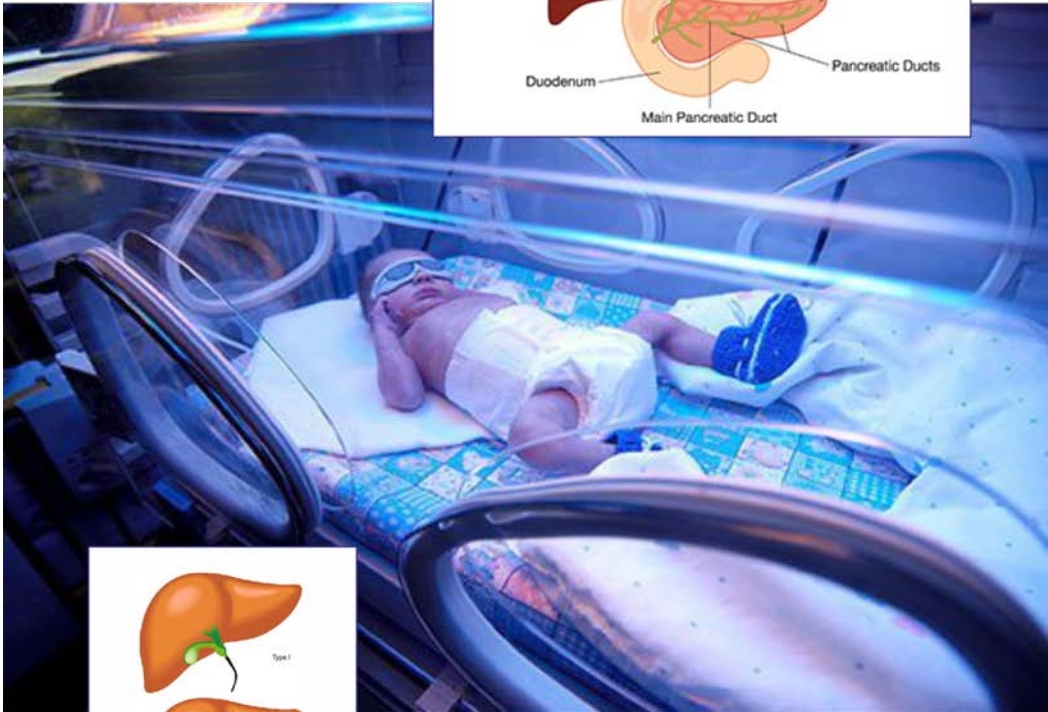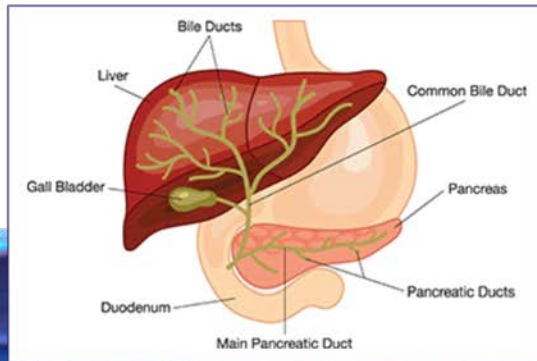
Propranolol is the approved oral medication of choice at present.





## JAUNDICE IN CHILDREN

## Normal Arrangement



**Abnormal Arrangement  
Biliary Atresia**

Jaundice is a very common condition in newborn babies. It usually appears in the first few days or weeks of life. Most cases of jaundice are not caused by any major disease and clears up quickly without any treatment. Jaundice is caused by a yellow substance (pigment) called bilirubin. The liver, spleen and bone marrow makes bilirubin out of used red blood cells that have broken down. Bilirubin is a yellow pigment that is produced as the body recycles old red blood cells. The liver helps to break down bilirubin so that it can be removed from the body in the stool. It can be normal for newborn babies to be a little yellow between days 1 and 5 days of life. The colour most often peaks around day 3 or 4.

The liver then passes bilirubin out of the body through bile which flows into the stool. After birth, the baby's own liver takes over this task. Jaundice occurs when the baby's liver is not able to handle extra bilirubin on its own. Because a baby's liver is still immature, jaundice is quite common. However, for most newborns, this only lasts for a few days or weeks. After that, the liver of most babies is able to handle bilirubin normally and pass it out of the body so that it won't build up and cause jaundice. Rarely, jaundice in children may be a sign of a more serious health issue.

- Jaundice occurs when bilirubin cannot be removed from the body fast enough and levels in the blood become too high. The buildup of bilirubin causes the skin and the white part of the eyes to appear yellow. This yellowness extends from head to toe in a gradual manner. By assessing up to what level the jaundice extended on the body, the severity can be assessed.
- Yellowish skin and eyes: Press gently on baby's forehead with one finger. If the

pressed area looks yellow, it is a sign of jaundice.

- Dark yellow coloured urine & Pale stool: normal stool color is yellow or green. A baby's stool should not be gray, white or pale.

There are two main types of jaundice in infants:

- Physiologic jaundice: This type is quite common. It affects about six out of 10 newborns. Physiologic jaundice happens when bilirubin does not move out of the body fast enough. Most often, it goes away on its own by the time the baby is about 2 weeks old. If it continues, treatment may be needed.
- Pathologic jaundice: Various disorders, such as infectious, endocrine (hormonal) or genetic (inherited) diseases, can keep the liver from processing bilirubin as it should. In those cases, the problem that is causing the jaundice needs to be found and treated.

### ▶ Red flags signs of danger in ( severe) jaundice

- Jaundice noted immediately after birth on day one. Usually jaundice is noticed on 2nd-3rd day of life. If jaundice is noticed on day of birth, it is dangerous.

- Jaundice persisting beyond 2 weeks

Usually jaundice due to simple reasons, will be relieved by 10 days but if it persists beyond 2 weeks it should be looked with suspicion.

- Rapidly increasing jaundice
- Passing pale coloured stools along with deep yellow coloured urine.

- High levels of direct bilirubin fraction
- Jaundice with sick baby : irritable, dehydrated, not feeding well, weak and losing weight
- Jaundice with enlarged liver.

## ▶ What causes the jaundice in children

Jaundice due to simple reasons is the common jaundice noticed in newborns. It is noticed on 2nd or 3rd day of life. Gradually decreases and completely resolves by 14 days. The reasons for this simple jaundice are...

- Physiological (Simple) jaundice ( due to Immature liver) :
 

Newborns produce more bilirubin than adults do because of greater hemoglobin level and faster breakdown of red blood cells in the first few days of life. Normally, the liver filters bilirubin from the bloodstream and releases it into the intestinal tract. A newborn's immature liver often can't remove bilirubin quickly enough, causing an excess of bilirubin. Jaundice due to these normal newborn conditions is called physiologic jaundice, and it typically appears on the second or third day of life. It usually resolves on its own by 2 weeks time.
- Enzymes in Mothers milk : If jaundice seen in second or third week (after the first week) of life in a breastfed baby who is otherwise healthy, the condition may be called breast milk jaundice. It is likely caused by : enzymes & factors in a mother's milk that will interfere with the absorption of bilirubin from the intestine & Factors that keep certain proteins in the baby's liver from breaking down bilirubin. This condition is self limiting and resolves on its own. There is no need to stop mothers breast milk in this condition. reasons for
  - Insufficient feeding:
 

This occurs within first week of life. jaundice occurs when the baby does not get enough breast milk, Newborns may not receive optimal milk intake, which leads to elevated bilirubin levels due to increased reabsorption of bilirubin in the intestines. Inadequate milk intake also delays the passage of meconium, which contains large amounts of bilirubin that is then transferred into the infant's circulation. In most cases breastfeeding can, and should, continue. More feedings can reduce the risk of jaundice.
  - Head injury :
 

During difficult deliveries, blood can collect under the scalp skin called cephalohematoma. It usually gets absorbed in 4-6 weeks time. During hematoma absorption bilirubin levels may rise and cause jaundice.
  - ABO incompatibility
 

ABO incompatibility is one of the diseases which can cause jaundice. ABO incompatibility happens when a mother's blood type is O, and her baby's blood type is A or B. The mother's immune system may react and make antibodies against her baby's red blood cells. ABO incompatibility is treated in newborns by light therapy (phototherapy). On rare occasions an exchange transfusion may be necessary. Full recovery usually occurs with no lasting repercussions.
  - Severe jaundice ( Pathological) like Conditions that block the flow of bile out of the liver (cholestasis), such as biliary atresia or choledochal (bile duct) cyst.
  - Bile duct abnormalities : Biliary atresia : in this condition , the ducts which carry bile from liver in to the intestine either they fail to develop or gets blocked. As the bile is not flowing in to the intestine,

it gets stagnated in the liver leading to deep jaundice, pale coloured stools & liver failure. This is a serious condition. It is confirmed by Hepatobiliary nuclear scan and liver biopsy. Surgery is the only option and hope for this condition. It should be treated early ( before 2 months of age) by a procedure called Kasai potoenterostomy. In this procedure, an intestinal loop is attached to the liver after dissection at the portal area of liver, for establishing flow of bile in to the intestine. If this surgical procedure fails -liver transplant is the only option.

- **Choledochal cyst :** In this condition, the tube which carries liver secretions ( bile) will be swollen, leading to stasis of bile. This condition can lead to jaundice ,repeated infections of bile tubes and liver failure. This condition can be diagnosed by ultrasound abdomen and MRCP test. this condition is corrected by a surgical procedure called – cyst excision and hepaticoenterostomy , in which the entire cyst is excised and a loop of intestine is anastomosed to the liver for free flow of bile in to intestine.
- **Neonatal hepatitis**  
During pregnancy, if the mother gets TORCH viruses infection ( Toxoplasmosis, rubella, cytomegalovirus & Herpes infections) it will lead to fetal developmental disruption. They can present with enlargement of liver,spleen and deep jaundice. The treatment of TORCH syndrome is mainly supportive and depends on the symptoms present; medication is an option for herpes and cytomegalovirus infections. Prevented by treating an infected pregnant woman, thereby preventing the infection from affecting the fetus

#### **Other causes ....**

- **Blood cell diseases :** such as sickle cell anaemia or glucose-6-phosphate

dehydrogenase (G6PD) deficiency where the blood cells are damaged early.

- **Infections :** usually caused by a virus (such as the CMV virus) or bacteria (such as in a urinary tract infection). Jaundice can also be a sign of a more serious infection, such as or sepsis.
- **Endocrine (hormonal) disorders :** such as hypothyroidism (underactive thyroid) or hypopituitarism
- **Genetic diseases :** such as Gilbert syndrome (a common, harmless condition) or galactosemia (a serious illness that must be treated with a special diet for the baby). There are many other genetic diseases that can cause jaundice, but most of them are extremely rare.

#### **▶ Treatment of jaundice in children**

Physiological jaundice (jaundice not caused by any disease) often goes away without treatment within two weeks. During this time, the baby's blood may need to be tested to make sure bilirubin levels are improving. Some babies need a treatment called phototherapy. This exposes the baby's skin to a special type of bright blue light. These blue lights are very safe for most babies. The light causes a chemical reaction in the skin that lets the body remove bilirubin more easily through urine and stool. Depending on bilirubin levels, phototherapy may take anywhere from a few hours to several days. There are two types of phototherapy for jaundice:

- **Conventional phototherapy:** The baby is placed on a bed under a set of blue lights. These are lamps that make a special blue light. Soft eye patches protect the baby's eyes during phototherapy treatment.
- **Fiberoptic phototherapy:** This treatment is done with a device called a bili blanket. It is a soft pad with blue phototherapy lights inside. The baby is placed on

or wrapped in the bili blanket during treatment.

- If phototherapy does not bring down bilirubin levels low enough or fast enough, a baby with severe jaundice may need a **blood exchange transfusion** (some of the baby's blood is removed and replaced with donor blood), but this is rarely needed. For children with pathological jaundice (jaundice that is caused by disease), the best course of treatment depends on the cause. As discussed above, pathologic jaundice can have many different causes, and various tests may be needed to find out what the problem is and how to treat it.



### what will happen ,if treatment is not given

Most often, jaundice is temporary and not harmful. In rare cases, jaundice can be serious or even life-threatening. Fortunately, prompt treatment can prevent most complications of jaundice in children. If not properly treated, jaundice can lead to serious health issues. When bilirubin levels rise dangerously high, it can harm cells throughout the body. It is possible for severe jaundice to cause brain damage (kernicterus) leading to complications such as cerebral palsy or deafness.



### Key Points Of Childrens Jaundice

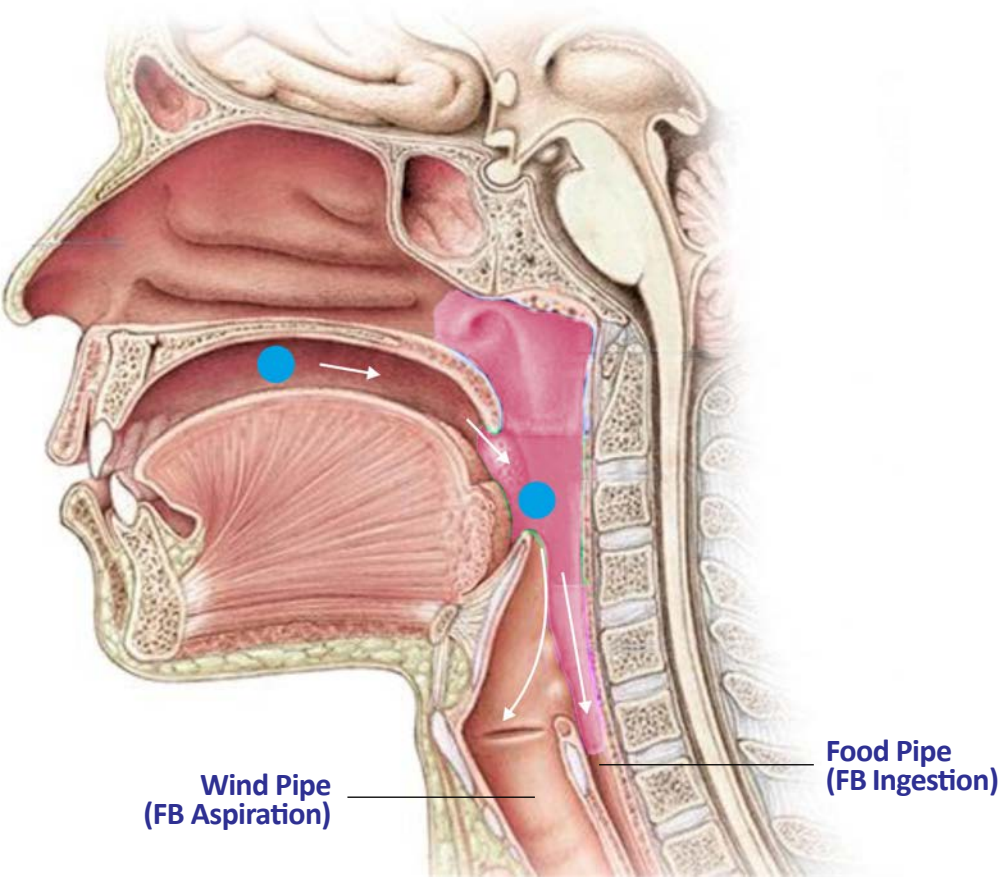
- Jaundice is very common in newborns( 60%)
- It is usually temporary and harmless.
- Rarely jaundice in children is serious or life-threatening.
- If jaundice is prolonged (lasting longer than 2 weeks), severe (with very high bilirubin levels), or pathologic (caused by a disease), prompt attention, testing, and possibly treatment are important to prevent complications.





## FOREIGN BODY INGESTION AND ASPIRATION IN CHILDREN

Once the Child Ingests the Foreign Body...

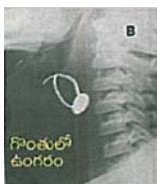

## FOREIGN BODY INGESTION AND ASPIRATION IN CHILDREN

- One family is enjoying the movie along with their 2 years old boy. At interval of the movie they bought pop-corn. the boy is watching the movie and taking the pop-corn. Suddenly one of the popcorn got stuck in the throat and slowly moved in to the respiratory system. He had breathing difficulty and became blue. By the time he was taken to hospital, he is no more.
- year 6months girl accidentally swallowed a nail while playing. But it moved into respiratory system, got stuck in the windpipe. Doctors tried to remove through endoscopy but they could not succeed so surgical removal was done.



If we go into the medical histories of Pediatric surgeons, ENT surgeons and Pediatric hospitals there are many such stories. These foreign bodies are small, tiny material to see but they become lifetreatening if the children took them in to their mouth. As children explore the world, they inevitably put foreign bodies in to their mouth and swallow some of them. Foreign body ingestion is the swallowing of an Object other than normal food. Foreign body aspiration is the condition arising out of foreign body entering the respiratory system. This commonly happens in children aged between six months to six years, who tend to put things in to their mouths. In young children both boys and girls are equally affected.



Once object is swallowed, it may get stuck in the esophagus (esophagus is the tube that connects the mouth to the stomach) or get trapped in the stomach. Swallowed objects usually pass through the entire digestive tract and out of the anus (rear end) without problems in most of the cases. FB that damages the intestinal tract, become lodged or have associated toxicity must be identified and removed. Children with pre-existing GIT abnormalities (intestinal stenosis, previous surgery) are at increased risk for complications. But foreign body aspiration is

the leading cause of death in children aged between 1 and 3 years. Though older children are also known to aspirate foreign bodies but toddlers are more prone to do so.

### ▶ Causes of Foreign Body Ingestion

Foreign body ingestion may happen by accident or done on purpose. While busy exploring their environment, putting things in to mouths with inadequate dentition and immature swallowing co-ordination.. Very young children may put anything in their mouth and swallow the object. The objects may be - blunt, sharp, pointed or poisonous. These may include -safety pins, small batteries, needles, tacks, seeds, toothpicks,

Pieces of toys, glass, wood. or school supplies. Children may swallow a fish bone or an animal bone while eating. Coins are the most commonly swallowed Objects in children. 96% of the aspirated FB are organic in nature like...pea nuts, custard apple seeds, and tamarind seeds heading the list

### ▶ Sites of Impaction of Ingested Foreign Body

Most of the complications of pediatric Foreign Body ingestion are due to esophageal impaction. Most common is at the thoracic inlet (area between the clavicles in x-ray chest)

where the cricopharyngeous muscle sling will “catch” the FB. 70% of the esophageal FB are lodged at this level. Another 15% of FB will lodge at mid-esophageal level where major blood vessel aorta, crosses the esophagus. Remaining 15% will lodge at lower esophageal sphincter level. Once the FB, moves from esophagus and reaches the stomach, it is much less likely to lead to complications. Exceptions are FBs which are pointed, too long more than 5 cm or too wide more than 2 cm fail to pass through the pyloric sphincter. Another interesting situation is the swallowed magnetic toys attracting and adhering together leading to intestinal obstruction.

### ▶ Impacted Foreign Body

As long as FB is moving down, it does not cause much damage. But once a FB becomes lodged in the GI Tract it can cause local inflammation, ulceration

Pain, bleeding, scarring and obstruction or it can erode through GI Tract. This causes peritonitis. Eroding through esophagus can lead to mediastinitis.

### ▶ Clinical Presentation

- Usually they are brought to medical attention, after the caretaker witnesses the FB ingestion.
- The child may present with signs and symptoms of a complication of ingestion.
- The care giver discovers the passage of a FB in the stool and brings the Child for evaluation.
- May present with vague symptoms. like pain in the neck, throat, chest or abdomen.
- Esophageal FB may present with Dysphagia, food refusal, hematemesis, chest pain, stridor, emesis or unexplained fever.

- Stomach and lower gastrointestinal foreign bodies will produce vomitings, abdominal distension and Haematochezia.
- May have breathing problems... coughing, or wheezing or cyanosis.

### ▶ Investigations

Most of the Foreign Bodies ingested by children are radio-opaque. (in contrast to inhalation where most of them are Radio-leucent). A single plain x-ray that includes neck, chest and entire abdomen is usually sufficient to locate the FB. If the object is in the esophagus- frontal and lateral films are needed to precisely locate and for better identification of the object. When a Foreign Body is strongly suspected, visualization by endoscopy is the best option which has added advantage of allowing the removal of the FB. CT or MRI are rarely done in special cases but may enhance the detection of foreign bodies. Patients with coins in the abdomen can be safely observed but those with FB in the esophagus probably should have exact location confirmed by plain x-ray.

### ▶ Treatment

The treatment of Foreign Body ingestion depends on the type and size. Treatment also depends on how long and how far the

FB is in the gastro-intestinal tract. Most of the time, watchful waiting may be advised if the FB is small, smooth and in the stomach. It may take few days to weeks for it to pass. Most of the children who swallowed FB do not require special care. They should be allowed to assume a position of comfort. Foreign Bodies in esophagus like. button batteries and others - immediate removal by esophagoscopy is the treatment of choice. Foreign bodies impacted at esophago-gastric junction if intact, can be removed by endoscopy. If it fails still Foreign Body is impacted, it has to

be removed by surgery. If the Foreign body has already caused perforation of esophagus, an emergency surgery has to be done. Otherwise it will lead to (severe Infection of the chest (Mediastinitis) which has got a high mortality rate.

If FB has moved down in to the stomach or small bowel- shape, size and sharpness matters a lot. Usually the small, smooth, and closed FB will pass spontaneously. Long FB like pens, pencils, sharp FB like pins, open FB like Safety pins will likely to get stuck and will get impacted. These situations need surgical intervention. Sometimes these sharp FB will perforate and are outside the GIT.. they need laparotomy with C-Arm control. Usually FB of size 5cm length and 2 cm width can not pass through pylorus and they need removal by endoscopy.

### ▶ **Ingested & Retained FB**

The FBs are usually retained as they can not negotiate through control mechanisms in the GIT. Like pyloric area at the outlet of the stomach, Duodeno-jejunal junction at the beginning of the small bowel. Ileo-caecal region at the junction of small and large bowel. If the FB is large, lengthy or sharp it is difficult to negotiate these areas. If retained in the stomach, for more than 1 week even if it is smooth FB It has to be removed by endoscopic removal. If it is distal to stomach, follow up for another 2 weeks is advised. If the FB is stuck in small bowel and causing intestinal obstruction, it needs to be removed by enterotomy. Typical example is unbroken beetalnut. During the household functions, the unbroken Beetalnuts are used regularly. If the child swallows these nuts, as they pass through GIT, they swell in size and cause obstruction at ileocaecal region. This needs intervention by surgery.

If the FB enters the colon (large intestine), they pass out without much difficulty and a course of laxative is enough to make it pass spontaneously.

Alkaline Batteries causes erosion of the GIT wall leading to complications. They have to be removed, as and when they are diagnosed.

### ▶ **Foreign Bodies Which Need Attention**

- Sharp objects like open safety pin, glass pieces.
- Objects more than 5 cm long and more than 2 cm width.
- Alkaline batteries
- Objects which increase in size as they pass down like unbroken beetal nut
- Retained foreign bodies for more than specified period
- Foreign bodies which has already produced complications at the time of diagnosis
- All aspirated foreign bodies have to be removed immediately as they can cause life threatening complications.

### ▶ **Complications of the Foreign Body Ingestion**

Esophageal FB

- Mucosal abrasions
- Esophageal stricture or obstruction
- Retropharyngeal abscess
- Failure to thrive
- Esophageal perforation leading to mediastinitis
- Pneumomediastinum
- Tracheal compression
- Aorto-esophageal fistula formation.. resulting in hemorrhage.

Stomach and lower GIT foreign bodies.

- Mucosal abrasion
- Intestinal obstruction.
- Intestinal perforation leading to peritonitis.

## ▶ Foreign Body Aspiration

Foreign body aspiration is the condition arising out of foreign body entering the respiratory system. It is the leading cause of death in children aged between 1yr and 3yrs of age. 96% of the aspirated FB are organic in nature. Like peanuts, custard apple seeds or tamarind seeds. Where the FB lodges in the respiratory system depends on the size and shape of the FB. Majority of the FBs are found in the proximal airways. Organic FBs like seeds they swell over a period of time, worsening the obstruction. Small and sharp objects tend to lodge in the subglottic area.

## ▶ Presentation

FB aspiration can present in one of the 3 clinical phases.

- Immediate phase.. occurs immediately after the aspiration and presents as coughing, choking, gagging, wheeze, stridor or temporary cyanosis. Death rate is high in this phase.
- Asymptomatic stage... may last from few minutes to months. The varied duration depends on the location of the FB., the degree of FB obstruction, the type of material aspirated and the ease with which the FB can change its position.
- Renewed symptomatic phase.. characterised by airway inflammation or infection. This is possible if the FB is organic in nature. Symptoms include Repeated bouts of cough with sputum, haemoptysis (blood in cough), Fever, wheezing and intermittent cyanosis. Clinical presentation looks like pneumonia, croup, asthma, tracheomalacia, bronchomalacia.

Diagnosis depends on history of foreign body aspiration. Or sudden onset of coughing, choking, stridor or cyanosis- FB should

be suspected. If there is sudden onset of hoarseness, aphonia or stridor the FB is most likely in larynx or trachea. Chest retractions are seen with upper airway obstruction. Clinically, the symptoms depend on the size and location of the FB, the duration and the complications related to the FB. Most often there are unilateral diminished breath sounds and adventitious sounds because of airway narrowing can be heard. Alternating loss of breath sounds indicate that the FB is shifting its place and causing incomplete obstruction. Most of the aspirated FBs are organic and they are not visible on x-rays. So, indirect evidences of aspiration and bronchial obstruction like.. Collapse of lung, hyperinflation and mediastinal shift should be looked for in Xray chest.

## ▶ Management of Aspirated Foreign Body

In case of complete airway obstruction- infants should be treated with backblows, Chest thrusts, abdominal thrusts in supine position or abdominal thrust in upright position. Blind finger sweeps should not be done as it may push the FB down. If some respiration is possible encourage coughing and transfer to hospital as early as possible. Gold standard for removal of an aspirated FB is via a rigid bronchoscopy. Rigid bronchoscopy is done under general anaesthesia. Rigid bronchoscopy can be done as an emergency in the initial phase or as an elective procedure, when

They are presenting later with repeated chest infections. Nowadays illuminating FB forceps are available, which helps in better and easy removal of aspirated FBs. Most difficult situations are where the organic FB is of long duration and when the FB has already perforated the tracheobronchial tree. This needs an experienced pediatric surgeon's intervention.

## ▶ Situations Where Mishaps Can Happen

- Children eating popcorn in cinema-halls, while watching movie.
- Habit of giving feed to children, while children are watching the TV programmes.
- Birthday parties, functions and social gatherings, where attention on children will be less.
- Domestic festivals and functions where things like unbroken beetal nuts are easily available to children.
- House repairs time where lot of bolts and nuts are freely left out.
- Common in situations where parents are employed and children are left with care takers.



### Key Points :

Parents and caregivers of the children should be cautioned about leaving small objects particularly sharp objects and batteries, where young children may find them and place them in their mouths. This is especially common at times of unusual activity such as parties, functions, festivals, holidays, when visitors present at home or during travel. Do not let your child play with toys that have small parts that might come off and be swallowed. Make sure that older children keep their small toys away from younger children.







## CORROSSIVE INGESTION IN CHILDREN



### ▶ Introduction

- Chandu is a 18 months old boy. Started learning walking. His father works in an ice factory. One day he brought caustic soda to home. He kept it at a corner in the house. Chandu while playing went to that corner and on seeing the white caustic soda, mistaking it to be milk he took it and started crying. This is the starting point of his lifelong problem. He was treated on ventilator. Temporary tube was introduced in to the stomach for feeding purpose. He was with this tube for 2 years after that surgery was done to restore normal oral food intake.
- Sudhir is a 2 years old boy. His mother works as a laboratory technician. One day he went to lab along with his mother. Mistaking the lab solutions as cold drinks he took sulphuric acid. He is now in his adolescence but still he is suffering with respiratory problems and intake of food.

These are the stories of the children who took corrosives accidentally. Corrosive ingestion remains a common problem in developing countries, such as India due to the lack of strict laws that regulate the sale of caustics. It can pose a significant management challenge due to a devastating effect on the upper gastrointestinal tract in the acute and chronic phases of the injury. Although significant tissue damage occurs immediately after caustic ingestion, appropriate treatment of the acute phase can prevent aggravation of the injuries, and facilitate future management in the chronic phase.

### ▶ Corrosives

Corrosives are the substances either acid or alkali capable causing harmful, destructive damage to the tissues that they come in contact. Acids with a [pH](#) of less than 2 or [alkalis](#) with a pH above 12 are capable of causing the most extensive injuries on ingestion. Commonly ingested corrosives are broadly classified into acids and alkali. Sodium hydroxide containing bathroom cleaners and dishwashing agents are the often-implicated alkali while toilet cleaning agents containing sulfuric or hydrochloric acid and goldsmith's solvent, which contains hydrochloric and nitric acid in 3:1 proportion are commonly implicated acids. Sodium hypochlorite, a natural alkali constituent in household bleach, was the most commonly implicated corrosive agent in western countries. In developing countries such as India, where acids are commonly used in the toilet cleaners compared to the more expensive caustic soda, acids contribute to most of the corrosive accidents.

Alkalis damage tissue by saponifying fats, leading to liquefaction necrosis which allows the alkalis to reach the deeper tissues. Acids denature proteins via coagulation necrosis, this type of necrosis is thought to prevent the acid from reaching deeper tissues. So, alkalis are more dangerous. Clinically, the pH, concentration, volume of ingested substance in addition to the duration of time in contact with tissue as well as percentage of body surface area involved determine the severity of the injury.



## ▶ Sites where it happens

- Most of the cases of accidental corrosive ingestion occurs in the home atmosphere only. Toilet cleaners, detergents, cloth soda, floor cleaners are the material ingested accidentally.
- In schools in the laboratory setup, accidental ingestion of corrosives can occur.
- In neighbours houses, when the children goes to the toilet, they can accidentally ingest the toilet cleaners
- In goldsmith areas , they use acids for cleaning gold .Children ingest acids when they come to goldsmiths along with their parents
- Battery making units, they use alkalis. These sites are the source for accidental ingestion of corrosives
- Small scale Industries like soap making, printing presses, cycle polishing areas and copper polishing areas

## ▶ How accidental ingestion occurs.

Caustic ingestion occurs when someone accidentally or deliberately ingests a caustic or corrosive substance. Depending on the nature of the substance, the duration of exposure and other factors it can lead to varying degrees of damage to the oral mucosa, the esophagus, and the lining of the stomach. Studies shows alkali ingestion is more common than acids

- Corrosives are either colourless or they are colourful when made commercially. If they are colourless, they are consumed accidentally by children ,thinking that they are water. If they are white in colour, they are consumed mistaking it for milk and if they are colourful ,they are mistaken for cool drinks and juices.

- At the time of learning walking and crawling, the enthusiasm in the children is more. they wanted to see and explore everything they come across. So it is always better to keep the corrosives in a safer height and place away from the reach of children.

## ▶ How the corrosives cause damage after accidental ingestion

Clinical manifestations depend upon the extent of the injury. In the mildest form, the patient may be asymptomatic or presents with mild symptoms like throat pain with normal or mild erythema of the oral cavity mucosa. However, in moderate to severe injuries, the patient presents with significant symptoms.

- immediate manifestations of caustic substance ingestions include erosions of mucosal surfaces of the gastrointestinal tract or airway (which can cause bleeding if the erosions extend to a blood vessel), mouth and tongue swelling, drooling of saliva, nausea, vomiting, dyspnea ,dysphonia dysphonia irritation of the eyes and skin. Perforation of the esophagus can lead to infection in the chest ( Mediastinitis) or perforation of the stomach or bowel can lead to infection of abdominal wall(peritonitis). Swelling of the airway or laryngospasm can occur leading to compromised breathing. Injuries affecting the respiratory system include aspiration pneumonia and laryngeal sores. Later manifestations of caustic substance ingestions include esophageal narrowing( stenosis). Remote manifestations of caustic ingestions include esophageal cancer. People who have a history of caustic substance ingestion are more likely to develop esophageal cancer with most cases occurring 10–30 years after the ingestion. The severity of the injury can be

determined by endoscopy of the upper digestive tract, although CT scanning may be more useful to determine whether surgery may be required in the later period. During the healing process strictures of the oesophagus may form, which may require theureuptic dilatation or surgery.

### ▶ Longterm affects

Stricture is an important late sequel following corrosive ingestion. It begins within the first 2–3 weeks and may progress rapidly. Endoscopic dilatation using either bougies or dilators is recommended in patients with short dilatable strictures. If endoscopic dilatation is not feasible, then definitive surgical treatment is performed after 6–12 months, depending upon the level of the stricture with a longer delay preferred for high pharyngeal stricture. The type of surgery is determined by the extent of gastric and esophageal stricture.

### ▶ Treatment Immediate measures

Management of acute corrosive ingestion is focused on initial resuscitation, evaluation of the grade of injury, treatment of early complications, maintenance of nutrition, and prevention of longterm stricture formation

Use of milk or water to dilute the corrosive is not recommended. Gastric lavage is not recommended.

Signs of airway compromise including decreased level of consciousness, stridor, change in voice, inability to control oral secretions necessitate intubation and mechanical ventilation. IV fluids are often needed to maintain hydration and replace insensible water losses.

Endoscopy should be done within the first 24–48 hours of ingestion as subsequent wound softening increases the risk of perforation.

[1] Endoscopically inserted nasogastric tubes can serve as a stent to prevent esophageal strictures as well as allow tube feedings.[1] A CT scan, often enhanced with contrast, can also be used to evaluate injuries.[1]

### ▶ Surgical management

Surgery in the acute stage involves removal of the necrotic tissue of esophagus and stomach. Sometimes removal of entire stomach is needed if the tissue damage is more ( Gastrectomy). In such surgical procedures nutrition is taken care by a tube introduced in the jejunum ( feeding jejunostomy).

The most common surgical methods of treatment in children include esophageal dilation and esophageal replacement as less commonly implantation of an esophageal stent. Esophageal replacement is done using stomach or large intestine (colon). Stomach can be transposed as a whole ( Gastric transposition), tube may be made from stomach (gastric tube), or right or left sided large intestine is taken in to chest to unite with esophagus in the neck.

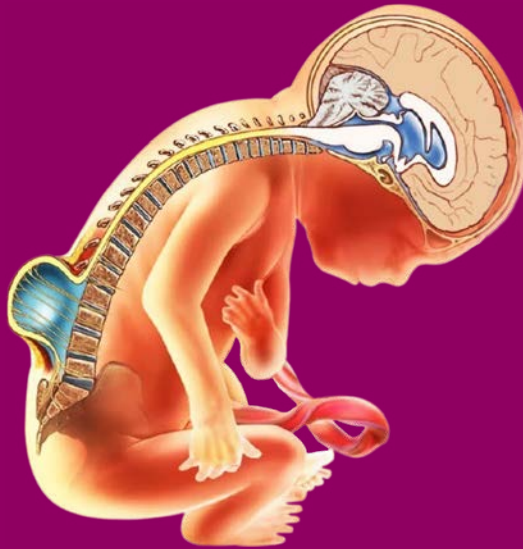
### ▶ Prevention

Preventative measures have been recommended that are intended to decrease the risk of accidental ingestion of caustic substances including

- Stringent legislation is necessary for curtailing the sale of caustics in unlabeled containers and limit unrestricted access to dangerous corrosive agents.
- The packing of these agents should be made childproof to prevent accidental ingestion by children.
- Parents need to be educated to keep household corrosives safely away from children. Keeping caustic substances in

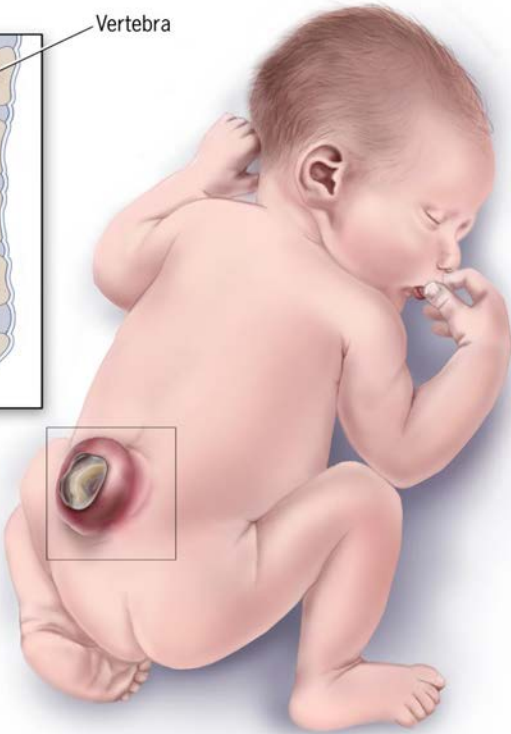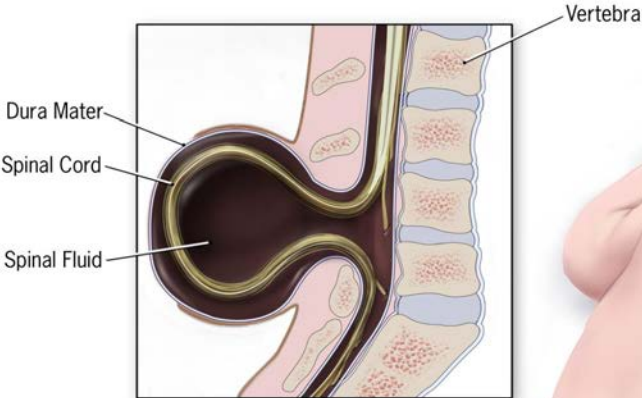
locked cabinets or on upper shelves out of the reach of the children.

- Not storing chemical substances in food or drink containers
- Not keeping large amounts of detergents in the home
- In the labs and places where caustic substances are used , the Parents should not leave the children alone.
- Keeping the phone number for poison control in the home for emergency purpose.
- Keeping caustic substances in labelled containers.



## SPINAL DYSRAPHISM IN CHILDREN

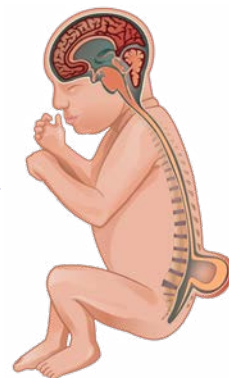# Spina Bifida (Open Defect)





## SPINAL DYSRAPHISM IN CHILDREN

During 9 months period of pregnancy, the gradual growth of the baby is like an amazing journey. It is not only amazing but also complex. During this complex and coordinated growth period anything can go wrong at any stage leading to birth of babies with congenital anomalies. Some of these anomalies can affect the developing spine and spinal cord. They can occur anywhere along the length of the entire spine. They can occur in various forms. All these anomalies combinedly are called as– Neural Tube Defects (NTD). They are also called -spinal dysraphism. The incidence of these anomalies is 5-7 cases per 10,000 live births. Slightly more common in female babies. Once the babies are born, these anomalies should be evaluated and corrected at the by the experts in the field. Nutritional deficiency ( folic acid) during the early pregnancy is one of the main reasons for the development of these anomalies. That is the reason for these anomalies to occur more in mid and lower socio-economic strata.



### ▶ Problem starts in the first month itself

The spinal cord forms between 17-30 th day after conception ( 4-6 weeks after first day of the womens last menstrual period ).it continues to develop for several years after birth. It is formed in four stages. Neural plate,neural groove ,neural tube and spinal cord formation. First there is a thickening of the cells on the midline of the back to form the neural plate. The lateral edges of the neural plate then rise to form neural folds. The neural folds move towards each other and meet in the midline, fusing to form the neural tube which is the precursor of the brain and spinal cord.The cranial end of the neural tube forms the brain ,the distal end of the neural tube forms the spinal cord. Any error in this nervous system development in the first four weeks of foetal development can lead to various types of spinal dysraphism.so, spinal dysraphisms and Hydrocephalus will have their origin in the first month of baby formation itself.

### ▶ Why these spinal cord anomalies occur ?

The exact reason why they develop is not known. It can happen in random. In some it runs in families ( Hereditary). Gene defects, gene-environment interaction ,cigarette smoking can increase the risk of development of neural tube defects. Majority of cases are due to nutritional deficiency during pregnancy like folic acid ( Vit B9 deficiency ) deficiency . supplementation of folic acid during pregnancy period has reduced incidence of neural tube defects by 70%.

### ▶ Spectrum of spinal formation defects.

Spinal dysraphism is a condition where the spine and spinal cord,do not form properly during pregnancy. The spine and spinal cord are exposed to the surrounding environment . these defects can be visible or invisible. In the visible form the defect is seen on the surface of the skin and in invisible form, the defect it cannot be seen and it is concealed under the skin.

Spinal dysraphism can occur in various forms. It can be Spina bifida occulta- in which there are one or more vertebrae malformed and the surface of the malformed vertebra is covered by skin, no neural tissue will be projected out. Meningocele- where the spinal fluid and coverings (meninges) project out without neural tissue, and Myelomeningocele- where the spinal fluid and coverings (meninges) and neural tissue also project outside covered by skin or thin membrane. Sometimes fat grows along with the spinal defect -it is called lipomeningocele. If the large part of the spinal tube is not closed and laid open, it is called -rachischisis. This can affect the brain area also. Part of the skull may not form well and brain tissue will project out -called encephalocele. These are the more severe forms of spinal formation defects.

### ▶ **Problems with spinal dysraphism**

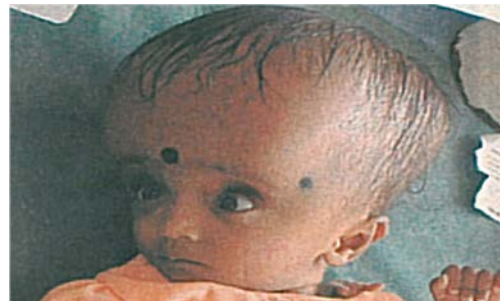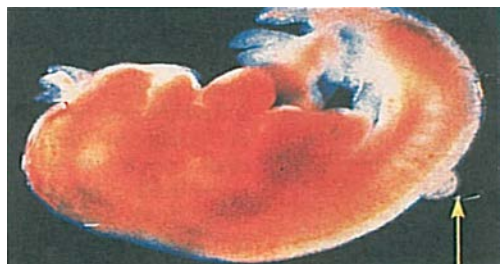All the nerves which control our body will go through the back spine and come through the spinal cord. So, when there is a defect in the formation of the spine or spinal cord, it will affect a variety of organ systems and interfere with their function. The extent of the neurological deficit will depend on the extent of involvement of the neural tissue. More commonly the spinal defect occurs at lower back leading to interference with the function of legs, urinary bladder and bowel. In some children, there is loss of sensation in the legs, paralysis of one or both legs, shortening of one leg, bending of the spine and gait defects can occur. In others, constipation or urinary incontinence can develop when bladder & bowel nerves are involved. The severity depends on the extent of nerves which are involved. In some cases along with these, associated problems can occur like collection of fluid in brain and ventricles (Hydrocephalus) or brain tissue may move down and herniate into the spinal cord (Arnold-Chiari formation).

### ▶ **How to detect and confirm these spinal defects.**

Spinal dysraphisms can be detected with accuracy by TIFFA scan done around 20-24 weeks. With the latest advanced ultrasound techniques, the spinal defects can be detected and their effect on organs like bladder can be seen to a reasonable level. After birth, most of the spinal defects will be visible to the naked eyes. Their extent and severity can be assessed by spinal X-rays, ultrasound examination, MRI study of the spine and CT scan brain. The fluid collection in the brain can be assessed by -Neurosonogram test.

### ▶ **Surgical correction**

Most of the visible spinal dysraphisms can be corrected by surgery. During surgery the projected nerve tissues are carefully placed back into the spinal canal, the overlying membranous coverings and tissues are



closed in 3 layers in a water tight manner ( repair of myelomeningocele). If there is any fluid collection within spinal cord it will be drained out ( syringomyelia). Fluid collection with in the brain ( Hydrocephalus) either at birth or developed later can be corrected by a shunt surgery. In Hydrocephalus ,the fluid collection within the brain ventricles, can compress the brain tissue . to avoid this brain damage a shunt tube is introduced in to the brain and it is run under the skin and placed in to the abdomen in a one way drainage manner. So fluid collected in the brain will drain in to the abdomen preventing the brain damage. With the advances in neurosurgical equipment and techniques, today spinal dysraphisms can be corrected with good results. But it is always important to prevent the development of these anomalies.

### ▶ Message to the prospective mothers

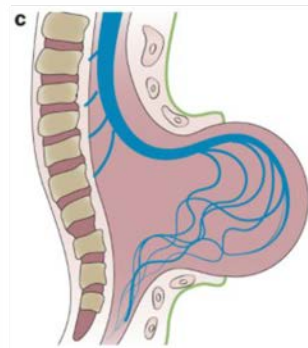
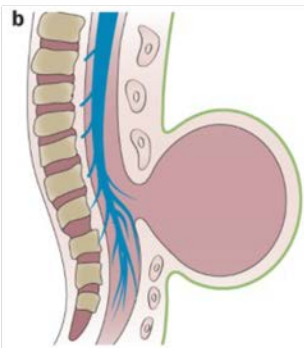
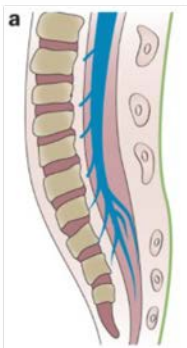
Some of these spinal defects are caused by chromosomal anomalies. But most of the cases are due to folic acid deficiency in the early part of the pregnancy. By scientific studies, it is proved that upto 70% of the spinal defects cases, can be reduced by giving folic acid in the early part of the pregnancy. Folic acid is a B vitamin ( vit B9) . It helps the body to make healthy new cells. Everyone needs folic acid. For women who may get pregnant, it is really important. Getting enough folic acid before and during pregnancy can prevent

major birth defects particularly brain and spine.

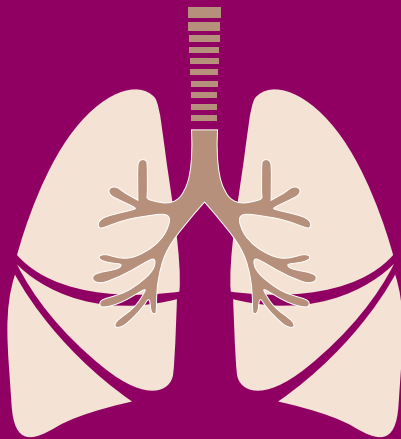
Foods with folic acid in them include:Leafy green vegetables,Fruits,Dried beans, peas, and nuts,enriched breads, cereals and other grain products

Usually the prospective mothers will start taking folic acid after they get confirmed that they are pregnant. It will happen after one or two missed periods. By that time the babys spine is already formed . So it is always advisable for the prospective mothers to take folic acid supplements at a time when they are planning for pregnancy. It is advised to take folic acid supplements 1 month before pregnancy to 3 after getting pregnancy in a planned manner. This will reduce the development of spinal defects by 70%. The dosage of folic acid supplement is 400 micrograms ( 0.4 mg) per day. Suppose if the previous pregnancy is already affected with neural tube defects, the dosage recommended is 4000 micrograms (4 mg )per day.

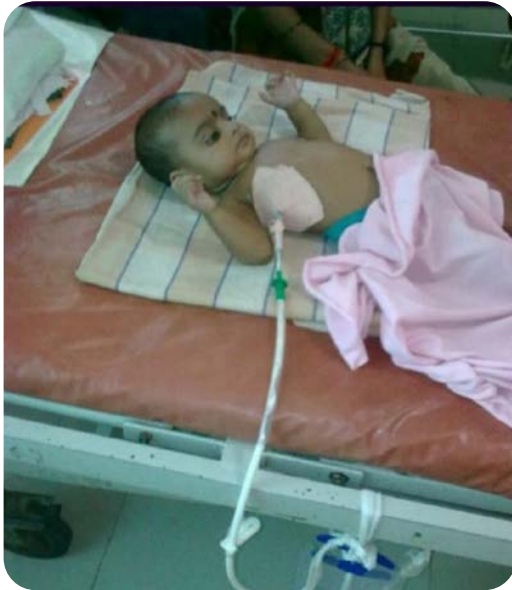Along with folic acid supplements, diet rich in folic acid also to be taken regularly. In advanced countries folic acid fortified milk and biscuits are available. In our country also ,the folic acid fortified food should be made available freely along with awareness like iodinated salt. This will reduce the occurrence of neural tube defects development to a large extent.







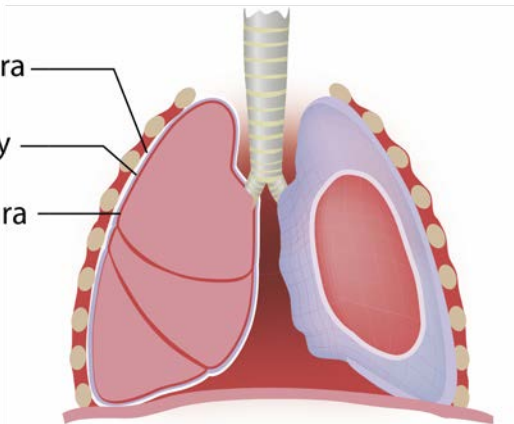
## EMPYEMA THORACIS IN CHILDREN



Parietal pleura

Pleural cavity

Visceral pleura



Rakesh, a five years old boy developed fever, cold and cough. parents have started him on medications advised by their family physician. With in 3 days, the symptoms have become evere and high swinging temperatures have developed. Breathing became difficult. He was aken to a pediatrician, who told them that Rakesh had acute pneumonia. He was admitted in the hospital After 2 days doctors told the parents that child had necrotizing pneumonia with empyema and he needs surgical intervention to clear the pus in the chest. Parents got panicked and shocked.

What is this empyema ? How can a simple fever with cough & cold leads to surgery ? Can y child in such a serious condition withstand the surgical procedure ? How will be his quality of life after chest surgery.?

In cold weather months and in early summer - many children will get lung infections. Some of them, will develop empyema (pus in thorax). This article will through light on doubts raised in parents minds about empyema thoracis.

### ▶ What Is Empyema ?

Empyema thoracis is an accumulation of pus or infective fluid within the thoracic avity. Amount of purulent collection and thickness of pus, varies with the stage of the disease and causative organism.

### ▶ How Empyema Develops ?

Our lungs are well protected by the chest wall. There is a thin (covering) layer present over the lungs called **pleura**. This **pleural** layer contains two separate layers -outer layer (parietal pleura) and inner layer (visceral pleura). There will be minimal fluid

between the layers (pleural fluid) which is nutritionally rich protein fluid with little white cell defence population. The function of this fluid is lubrication for lung surfaces when the lungs move during respiration. Normally this pleural fluid is very minimal. It is continuously produced by the visceral pleura and absorbed by the parietal pleura.

This fluid amount increases due to excessive pleural fluid production, when ever there is infection in the adjacent lung lobe. This is a reactionary fluid developed due to spread of infective activity from lung to the visceral pleural layer. This outpoured fluid is called - Pleural effusion as the volume is more than what a parietal pleura can absorb.. it is initially sterile without infection. This pleural fluid collection which develops with in 48-72 hrs are small, sterile with rich WBC. If the pneumonia remains untreated the amount of pleural fluid increases with time due to endothelial injury, increased pleural permeability and pleural edema.

Later with the spread of bacteria from the adjacent infected lung lobe or bursting of lung abscess cavity, the bacteria gain access to the pleural fluid. with the entry of bacteria the sterile pleural fluid will turn in to pus. This bacterial invasion will further increase the pleural fluid output. This fluid collects with in the two layers of the pleura. The entire pleural space will be filled with pus, which leads to compression, collapse and non-expansion of the lung on the same side. If proper treatment is not intiated, the infection progresses, pus will become thickened, pleural cavity becomes loculated due to fibrin deposition.(loculated empyema). The thickening of pleural fluid is due to increased plasma proteins in pleural collection and decreased fibrinolytic activity

due to inflammatory injury. This leads to deposition of dense layer of fibrin on both layers of pleura. Fibroblasts move in to the pleural space leading to formation of loculations. This leads to the development of thick purulent peel over the lung (chronic empyema). The Empyema is called, **SIMPLE EMPYEMA** -when the pus is thin, free flowing within a single locule. It is called **COMPLEX EMPYEMA** – when the pus is thick,loculated due to multiple septa. This accumulation of pus - with in the chest cavity will produce high fever, cough and respiratory distress. Patient will become toxic and sick at this stage.

### ▶ Presentaion of Empyema

Epyema is a common complication of pneumonia in children. More common in children of poor socio-economic status and children below 3yrs of age. Clinical signs vary according to the causative organism, age of the patient, type of the antibiotic therapy used and the stage of the effusion.

Common symptoms are chills, fever, dyspnoea,chest pain, night sweats, cough, malaise and increased sputum production. On physical examination, decreased breath sounds, splinting of the chest on the affected side, preference to lie on affected side will be present.

### ▶ Stages of Empyema

The process of evolving empyema will go through three indistinct stages. They are not divided sharply. Gradually one stage merges in to another with progression depending on the infecting organism.

**First 1 -3 days** of disease is called **EXUDATIVE** stage. This is a reaction to the pneumonic process. There is outpouring of the fluid from the inflamed pleural layers. During this stage the reactionary fluid is very thin and lung is readily reexpandable. It is difficult to differentiate exudative stage from

simple pneumonia. As the fluid collection increases,the respiratory symptoms will become severe. This stage can be diagnosed and confirmed by x-ray chest, ultra-sound examination of chest and needle aspiration under ultra-sound guidance.

**4 -14 days** of disease is called **FIBRINO-PURULENT** stage.. in this stage, large number of white blood cells and fibrin accumulate in the effusion. Fluid collected will become more thick, more purulent, tendency towards formation of loculations and a thick peel over pleural membranes limiting the lung expansion.

**After 14days (ORGANISING stage)** in this stage fibroblasts grow in to the exudates on both visceral & parietal pleura, producing an inelastic membrane – the PEEL. Thickened peel will prevent the entry of any anti-microbial drugs in to the pleural space. The thickened peel will prevent any expansion of the lung leading to –**Trapped Lung**.

### ▶ Diagnosis

- **X-RAY CHEST** – is the primary investigation. Large volumes of fluid collection can be easily diagnosed in AP view chest x rays. It may reveal the status of underlying lung. Pleural thickening and loculations also can be noted in chest xrays.
- **ULTRA-SOUND CHEST** – is a very useful tool for diagnosing empyema, for ultrasound guided aspiration or catheter placement in to the empyema cavity. It helps in identifying the stage of empyema by demonstating loculations and non-expanding –trapped lung.
- **COMPUTED TOMOGRAPHY (CT SCAN)** empyema appears smooth, rounded or elliptical collection in chest on CT. thickened pleural layers are separated by pus giving rise to **SPLIT PLEURAL** sign on CT. it gives better delinieation of stage



of empyema, thickness of pleural and status of underlying lung parenchyma.

- **THORACOCENTESIS** aspiration of pleural fluid for analysis is called thoracocentesis. If the fluid is thin and free flowing it can be done directly. If it is loculated thoracocentesis should be done under ultra-sound guidance. Characteristics of the fluid including odour should be noted. Ph, WBC count, Glucose, LDH levels, are done on pleural fluid. Grams stain on pleural fluid will demonstrate the organisms directly under microscope.

### ► **Complications of Empyema**

If empyema is left untreated or incompletely treated, it will lead to complications. In small children it can lead to – septicemia (spread of infection to blood) which can be fatal. In grown up children, it can lead to loss of function of affected lung, due to trapping of lung by thickened membranous fibrin peel. It will lead to necrosis of underlying lung lobes if left unattended. If the infection spreads to the chest wall - it will lead to ugly chest wall deformity particularly in young girls. Necrotic pneumonias may produce a condition called – Broncho-pleural fistula. In this condition the air carrying tubes connected to lung parenchyma will get opened up leading to continuous air leaks leading to respiratory distress.

Empyema will produce lot of morbidity in the form of ill health, fever, cough and respiratory distress. It will lead to loss of schooling.

### ► **Management of Empyema.**

Effective therapy of empyema involves - Control of infection, Drainage of pus and Expansion of the lungs. Management of empyema depends on the stage of empyema, presence of loculations, amount and thickness of the pleura & pleural fluid.

**Antibiotics** - should be given in all cases of empyema, depending on suspected etiological agent. Antibiotics should be changed later, on the basis of culture & sensitivity test done on aspirated pleural fluid. Tuberculous empyema presents a special situation. Along with antibacterial, anti-tuberculous drugs, corticosteroids are given to reduce effusion and its sequelae.

**Empyema drainage-** is a major component of empyema therapy. Purulent fluid can be drained by repeated needle aspirations, chest tube introduction, pig tail catheter introduction or by video assisted thoracoscopic surgery (VATS) drainage. The mode of drainage depends on the thickness level of the pus and stage of the disease.

If the pus is thin –either Repeated needle aspirations or small bore percutaneous catheter drainage should be used. If the pus collection is small, CT guided aspiration is advised. Chest tube with underwater seal drainage is used, if the pus is slightly thick but free flowing in a single cavity without loculations. Chest tube should be kept till the drainage is less than 20 ml per day colourless fluid and lung is completely expanded on x-ray chest.

**Surgical modalities** of treatment-VATS (video assisted thoracoscopic surgery) is quite effective in lysis of adhesions in multiloculated effusions and removal of fibrinous pleural peel. A limited decortication can be done when the fibrinous pleural peel is thin. It will help in localizing area of collection, under vision drainage of pus, and proper placement of drainage catheters and tubes. VATS is not useful in organizing stage, where the pleural thickening is more.

**Thoracoscopic debridement & drainage-** it is quite effective in multiloculated empyema. It helps by breaking all the loculi converting multiloculated pleural cavity into a single cavity. Thoracic cavity is then irrigated and

entire purulent fluid is sucked out. Under vision a chest tube is placed.

**Open thoracotomy and decortication** – is the procedure reserved for cases where the pleural peel is very thick leading to trapped lung. when the both visceral and parietal pleura are thickened very much and acting as a restricting layer, not allowing the lung to expand. In this procedure, both pleural layers covering the lung and chest wall are removed completely so that there wont be any restriction on lung expansion. This is done through wide cut given on lateral chest wall. If underlying lung lobe is destroyed, it is also removed along with the decortication(decortications + lobectomy).

So, overall if the pus is thin no loculations-treatment of choice is chest tube drainage along with antibiotics. If pus is thick and loculations present, the treatment of choice is VATS by which we break the loculi and we can give good irrigation of infected pleural cavity. If the empyema is in organizing stage with thick restricting peel over lung, treatment of choice is open postero-lateral thoracotomy + decortications. In any stage if underlying lung lobe is damaged,it should be removed (lobectomy).

### ▶ **What is Thoracoscopy.?**

Video assisted thoracoscopy is a minimally invasive surgical technique used to diagnose and treat the conditions in the chest. It is a form of key-hole surgery. It allows surgeons to see inside the chest and lungs and allows to do a number of chest surgical procedures.

During VATS procedure, a small tiny camera (thoracoscope) and surgical instruments are inserted in to the chest through several small incisions.(3mm -5mm). The thoracoscope transmits the images of inside view of the chest to a monitor outside, guiding the surgeon in performing the surgical procedure. The advantages of this procedure is -small cuts on chest, early healing and recovery. No retraction of rib cage is done in VATS. So no risk of rib fractures or shearing of nerves. Leads to less pain and early recovery. As procedure is done under magnification, all inaccessible areas also can be approached. Procedures can be done under vision with more clarity.

Surgeons use this procedure to do - lung biopsies, lung lobectomies and pneumonectomy,decortications or empyema debridement,esophageal surgeries,hiatus hernia repair. Removal of excess fluid or air around lungs. Surgery to correct gastroesophageal reflux, Thymus gland surgeries, Surgery for excess sweating (sympathectomy).

### ▶ **Long Term Outcome of Empyema Cases**

In most of the cases, following an effective treatment of empyema, the lonterm lung functions will return to normal. Even in cases where lung lobes are removed, the other remaining lobe or lobes will take over the function. There wont be any deficiet of lung function noted. Some of the Open thoractomy cases will experience, nerve pains or numbness along the operated area. No restriction of shoulder or chest wall movement is noted.

## Key Points :

Empyema is a common complication of pneumonia.

Children of poor socioeconomic status and below 3yrs are more commonly affected.

*Staphylococcus Aureus* is the most common causative organism.

A high index of suspicion helps in diagnosis.

x-ray chest, ultrasound and CT scan are the most useful modalities for diagnosis and follow up.

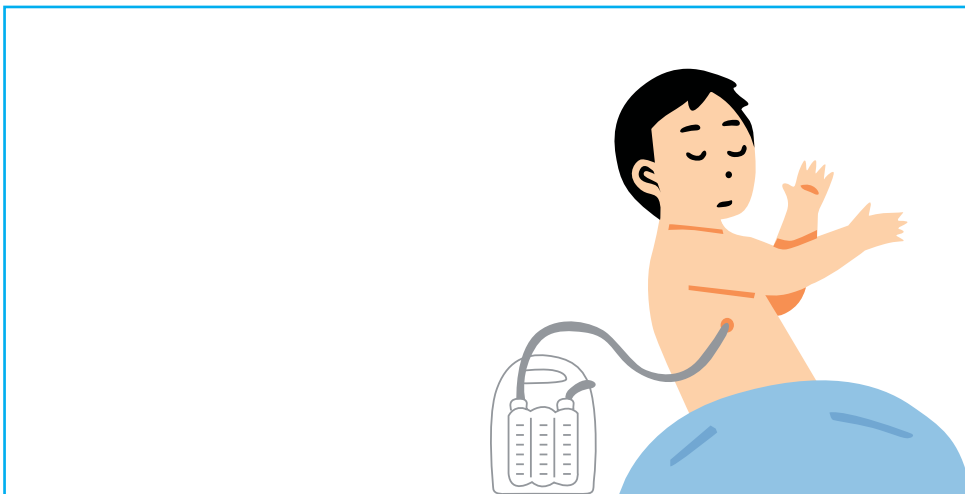Thoracocentesis and pleural fluid analysis helps in deciding the modality of treatment.

If empyema is not loculated – antibiotic coverage + chest tube drainage is enough.

For multiloculated empyema, Videoassisted thoracoscopic debridement will do good job.

Chronic organizing empyema needs open surgical decortication.

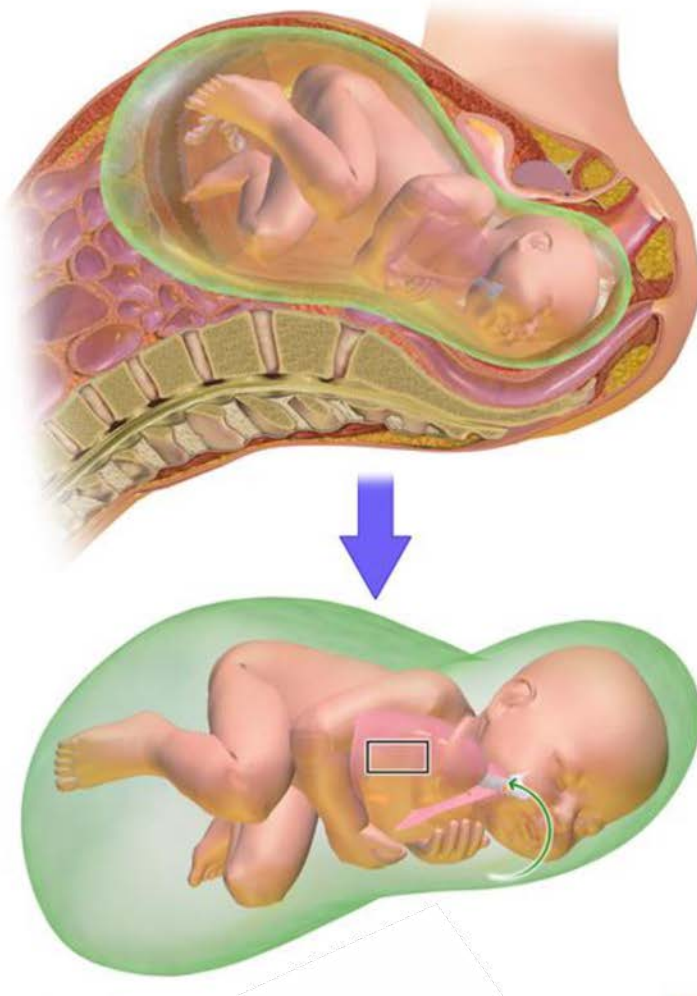
Longterm lung functions are normal in majority of the treated empyema case







## MECONIUM STORY





## ▶ Normal Meconium

Meconium is the fancy name for the first stool, the baby passes. It is the earliest stool. It contains the material baby ingests during the time it stays in the womb. It is a collection of peeled off intestinal lining cells, intestinal secretions, early temporary, lanugo hair, & waste products from ingested amniotic fluid. The word, Meconium comes from the mekon meaning poppy seeds because it resembles the raw poppy powder. It gets accumulated towards the beginning of second trimester, then gets accumulated in the colon until birth.

Usually passed in the first 24 hrs after birth and should be passed within 48 hrs. If it gets delayed beyond 48 hrs it is called – Delayed Passage of Meconium and needs doctor's consultation. Meconium stools are large, sticky and thick dark greenish in colour. It is difficult to clean the meconium stools from the baby's body surface. They do not smell bad. Meconium stools are sterile, as bacterial colonisation does not occur. Meconium stools are quickly followed by transitional stools, which are greenish in colour by the time the baby is 3-5 days. and they change to regular milk or breast feeding stools on about day six which is yellow in colour.

## ▶ Meconium if it Releases Before Birth Outside Baby in to the Womb

- **Meconium Staining**

A baby can pass meconium before birth leading to meconium stained amniotic fluid and a meconium stained baby. Meconium staining on its own is not dangerous, though it can be frightening to see baby covered in meconium at birth. It can become a problem if the baby breathes & aspirates meconium into

lungs. It is noted in about 12-20% of deliveries and is much higher in post dated births up to 40%. It is a sign of acute or chronic fetal hypoxia.

Meconium staining can sometimes happen normally. Most of the time it occurs in babies who are stressed, like prolonged labour, post dated pregnancies (beyond 40 weeks), large for gestation babies, babies born to diabetic mothers, hypertensive mothers. It is also noted in babies with mothers having alcohol ingestion & smoking habit.

- **Meconium Aspiration Syndrome**

Meconium aspiration syndrome is a condition in which a baby develops breathing problems because the baby inhaled meconium into the lungs while still in the womb, at the very end of the pregnancy or during the delivery. When meconium gets into the amniotic fluid baby will breathe it in to the lungs before, during and after the birth. It happens in 3-9 % of meconium stained baby deliveries. Meconium is a lipid and protein rich substance that is irritating to covering membranes of the distal airways resulting in chemical pneumonitis. It later leads to bacterial pneumonitis leading to a serious condition.

Some babies pass meconium in the womb or during delivery and do not develop meconium aspiration syndrome or any other problem. 90% of babies born through meconium stained amniotic fluid do not develop Meconium Aspiration Syndrome (MAS). However in

those babies who do develop MAS it can be mild, or it can be very serious and life threatening.

### ▶ Risk factors for meconium aspiration syndrome

- Post dated babies : babies born at gestational age more than 41 weeks
- Small for gestational age babies (babies who have low birth weight compared to the weight appropriate for that gestation period)
- Difficult delivery
- Fetal distress
- Preeclampsia
- Oligohydramnios
- Peripartum infections
- problems with placenta / umbilical cord

### ▶ Diagnosis of meconium aspiration syndrome (MAS) syndrome

- Amniotic fluid is meconium stained (green)
- Baby has meconium stains
- Difficult breathing
- Cyanosis
- Baby is limp/ dull
- Air leaks in to chest (pneumothorax)
- Can develop persistent pulmonary hypertension
- X ray chest is diagnostic

Vigorous suctioning of the mouth & nose was done for babies with meconium staining after the delivery of the head before the delivery of shoulders. In babies with vigorous muscle tone and good cry with good respiratory effort, this suctioning is not necessary.

(American academy of paediatrics & American heart association recommendations -2015)

Management of meconium aspiration syndrome, depends on duration of exposure to meconium, thickness of meconium, amount of meconium inhaled, respiratory efforts of baby. Most of the babies with MAS, will recover well. a few cases need Neonatal intensive care, oxygen support, ventilator care, surfactant administration, inhaled nitric oxide therapy and ECMO. In severe cases of MAS, baby will die inspite of all efforts.

### ▶ Release of Meconium Inside The Babys Abdomen Before Birth

#### • Meconium Peritonitis

Occurs when there is rupture of the bowel before birth. The meconium leaks out in to the space that surrounds the bowels, leading to inflammation of the lining of the abdomen (Peritonitis). It will be diagnosed before birth, if areas of calcium deposits in the peritoneum on ultrasound. It is diagnosed after birth if the baby is born with abdominal distension and vomiting.

The reasons for the rupture of the bowel are.. volvulus (twisting of the bowel), atresia of the bowel (where small bowel ends blindly without continuing with the remaining part of the bowel), intussusception (the bowel telescopes into itself). meconium peritonitis needs surgical intervention immediately after birth.

### ▶ Delay In Passage of Meconium

Normally, majority of healthy full term babies (90%) pass their first stool within 24 hours of being born & all term newborns should pass meconium within 48 hours. If the baby does not have a spontaneous stool on their first day or two of life, it could be a sign



that something is wrong & physician should consider all important causes. Premature neonates may take more time.

Any infant with delayed passage of meconium accompanied by vomiting, poor feeding or abdominal distension should be evaluated urgently with a high index of suspicion for neonatal bowel obstruction.

## ▶ Surgical Causes

- **Ano-Rectal Anomalies**

It is important that the physician should carefully examine the neonates perineum for any evidence of congenital anorectal malformations. In anorectal anomalies, the bowel does not open normally through anal orifice, it will end high above at various levels above the normal orifice on skin. The finding may be anorectal malformation with or without fistulous communication to the perineum. Examination & evaluation of ARM requires pediatric surgical expertise. Ano-rectal anomalies are divided in to high / intermediate & low anomalies based on their relation to the muscle of continence –levator ani muscle.

Low anomalies are treated by a single stage –perineal anoplasty. Intermediate and high anomalies are treated by initial diversion of feces through colostomy and definitive procedure (pull through procedure) after 3-6 months.

The main concern in anorectal anomalies is the retaining controle power (continence). In low anomalies 100% continence will be retained while it is less in intermediate anomalies (80%) & high anomalies (30-40% continence).

- **Intestinal Obstruction (Atresia)**

In intestinal atresias, a segment of the bowel is absent due to vascular accident during development. It can affect any part of the bowel but commonly involves the small intestine. Babies born with intestinal atresia will present with abdominal distension, bilious vomiting and failure to pass meconium. The intestinal atresias should be corrected by surgery.

- **Hirschsprungs Disease**

HD affects 1 in 5000 live births affecting males more than females (4:1).

In hirschsprungs disease, congenital absence of ganglion cells leads to a defective motility in the affected intestine leads to a functional obstruction. In normal embryonic development, nerve cells migrate caudally from brain to get distributed along the entire gastrointestinal tract. This is called enteric nervous system. This happens between 5<sup>th</sup> to 12<sup>th</sup> weeks of gestation. Incomplete or absent migration of nerve cells leads to Hirschsprungs disease.

Hirschsprungs disease most commonly affects the last parts of the large bowel (rectosigmoid area). The classical clinical presentation in the neonate is delayed passage of meconium with abdominal distension. In some neonates this functional obstruction with stasis of stool will lead to infection (enterocolitis) with vomiting, diarrhoea, abdominal distension and & shock. Physical examination reveals a rectum that is empty. an explosive release of stool and gas follows digital rectal examination. This disease is confirmed by contrast study of large intestine (Barium enema) and rectal biopsy.

Surgical treatment is the definitive therapy for Hirschsprungs disease.

surgery can be done in one stage or two stages. The surgery typically involves diversion of stool by making a opening in the proximal segment of bowel containing nerves. After a gap of 3-6 months after the proximal bowel is sufficiently decreased in size, a pull through surgery is done which involves bringing the bowel segment containing nerves down.

- **Meconium Ileus**

Meconium ileus is a bowel obstruction that occurs when the baby's meconium in the intestine is thicker & stickier than normal, creating a blockage in a part of the terminal small intestine called ileum. Most of the babies with meconium have underlying cystic fibrosis disease. After birth babies present with abdominal distension and bilious vomiting and no passage of meconium. The treatment of meconium ileus is mainly surgical and in staged procedures. Initially an ostomy (ileostomy) was done after resection of grossly dilated segment, to bring the sticky meconium out. The bowel is reconnected 3 months after the sticky meconium is passed out and bowel is clear.


- **Meconium Plug Syndrome**

It is a transient disorder of the newborn colon characterized by delayed passage of meconium and intestinal dilatation. It is due to functional immaturity of colon. The colonic obstruction is due to an obstructing meconium plug. It affects the left colon with meconium plugging the bowel distal to this segment. It is also called small left colon syndrome.

Contrast enema demonstrates the retained meconium as a filling defect or a plug that produces a double contrast effect. The initial treatment is non-surgical includes rectal stimulation and contrast enema.

- **Meconium Pearls**

In low type of anorectal anomalies, the meconium which is leaked through fistulous opening will get solidified and forms like greenish /whitish pearls in the midline from normal anal site to the tip of the penis. Meconium pearls indicate the anomaly is probably low.

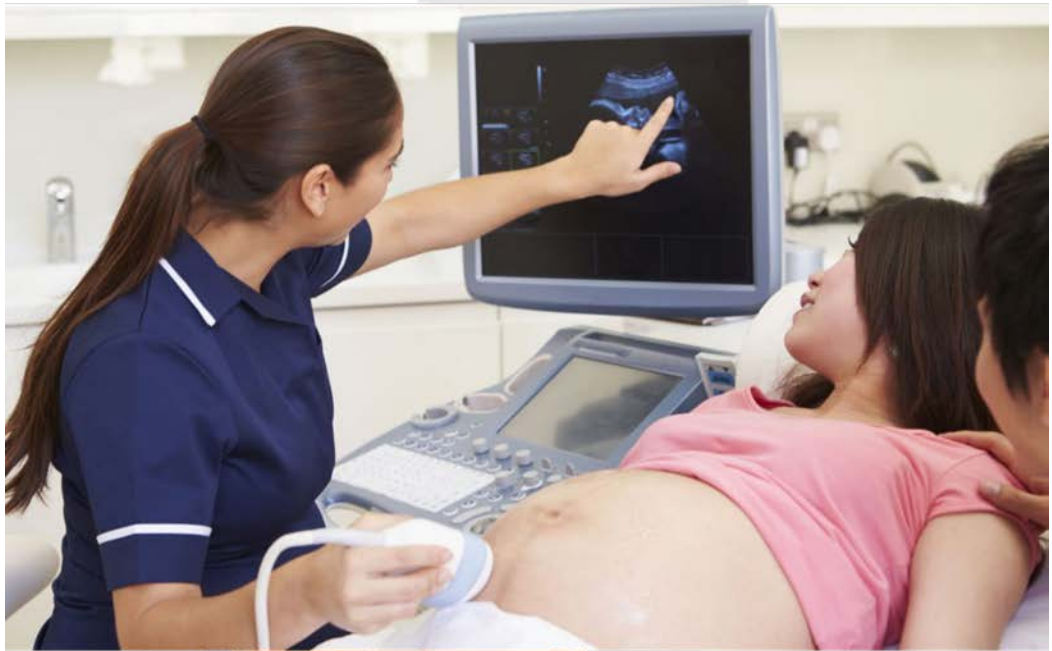

## Key Points :

The first motion (stool) has to be passed within 24-48 hours after birth, otherwise it is a cause of concern. It has to be taken seriously.



## **ANTE NATALLY DETECTED ANOMALIES - WHEN THE PARENTS SHOULD GET WORRIED?**



## ANTE NATALLY DETECTED ANOMALIES - WHEN THE PARENTS SHOULD GET WORRIED?

(AWARENESS ABOUT THE AFFECT OF CONGENITAL ANOMALIES ON THE BABY WILL HELP IN DECISION MAKING)

- o Mrs. Saritha is shocked and disturbed, when her obstretician,who is doing her regular antenatal check ups told her that tha baby she is carrying is having enlarged head and fluid in brain may be getting collected. (Hydrocephalus)
- o The dreams of Mrs. Laxmi were shattered when she heard that the baby she is carrying is having an enlargement of one of the kidneys. This is conveyed to her by her obstretician after antenatal scan. (Hydronephrosis)
- o Mrs. Karuna has approached a childrens surgeon,to know the status of her baby she is carrying, who is found to have a defect in the back spine (spinal Dysraphism)

The detection of these anomalies will lead to lot of tension, anxiety and will leave lot of doubts in the minds of expectant parents. The pregnant mother has to carry the rest of the pregnancy with uncertainty. There is an urgent need to know certain facts about these lesions which are detected ante-natally around 18 - 28 weeks.(targeted imaging for fetal anomalies -TIFFA scan)

### ▶ Facts

- Not all antenatally detected anomalies are dangerous.
- Some of them, may regress over a period of time before delivery.
- Most of the lesions, even if they persist -will have a benign course.
- Most of the anomalies, which need surgery can be corrected with reasonable and acceptable results.
- Now pediatric surgery (branch which deals with postnatal correction of most of the antenatal anomalies) is a well established branch.
- Advances in anaesthesia has made surgery for newborn(neonatal surgery) with anomalies – a reasonable and safe option.



From a single cell to a baby in 9 months,is a developmental process that represents an amazing integration of a increasingly complex phenomena. This journey of 9 months is not without accidents. Some unfortunate parents are blessed with anomalous babies. These anomalies can be structural, functional or metabolic. Anomalies develops in the embryo between 3rd –to-8th week of pregnancy. The highest number of anomalies occur in 5th week of gestation. Anomalies can be single or a group of multiple anomalies. They can be minor anomalies or major anomalies. Minor anomalies serve as clues for diagnosing more serious underlying defects. The detection of these anomalies ante-natally will help the

pregnant mother in one way- that is - the treating doctors can plan a treatment plan that is safe for the mother and baby. But at the same time it will lead to a prolonged period of anxiety and uncertainty to the parents. So the parents should know which lesions are dangerous and which lesions will not cause much trouble.

### ▶ **How These Anomalies are Detected.**

Now there are several options available for assessing the overall foetal growth, and for detecting malformations. they include ultrasound, maternal serum screening, amniocentesis and chorionic villus sampling.

ultrasound examination..

Parameters noted by the U/S include - foetal age, growth, presence or absence of congenital anomalies, status of uterine environment, amniotic fluid quantity, position of placenta, and umbilical bloodflow. 3d and 4d scans are the still colour pictures of the baby in three dimensions. 4D scans (with time as the fourth dimension) are the moving 3D images of the baby. The best time for these scans is between 23 – 28 weeks. These scans show the baby's external and some internal features in more greater details. Tiffa scan... this is a targeted imaging for fetal anomalies. This is done between 18 – 23 weeks of pregnancy. This is like a usual ultrasound scan with the difference that it is done by experienced sonologist, who carefully do systematic examination of each part of the fetus to see if he can detect any major or minor anomaly.

### ▶ **NT Scan (Nuchal Translucency Scan)**

This scan is done between 11 - 14 weeks of pregnancy. Nuchal translucency is the collection of fluid at the back of baby's neck. NT scan measures the thickness of this fluid to assess the risk of baby having downs syndrome or chromosomal abnormalities.

### ▶ **Fetal Echocardiography**

is the test used to diagnose the foetal cardiac anomalies. Colour and pulse Doppler techniques can be used to detect bloodflow through the heart and great vessels.

### ▶ **Biochemical Screening**

All pregnant women should be given choice to undergo certain blood tests like alpha fetoprotein levels, triple marker tests to R/O certain anomalies

### ▶ **Chorionic Villus Sampling (CVS)**

This is done much earlier in pregnancy. between 10-12 weeks. CVS is performed by taking a tiny bit of tissues from chorionic villi (part of placenta) under U/S guidance. The tissues is cultured and chromosomal analysis is done. It takes 2 -3 weeks to get the analysis results.

### ▶ **Amniocentesis**

this is done usually between 15 – 20 weeks antenatally. In this procedure, about 20ml of amniotic fluid which contains fetal cells is aspirated with a needle in the area away from the foetus under U/S guidance. From amniotic fluid- fetal cells are separated and grown in culture. Chromosomes from culture are examined under microscope for chromosomal abnormalities.

### ▶ **What Are The Options For The Parents ?**

When anomalies are detected the pregnant women will be taken care by obstetricians with special interest in high risk pregnancies.

a team of doctors including pediatric surgeons (who are going to correct the anomalies after birth) will

- review the results.

- Discuss the options available
- Explain possible outcomes from this anomaly
- Answer all the queries from parents
- Plan a treatment modality which is safe for mother and baby.
- Delivery should be done in a center where there are intensive care facilities available for both mother and newborn.

### **When the ante natal anomaly is detected, the options available are**

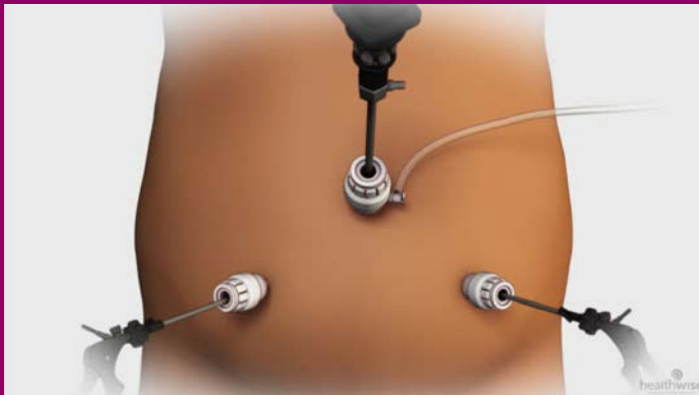- To terminate the pregnancy
- To continue the pregnancy, allowing the nature to take and tackling the anomaly after birth.
- To intervene and do procedures before birth on the foetus. (foetal interventions).

Minimal foetal interventions are popular and done with good results in cases like bladder outlet obstructions, where a shunt tube is placed in to fetal bladder and left in to amniotic fluid to bypass the outlet obstruction (vesico-amniotic shunt)

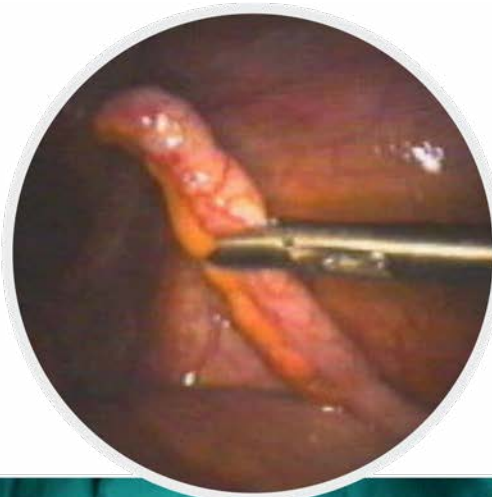Major foetal interventions like open foetal surgery are in experimental stage and are not standardized. They are done in selective centers at USA and Australia.



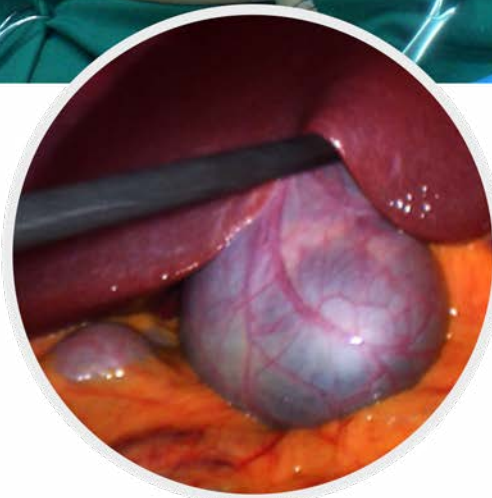
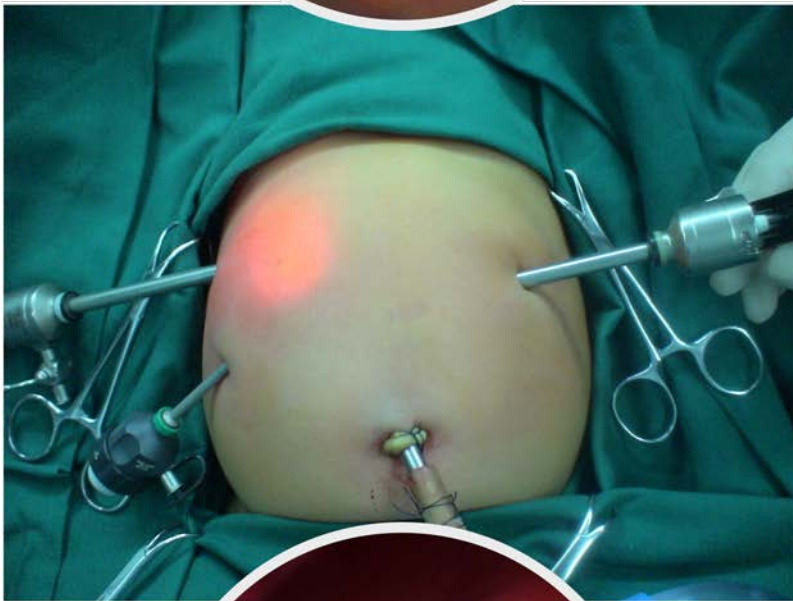


## LAPAROSCOPIC SURGERY IN CHILDREN



**Laparoscopic  
Appendectomy**



**Laparoscopic  
Cholecystectomy**

Laparoscopic surgery / Key Hole surgery or Minimal Access Surgery is completed with one or more small incisions instead of a large incision.

The surgeon passes a telescope with video camera through a small incision in to the body cavity. The surgeon then views the surgery on a TV monitor. Surgical instruments are then passed through other similar little incisions. The surgeon examines and operates on the area in question

by viewing the magnified images on a television. When telescope is used to operate on abdomen, the procedure is called laparoscopy. When used on chest the procedure is called thoracoscopy, used in bladder it is called vesicoscopy and when used in a joint, it is called arthroscopy.

Laparoscopy was first introduced in gynaecological surgery, later in general surgery. Laparoscopy in children surgery taken a long time in view of lack of small instruments, small capacity abdomen in children, thin abdominal wall which cannot hold trocars and lack of studies on safety of CO<sub>2</sub> insufflation in children was not established. All these myths are cleared and now laparoscopy is a reality in children. Pediatric laparoscopy has come a long way and now it is an established branch.

### ▶ How Laparoscopy is Being Done?

In all laparoscopic procedures, the primary port placement was by the Hassons open technique, in which under vision a trocar with cannula is introduced in to the abdomen through umbilicus. Then the trocar is removed, the cannula space will give access to abdomen for gas, telescope, or instruments. Through the gas insufflating port in the side of cannula, the abdomen was insufflated with a pre-warmed carbon dioxide starting at a pressure of 6mm Hg and slowly increased to 10-12mm Hg. This insufflation will raise the abdominal wall and create a operative working space. A 5mm 30 degree telescope is introduced in to the abdomen through the cannula. Then the working instruments are introduced under vision by viewing through telescope which is connected to the camera and monitor. 2mm & 5 mm instruments are used regularly for

pediatric purpose. Placement & number of secondary ports were dependent on the magnitude & type of surgery and operating area of interest. Triangularization is created & maintained during instrumentation, in which the camera port and instruments will form a triangle. A thorough look at all organs are done once the scope was inserted (diagnostic laparoscopy), then the procedure was completed depending on the pathology. After the procedure, the CO<sub>2</sub> gas is deflated through trocars. The minimal gas which is absorbed in to the blood during the procedure can get excreted through lungs.

### ▶ Advantages of Laparoscopy

- Minimal surgical trauma
- Better visualization with magnification
- Greatly reduced contact with body fluids
- Reduced adhesions development

- Reduced pain & analgesia requirement
- Reduced hospital stay
- Superior cosmetic results

### ▶ **Disadvantages**

- Initial cost of equipment
- procedural Cost is more than open procedure.
- long learning curve
- longer time than open procedure

Conversion to open procedure in case of difficulty, anomalous anatomy, or unsuspected pathology represents sound surgical judgement.

### ▶ **Procedures That Can Be Done**

Laparoscopy is mainly used for **four types** of surgical procedures i.e Diagnostic purpose, simple procedures, excisional procedures and reconstructive procedures. It can be used in abdominal surgeries, thoracic procedures, urological procedures & pelvic procedures.

**Diagnostic procedures** : in which laparoscopy is used to look for hidden pathology or Hidden organs. It is used mainly for diagnostic evaluation of unexplained abdominal pain, non-palpable undescended testis, evaluation of disorders of sexual differentiation, and in evaluation of abdominal masses.

**Simple procedures** : like inguinal hernia repair, ovarian cyst removal, abdominal lymph node biopsy and peritoneal or omental biopsy in TB abdomen. In these procedures, the surgical condition is simple, the procedural time is less and hospital stay is less.

**Reconstructive procedures** : this is the main core area of pediatric laparoscopic surgery. When the kidney is swollen due to obstruction to urinary outflow tract it is called -Hydronephrosis. To relieve the obstruction and to create a wide, funnel shaped & dependent un-obstructed flow of

urine, a procedure called Pyeloplasty is done. Laparoscopy gives a better vision & better access to perform this procedure. Now a days the gold standard approach for hydronephrosis is laparoscopic pyeloplasty. Laparoscopy can be used in other reconstructive procedures like ureteric reimplantation, choledochal cyst repair, and esophageal atresia repair.

**Excisional procedures** : like nephrectomy for non-functional kidney, removal of non-functional gonads, removal of tumor masses and removal of spleen in hematological conditions or trauma.

**Infective and inflammatory conditions** : like appendicectomy, meckels diverticulectomy, drainage of intra- abdominal abscess. The use of laparoscopy in these conditions will lessen the operative trauma, to give excellent wash of abdomen under vision even in inaccessible areas and lessens the chance of post-operative adhesions.

**Ostomies** : laparoscopy can be used to create ostomies (hole in the intestine or organ for drainage or feeding purpose). the ostomies done routinely are Gastrostomy for feeding purpose when there is swallowing difficulty, Jejunostomy for feeding purpose in complex procedures when normal oral route cannot be used or Nephrostomy to drain urine or pus from kidney when the urine in pelvis gets infected.

**Newborn surgeries** : laparoscopy is routinely done in newborns through 3 mm instruments for various congenital anomalies. These include congenital diaphragmatic hernia, diaphragmatic eventeration, malrotation of midgut & ovarian cysts in female newborns.

**laparoscopic Assisted Surgeries** : some procedures like non-palpable undescended testis, pull-through surgeries for ano-rectal malformations and Hirschsprung disease are being done with assistance through laparoscopy. In these procedures, laparoscopy is used to locate, mobilize and brought the

organ / bowel through proper route, to keep it in its normal location.

@ **vesicoscopic procedures** : in vesicoscopy, the bladder is distended with saline. The telescope is introduced into the bladder through cannula and like in laparoscopy the working instruments are introduced under vision into the bladder. Then surgeries like -ureteric reimplantation can be done under vision. To stop the urine going up (in vesicoureteric reflux), the ureter is disconnected and rerouted in a submucosal tunnel in the bladder (ureteric reimplantation). This will stop the urine

going in opposite direction. The advantage with vesicoscopy is less morbidity and early recovery.

@ **Thoracoscopic procedures** : if endoscopic procedures through introducing telescope through thorax, it is called thoracoscopy. The lesions of the thorax in children like – empyema thoracis, thoracic duplications, lung cysts and mediastinal lesions can be corrected with thoracoscopy. In this the patient is placed in lateral position and telescope is introduced in the mid axillary line. Other instrument ports are introduced under vision.

---

## ▶ Present Status

The role of minimal access surgery (MAS) in surgery of children is slowly emerging over the last two decades. The scope of MAS (laparoscopy) is to minimize the traumatic insult to the patient without compromise of the safety and efficacy of the treatment. With increasing experience and advances in miniaturized instruments the role of minimal access surgery in pediatric surgery has expanded and well accepted. With each advancing year, the instruments and optics are being refined and newer indications are getting added to the list of laparoscopically manageable childrens surgical conditions.

Minimal access surgery in children is widely accepted procedure now across the world. Advances in technology, training opportunities are helping these surgeries to become safe. Most of the childrens surgeries are now a days, being done safely done directly through laparoscopy or done with the assistance of laparoscopy. Public awareness about childrens laparoscopy is increasing.

In future, single port laparoscopy, flexible instruments which are manovarable in the abdominal cavity and pediatric staplers can change the face of laparoscopy in children.



Mobile : 98480 50565

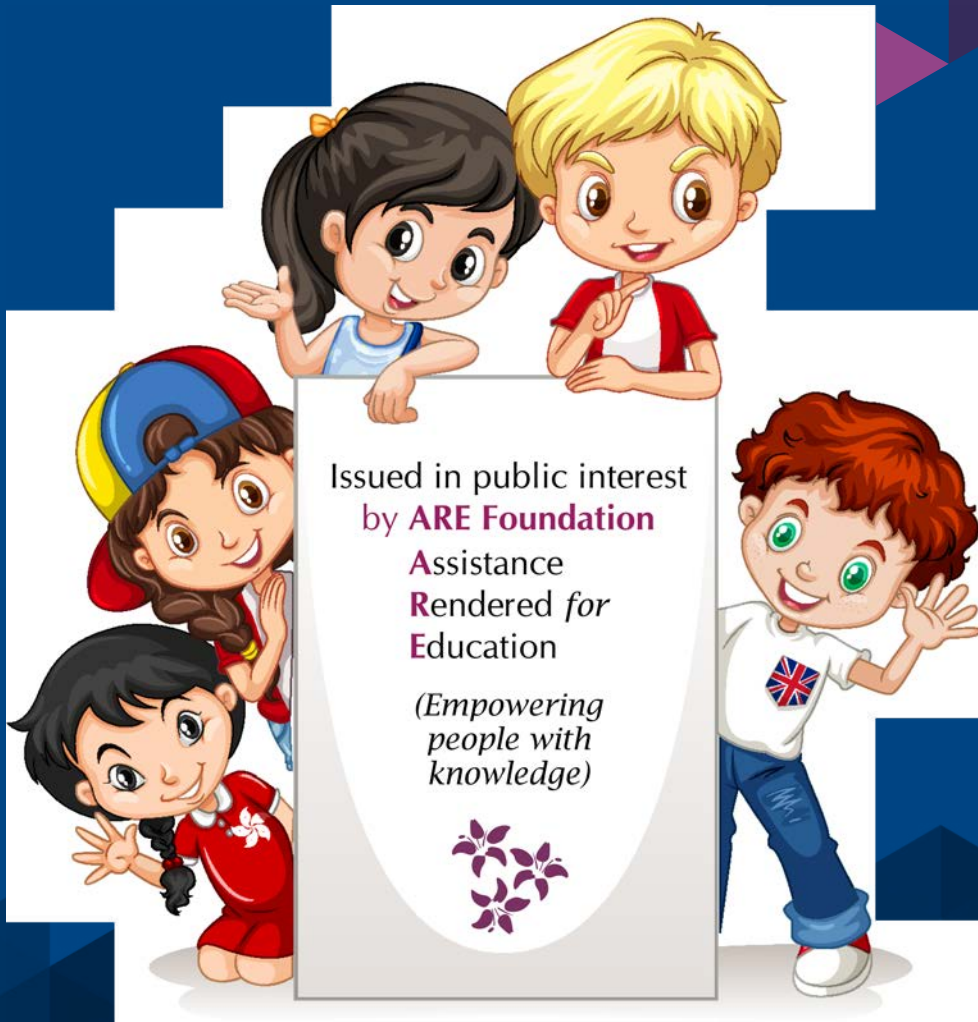Email : naren\_are@yahoo.com

Website : [www.drnarendrakumar.com](http://www.drnarendrakumar.com)

**Dr. Are Naredra Kumar**  
**Child Surgical Care**  
**Hyderabad, Telangana**

9848050565 / 6303413840 / 9293551036





Issued in public interest  
by **ARE Foundation**

**Assistance  
Rendered for  
Education**

*(Empowering  
people with  
knowledge)*

